

HIV enfekte hastada MSS radyolojisi

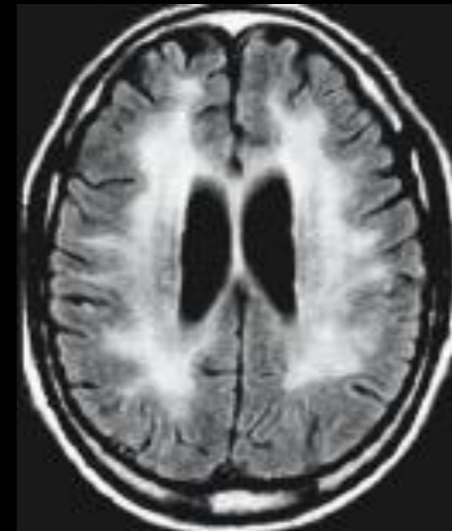
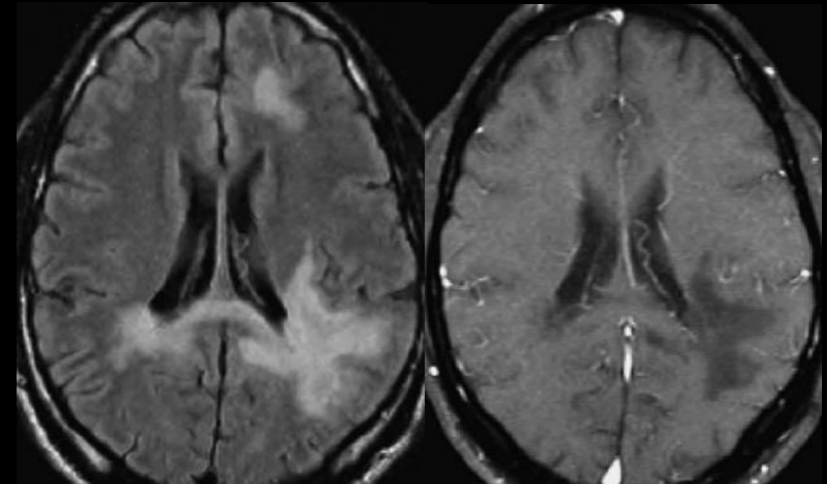
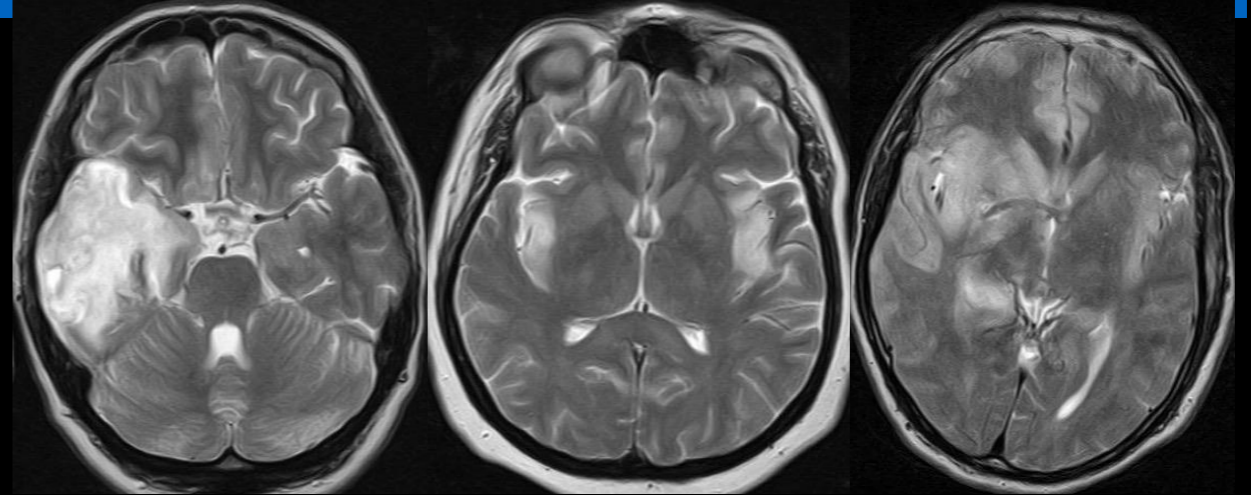
Dr. Osman KIZILKILIÇ
İstanbul Üniversitesi Cerrahpaşa Tıp Fakültesi
Radyoloji AD-Nöroradyoloji BD

HIV'E BAĞLI NÖROLOJİK TUTULUM

- %30 SIKLIKTA
- HIV ilişkili nörolojik Kx.lar
 - Doğrudan HIV ile ilişkili
 - Fırsatçı enf.lar
 - Ted ilişkili mtb bzk

Ensefalitler

- HSV
 - En sık fatal sporadik ensefalit nedeni.
 - İlk 48 saat içinde temporal ve inferior frontallerde hiperintensite
 - Geç dönem giral boyanma ve hemoraji
- PML
 - İmmün yetmezlikte (AIDS, transplantasyon)
 - Papova virüsü (JC virüsü)
 - Bilateral asimetric T2 hiperintens lezyonlar
 - Kontrast (-), kitle etkisi (-)
 - Korpus kallosumu geçince tümörü taklit edebilir
 - Boyutu artınca santralinde nekroz olabilir
- HIV ensefaliti
 - T2 görüntülerde hiperintens diffüz beyaz cevher değişiklikleri ve generalize atrofi

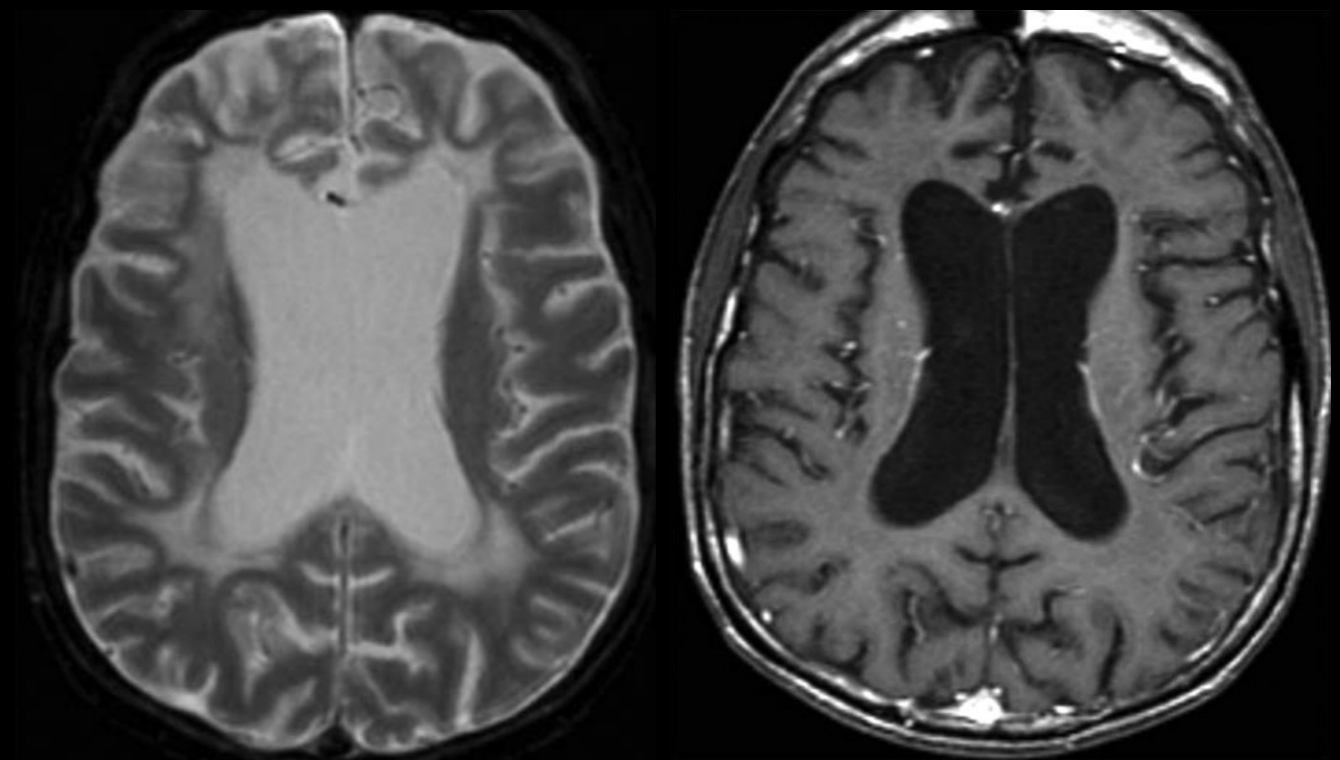
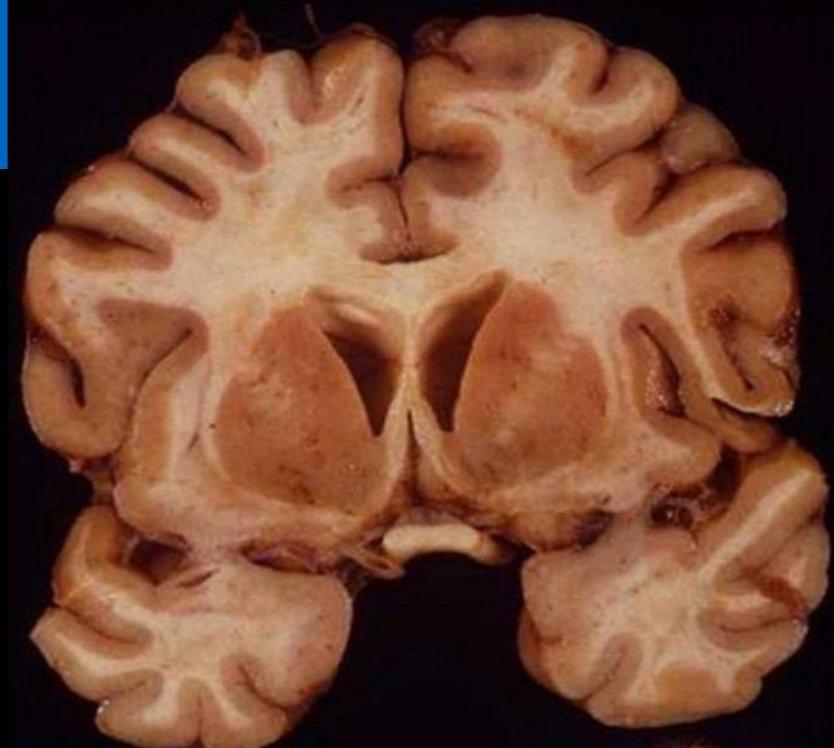


HIV ensefaliti

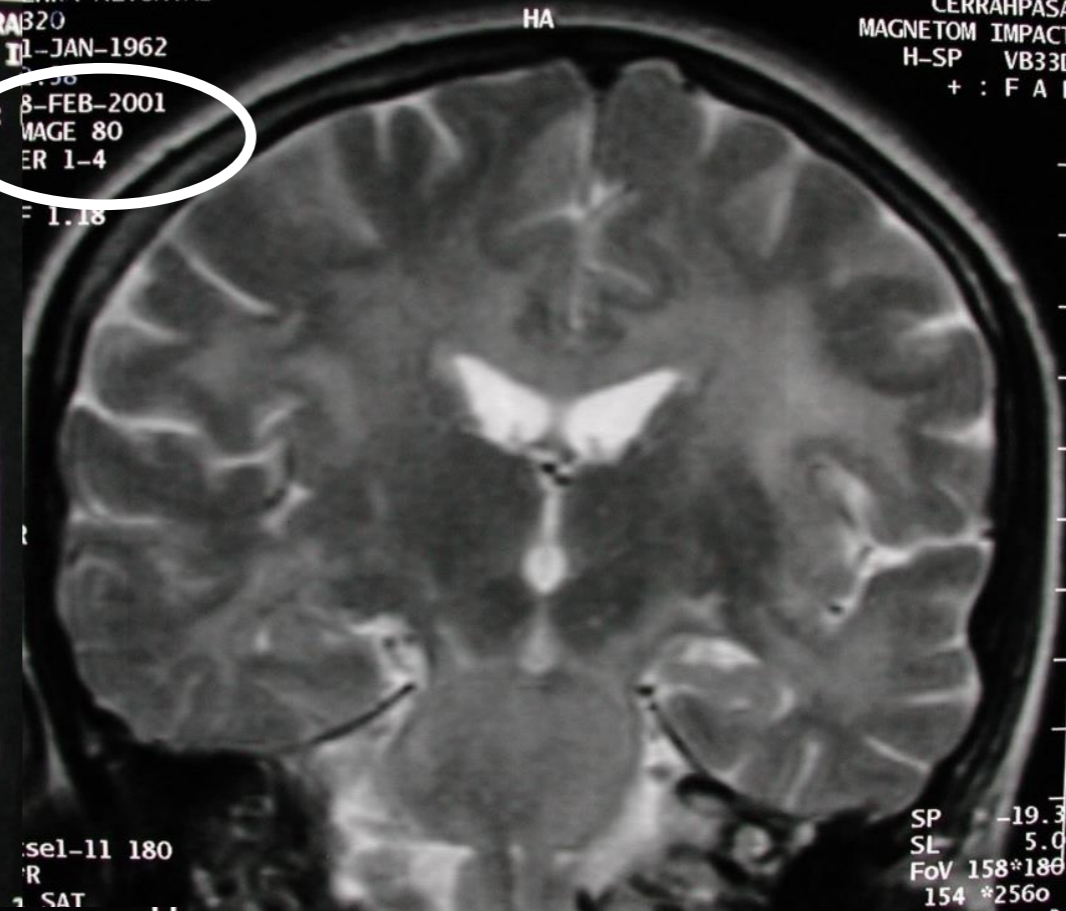
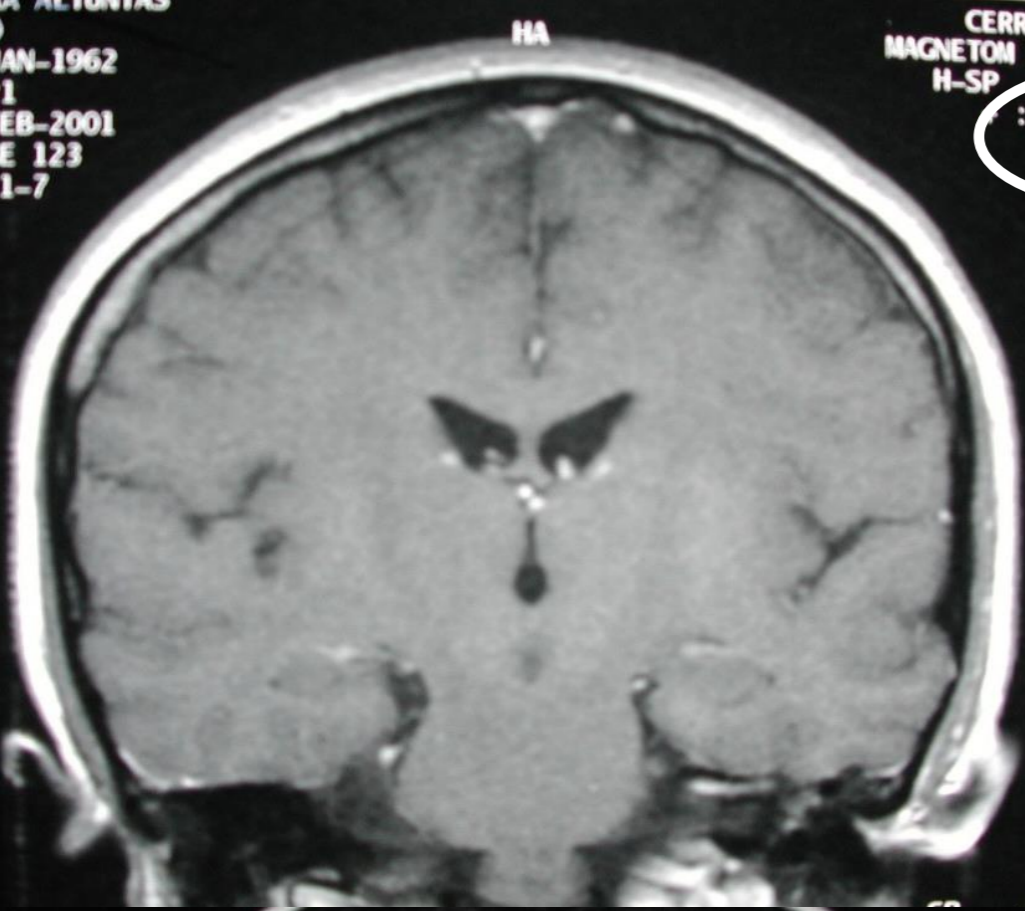
- Otopside HIV/AIDS hastalarının %75-90'nda beyin tutulumu bulguları (+)
- Ensefalit %5-10 olguda ilk bulgu
- Olguların %25'nde uygun tedaviye ve cevaba rağmen orta düzeyde kognitif yıkım gelişir
- HIVE veya lökoensefalopati beynin HIV enfeksiyonunun doğrudan sonuçlarıdır

HIV ensefalit

- **Radyoloji**
 - Direk etkisi (ensefalit)
 - Demansiyel tablo
 - Fırsatçı enfeksiyon
 - CMV
 - Fungal
 - PML
 - Tb
 - Nörosfiliz
 - Neoplazma
 - İlaça bağlı komplik.

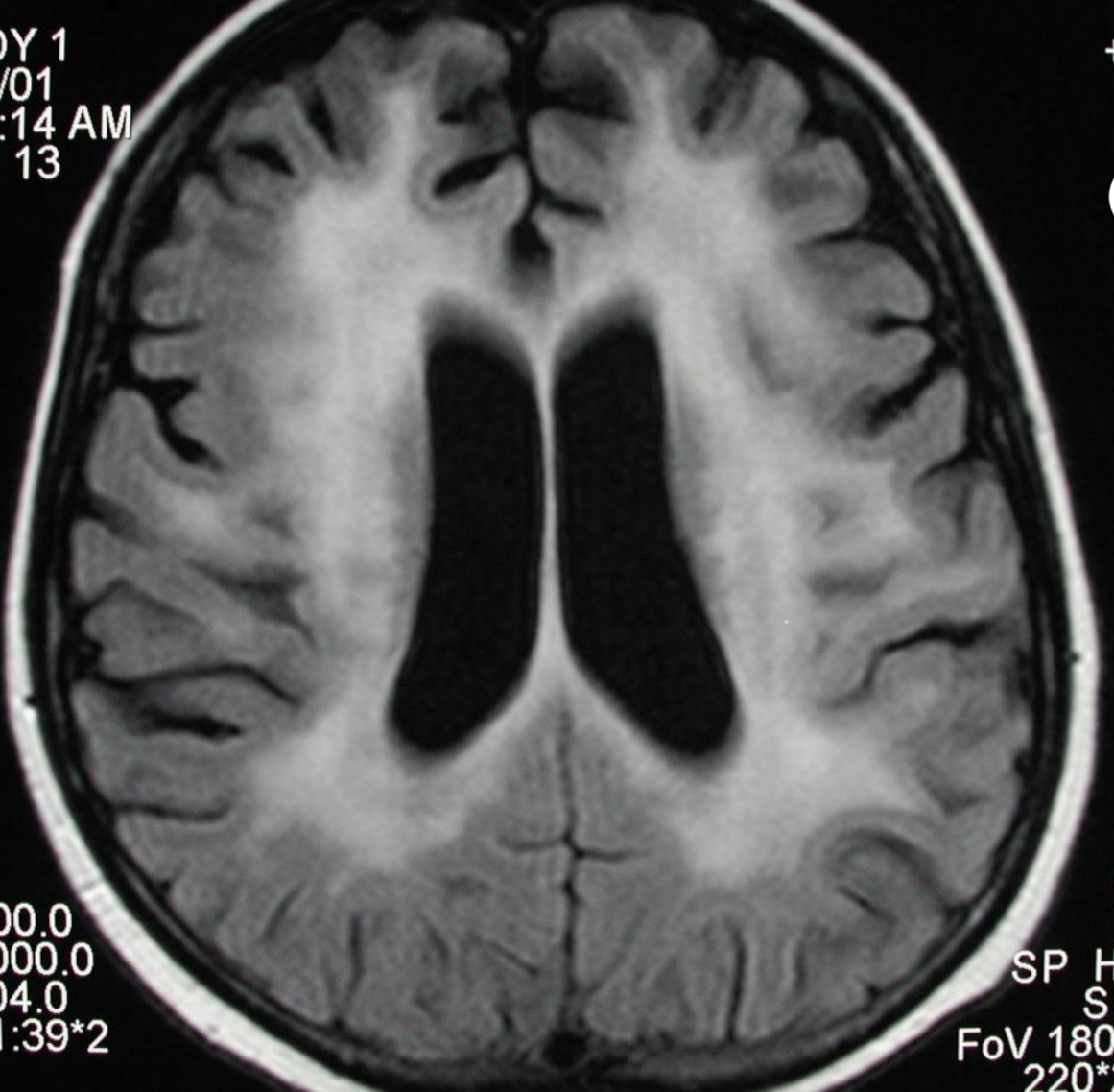


Diffüz atrofi, simetrik beyaz cevher
T2 anormalliği, kontrast (-)

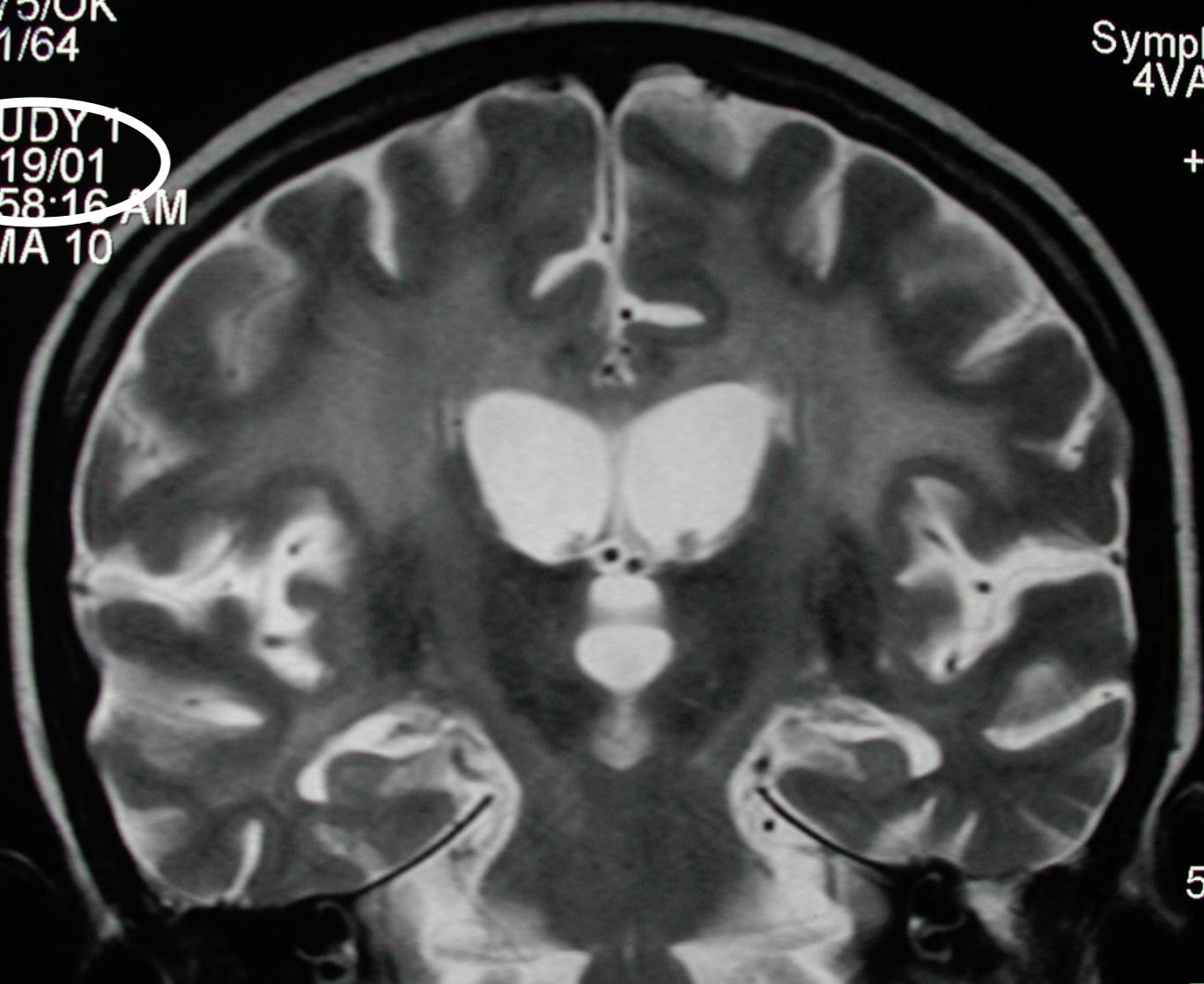


HIV+

9. AY kontrol.

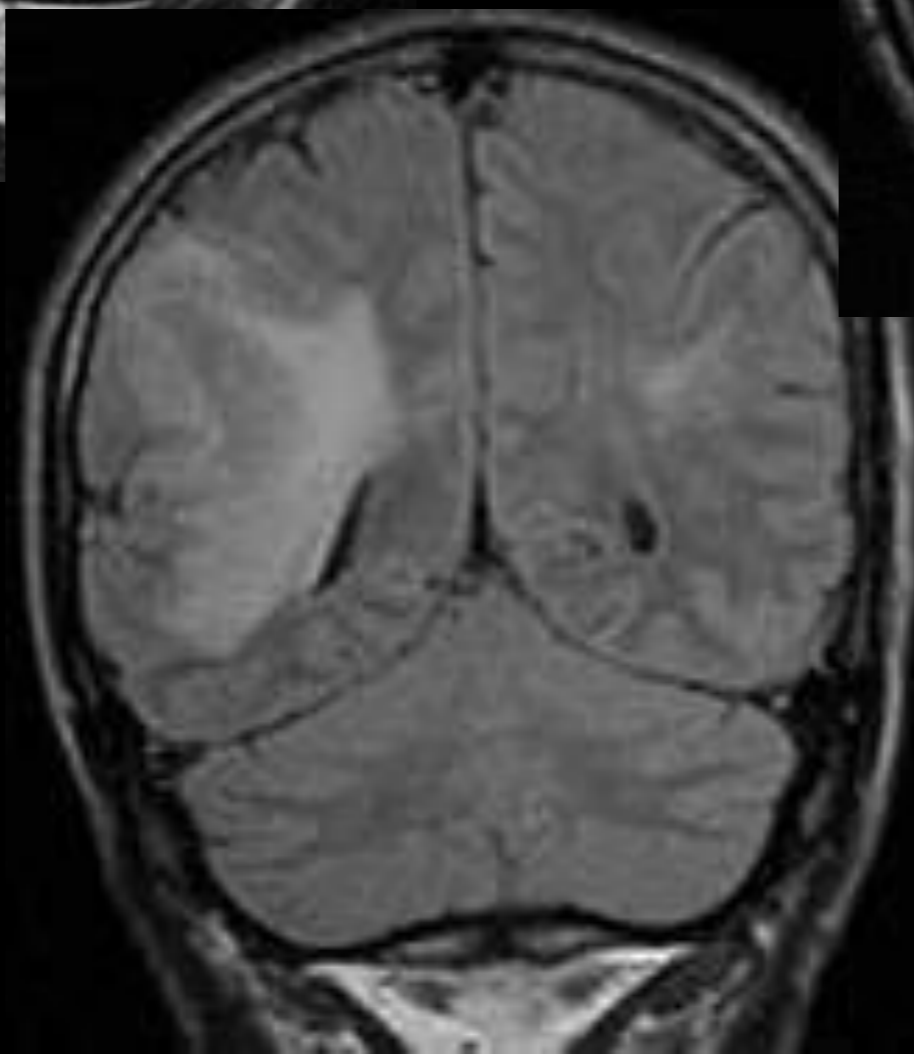
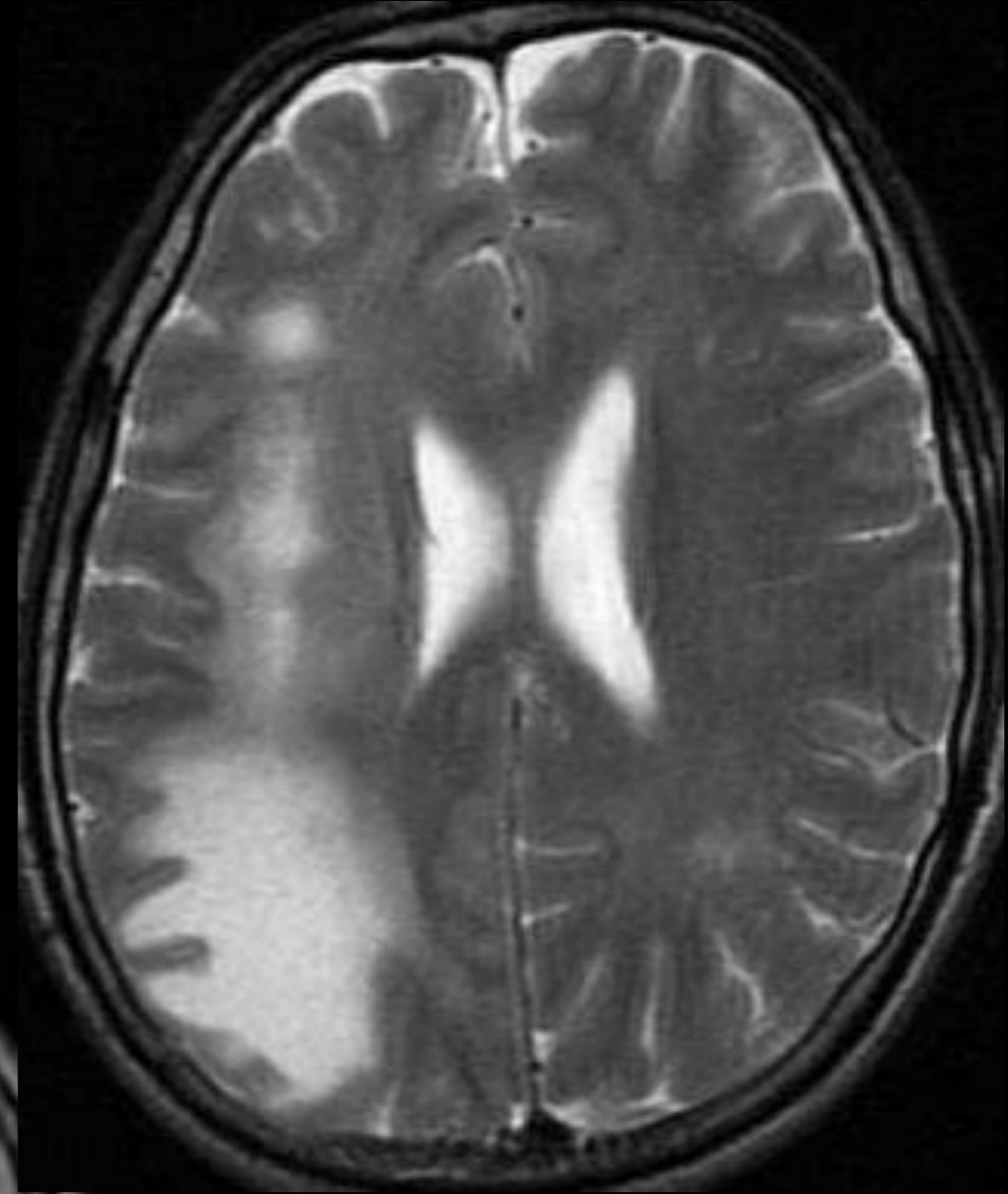
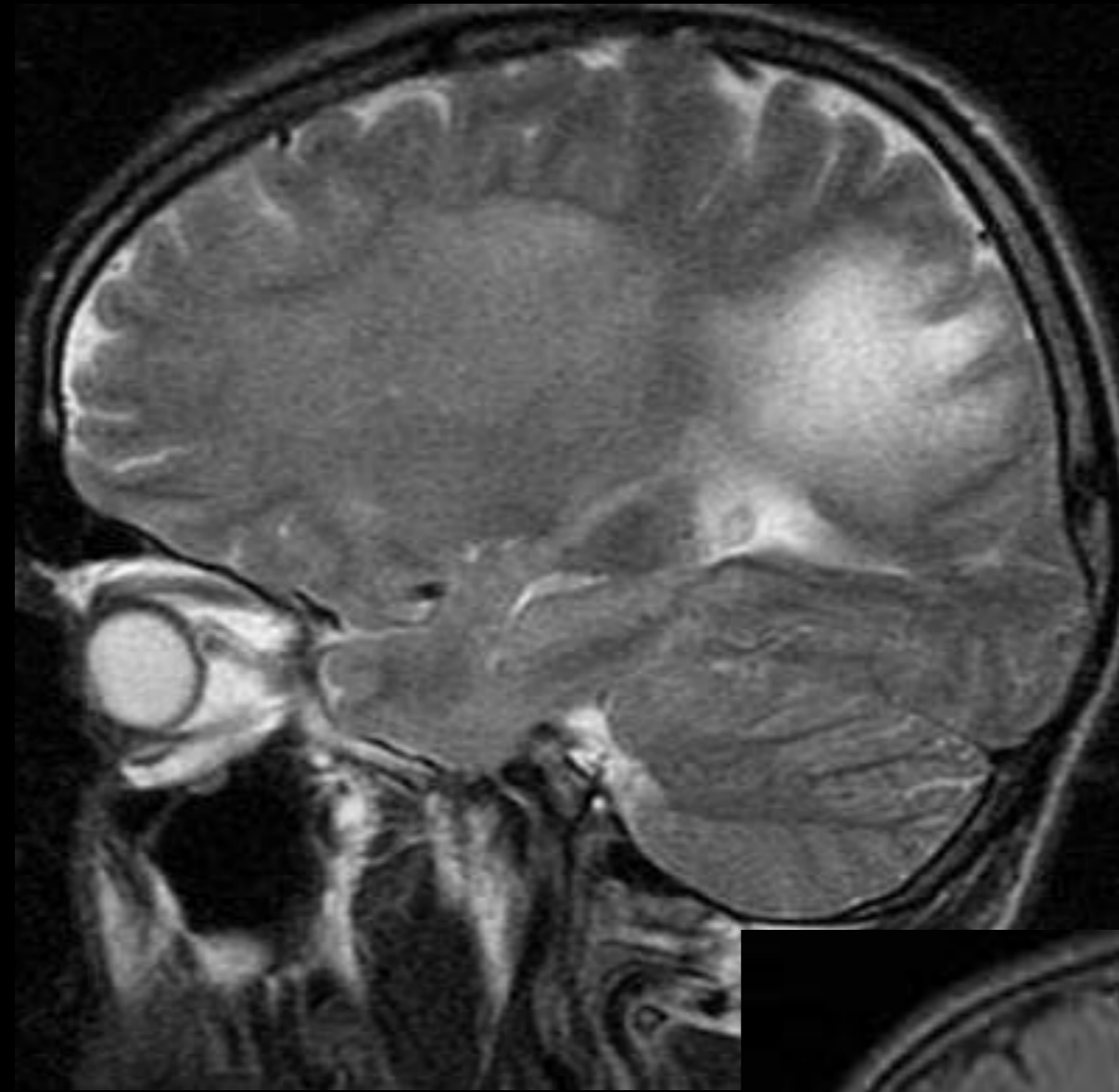


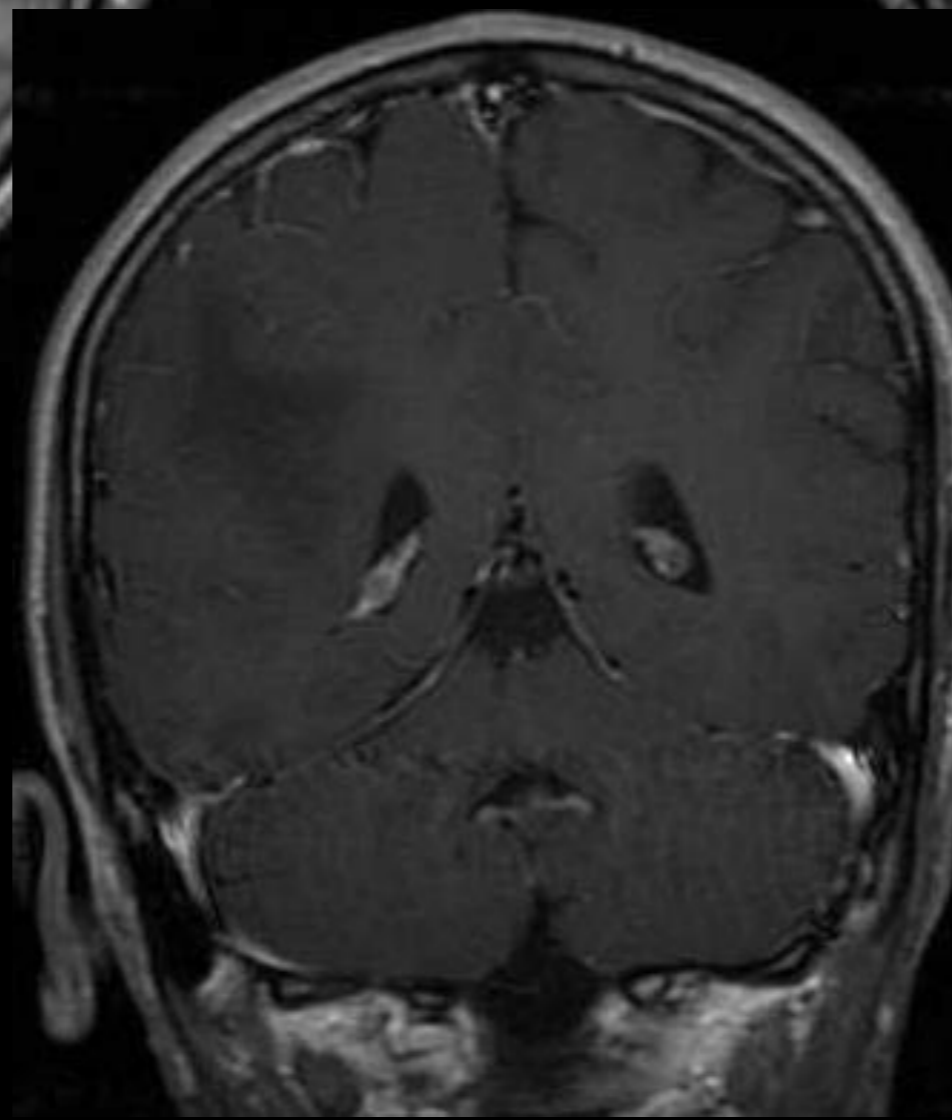
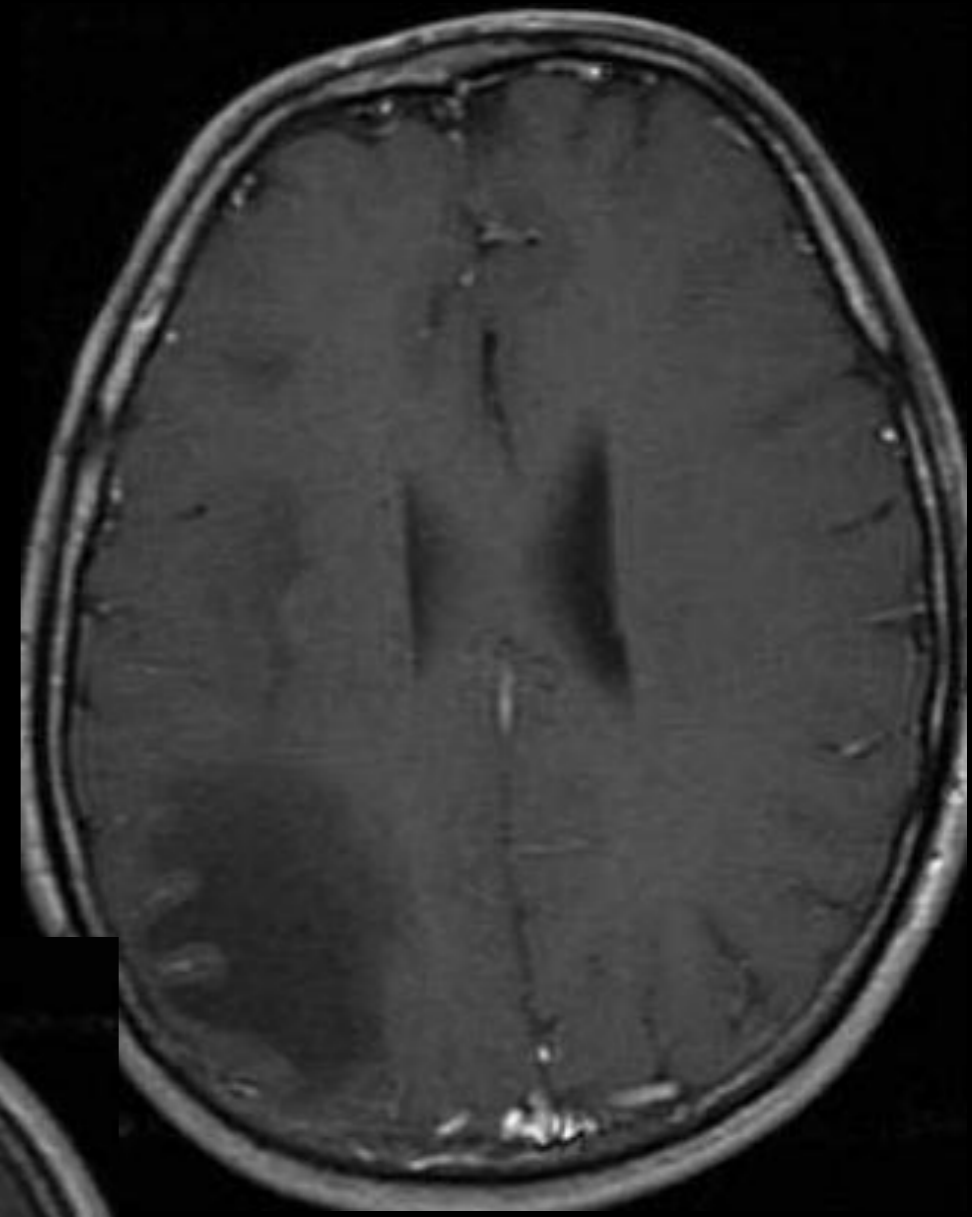
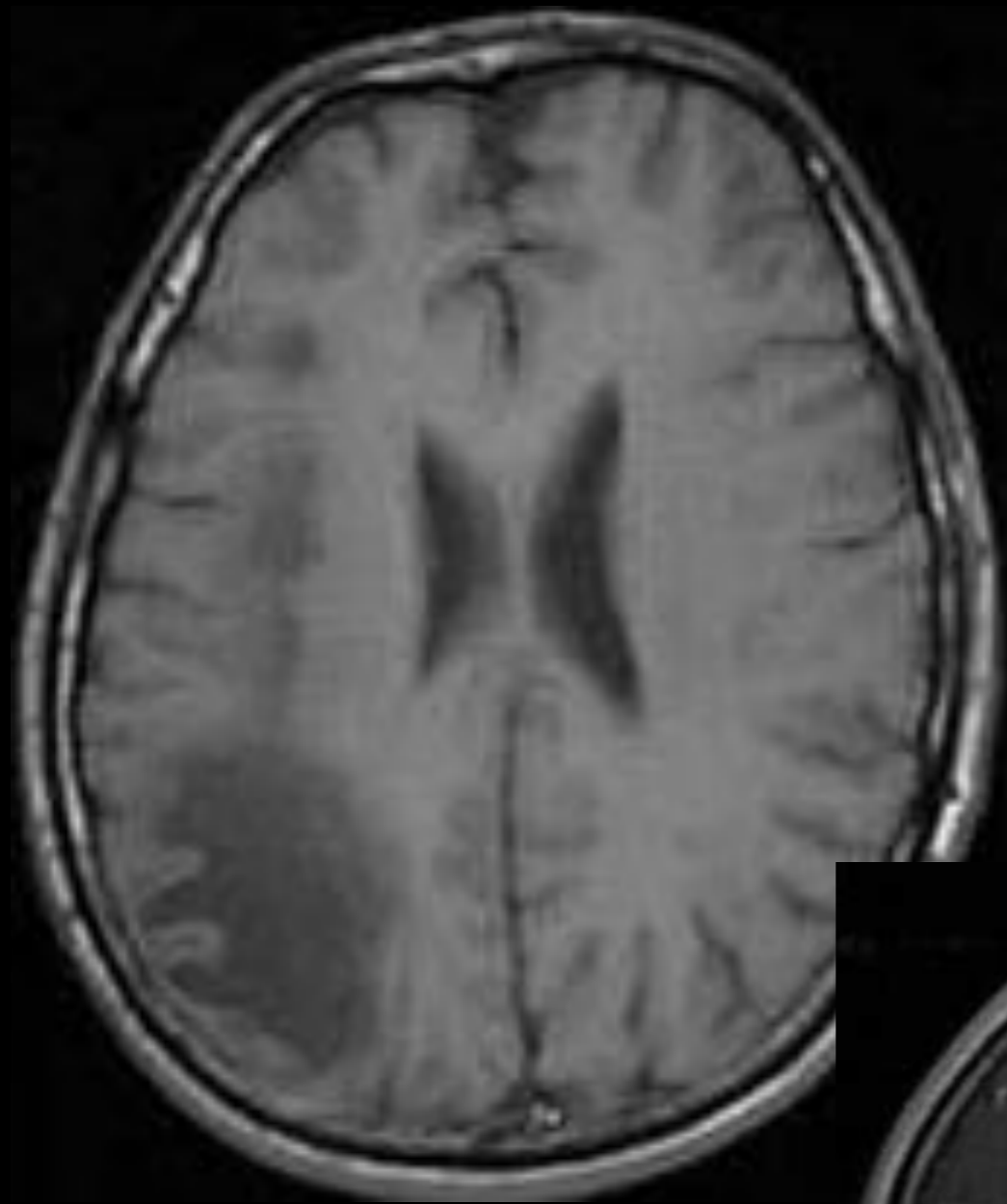
H1375/OK
+L*1/1/64
STUDY 1
11/19/01
11:58:16 AM
5 IMA 10

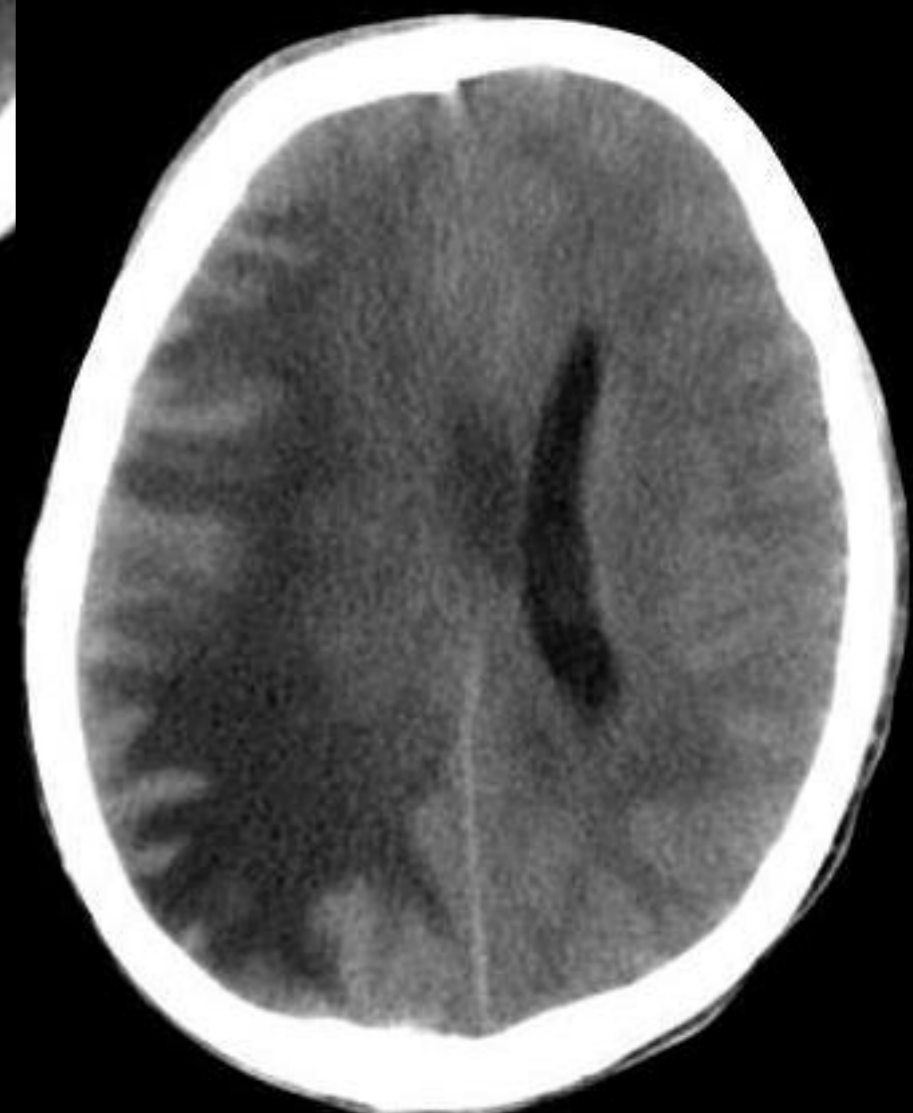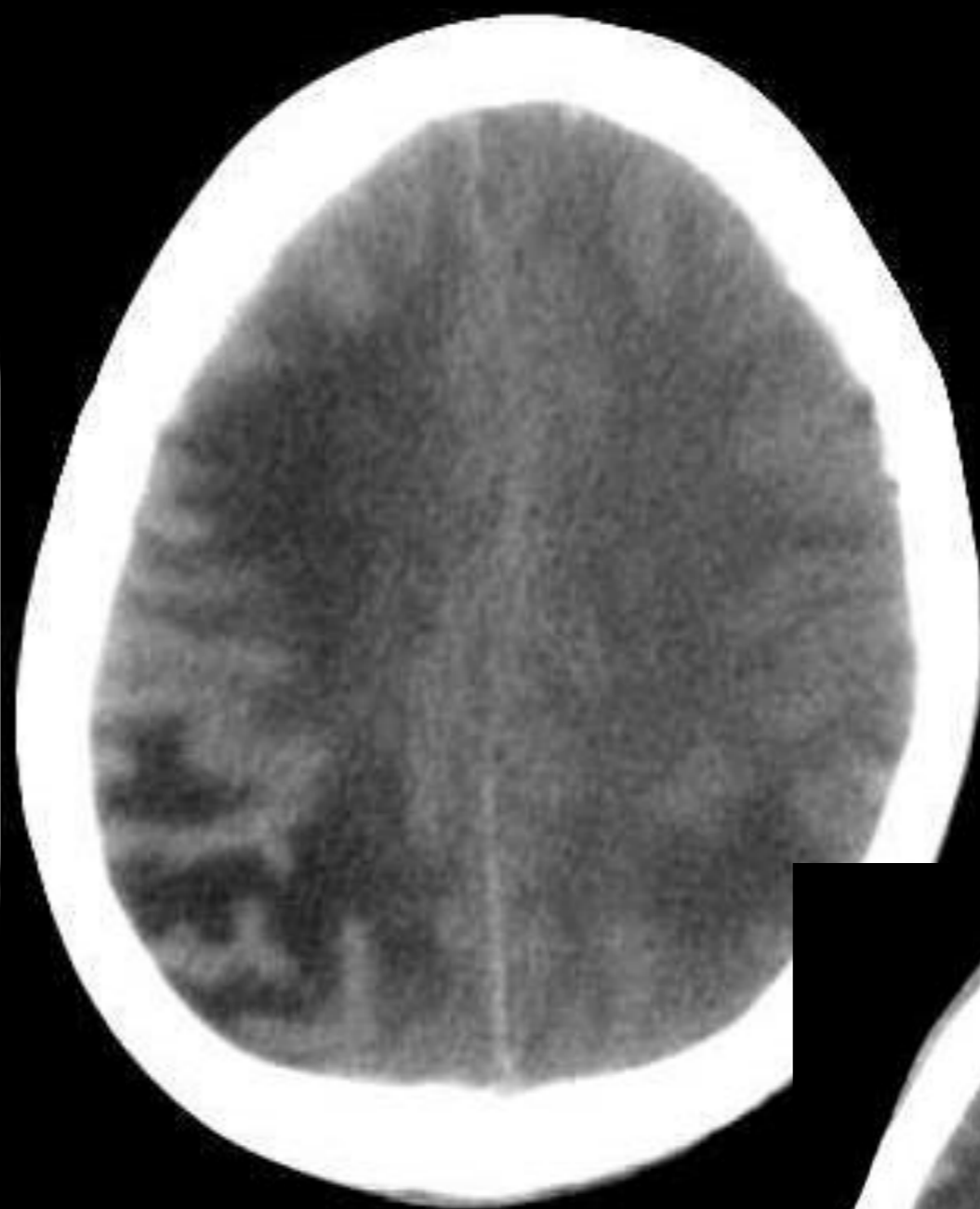

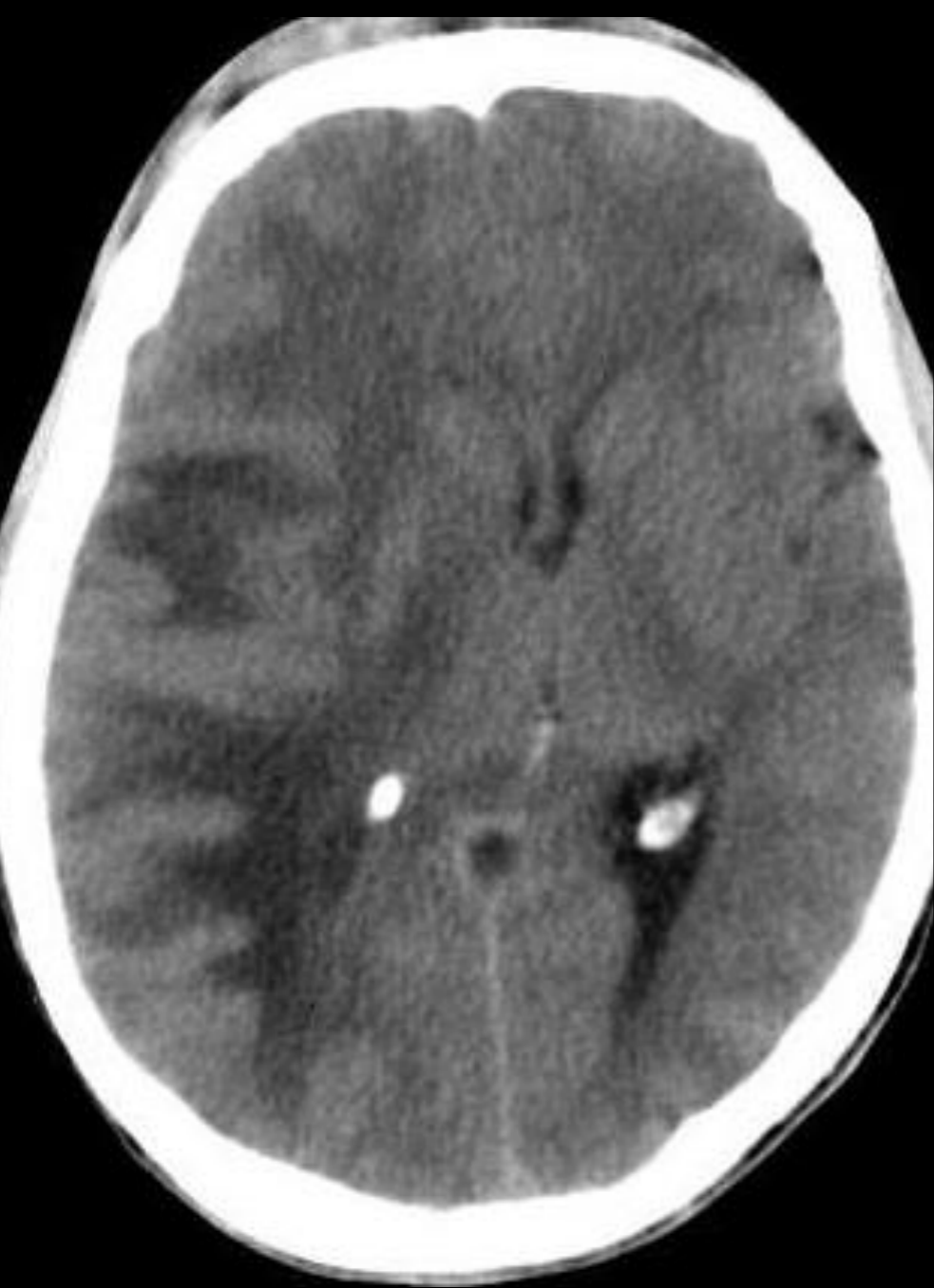
HIVE Görüntüleme

- BT - Normal, atrofi, ak madde hipodansitesi
- MR
 - Hacim kaybı, sulkuslarda-ventrikülde genişleme
 - T2/FLAIR silik sinyal artışı
 - Kitle etkisi yok
 - Kontrastlanma yok - istisna akut fulminan HIVE

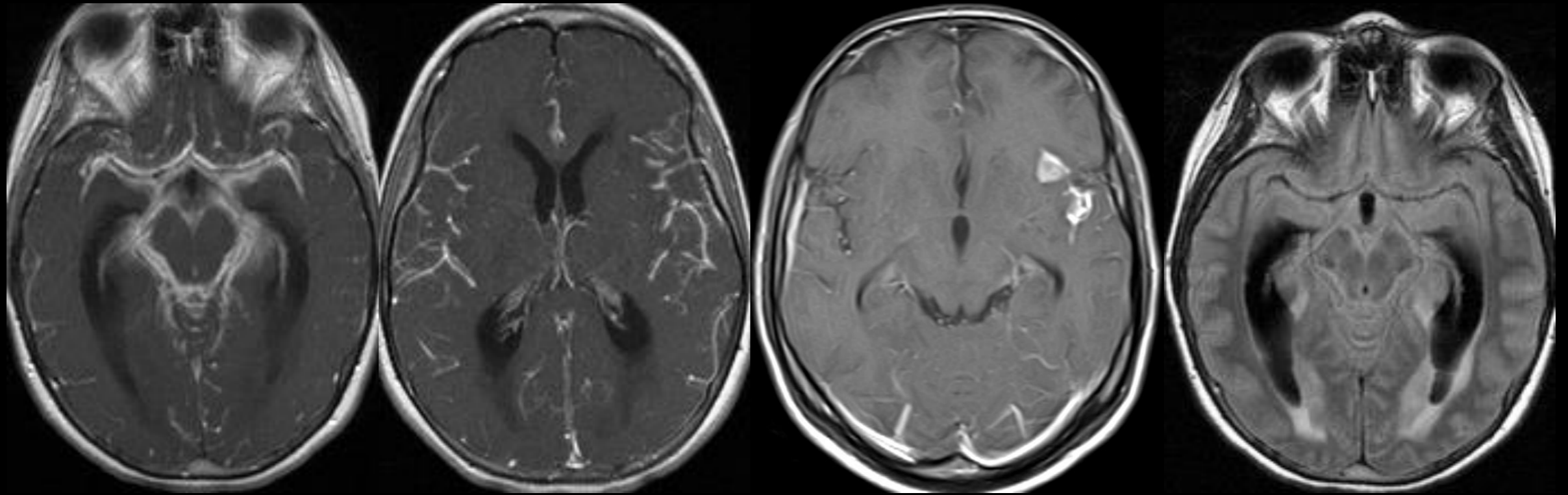






Takip BT

Tb menenjit

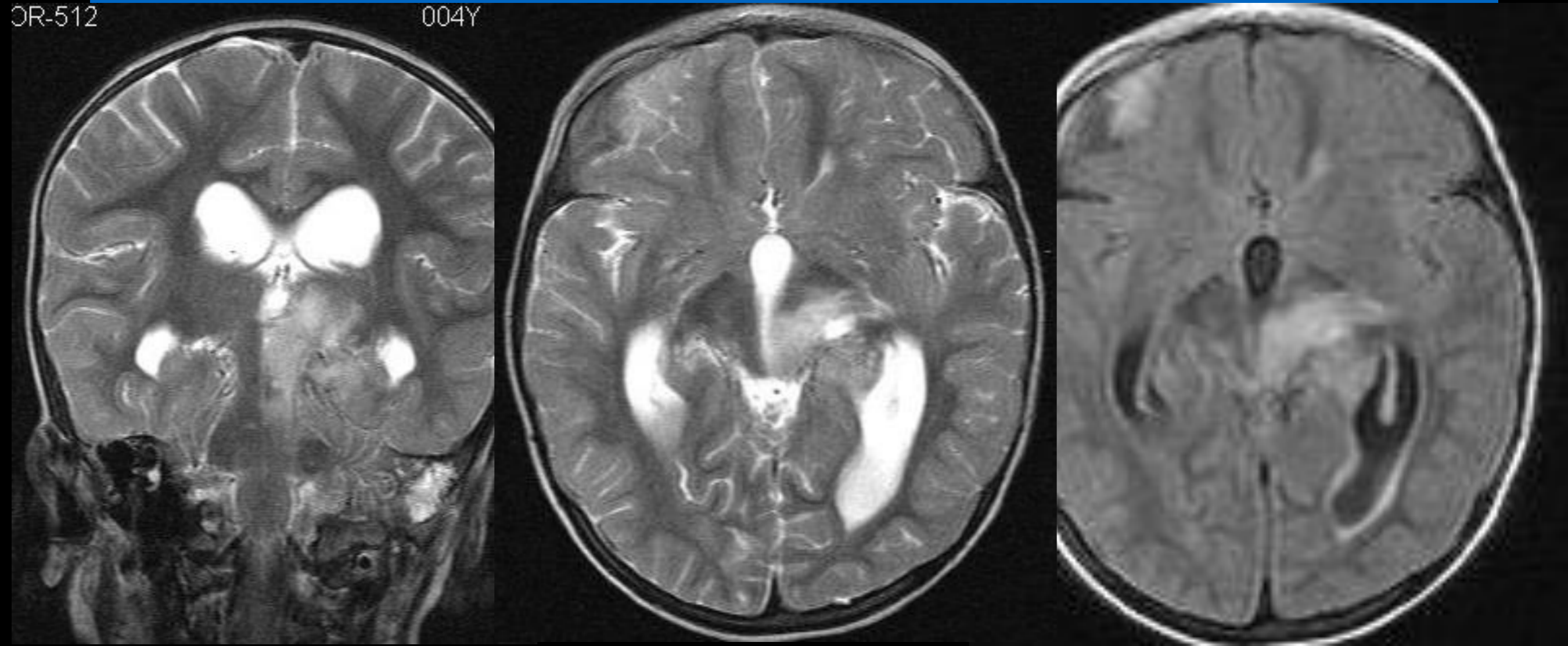


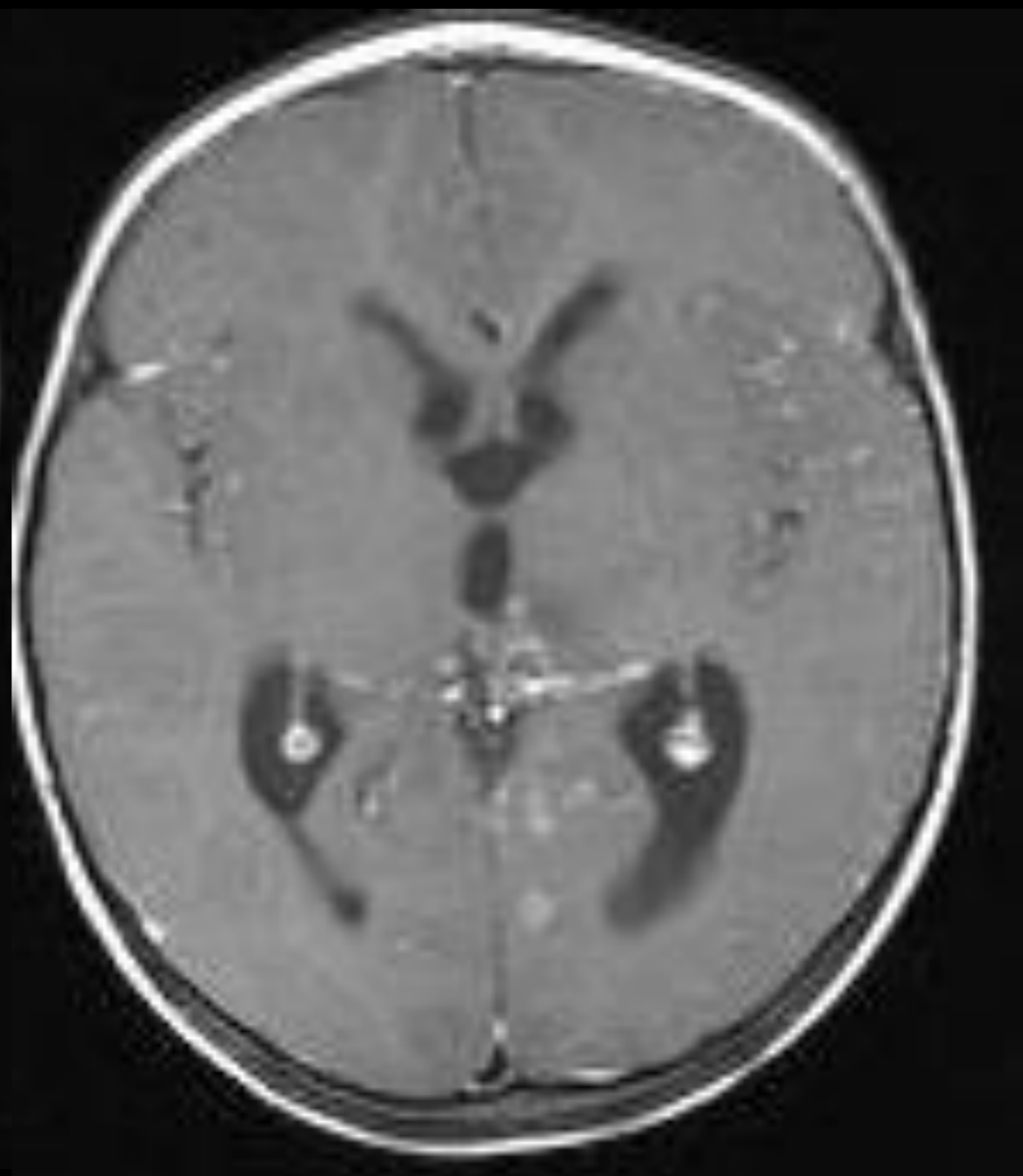
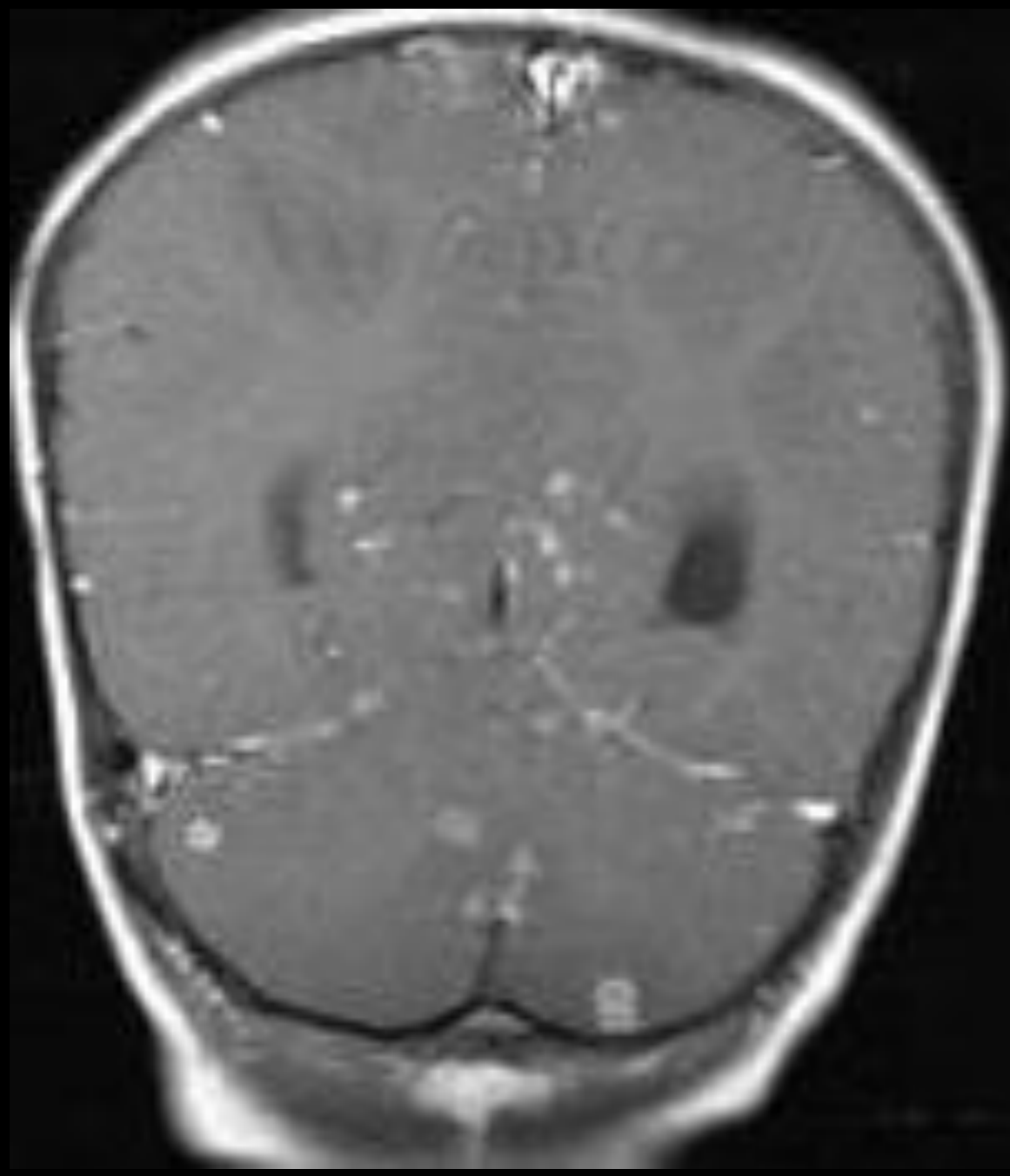
Meningeal boyanma	%45
Hidrocefali	%51

Tb menenjit – bazal menenjit

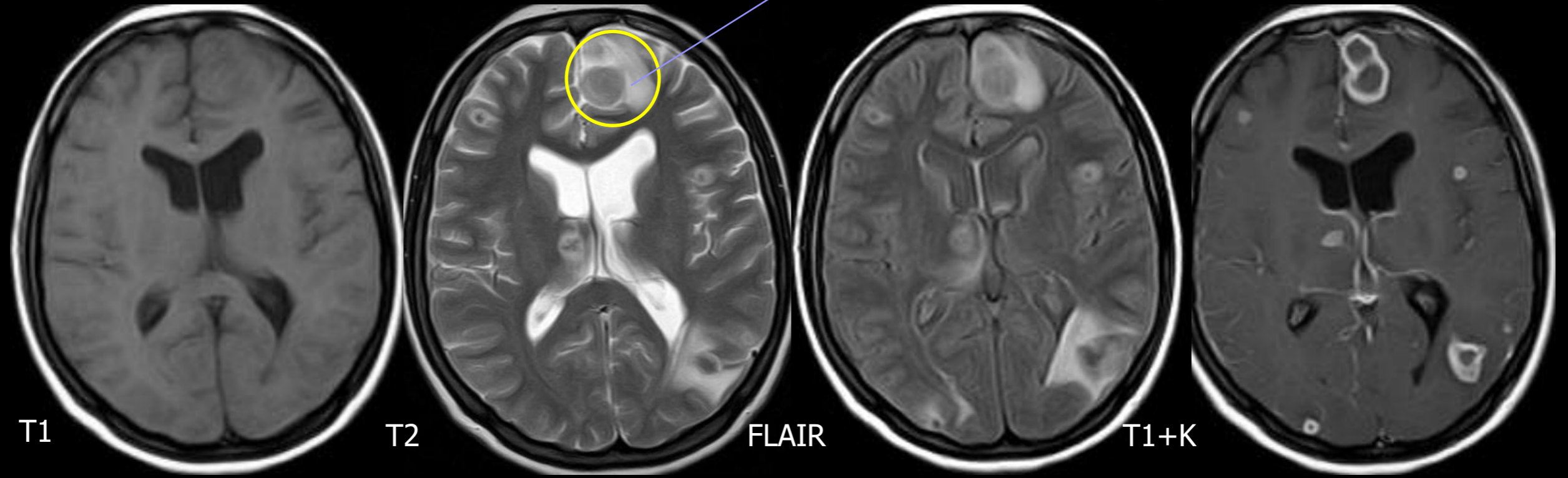
OR-512

004Y



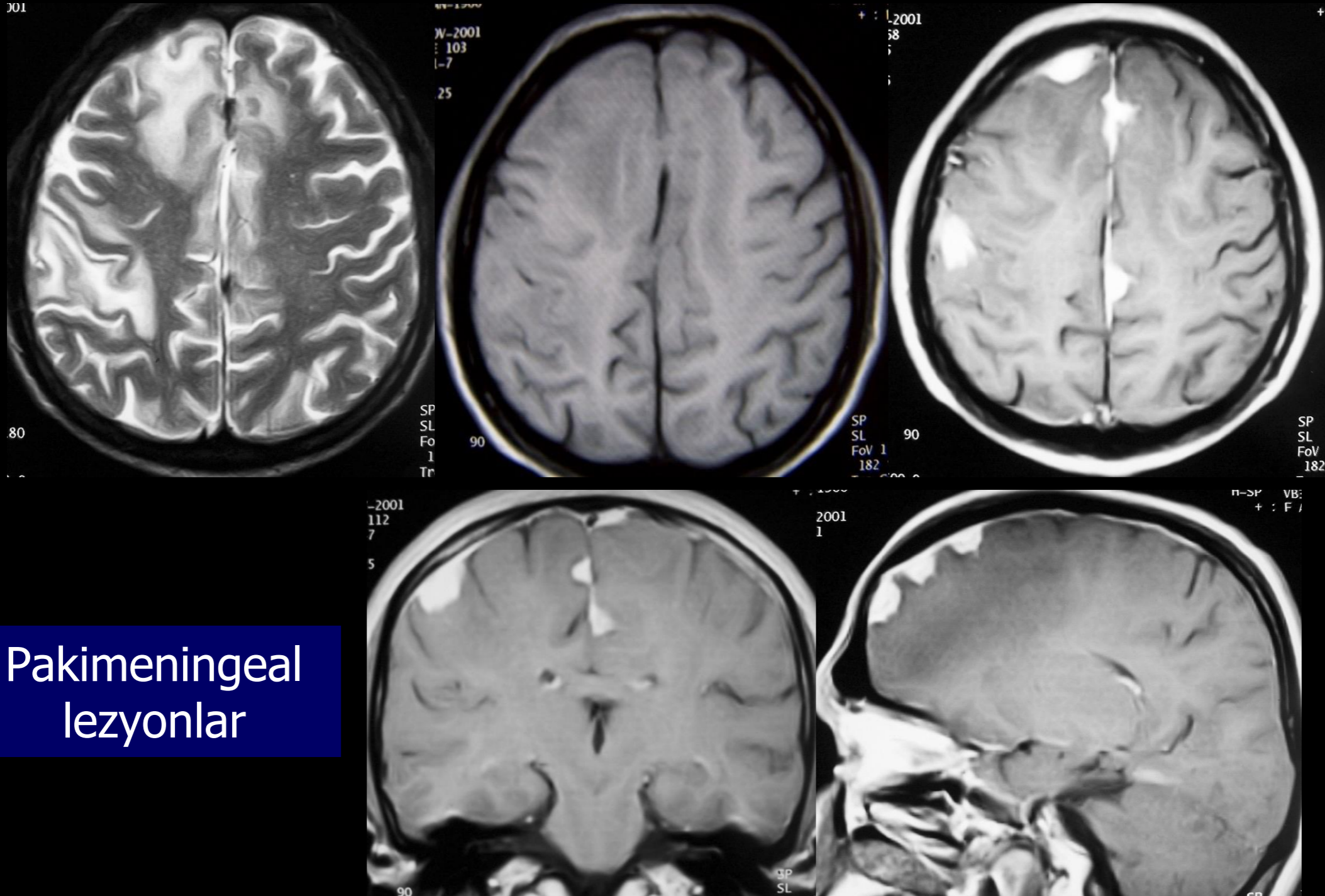


T2 hipointensite



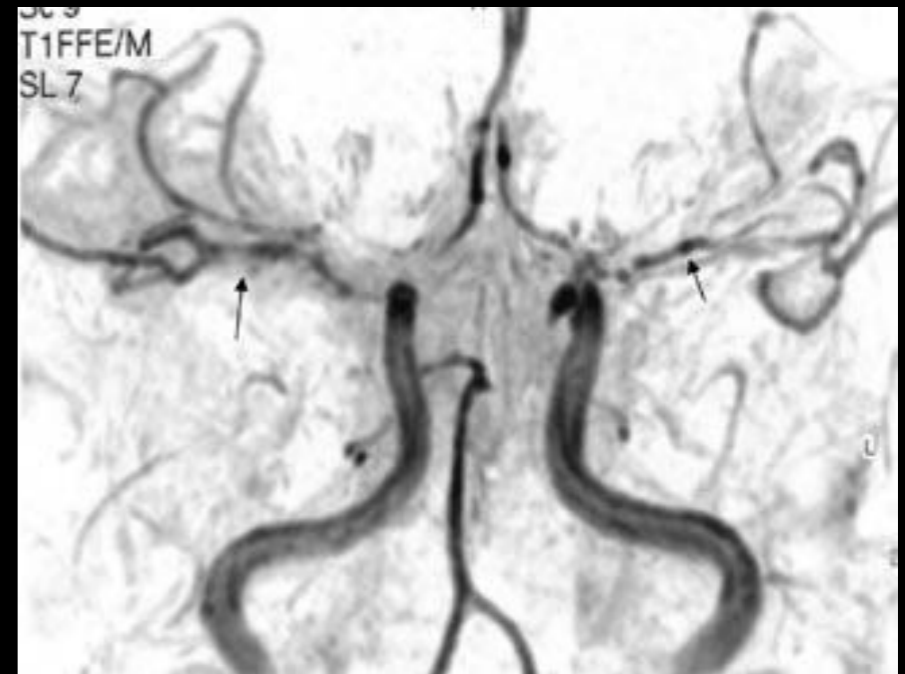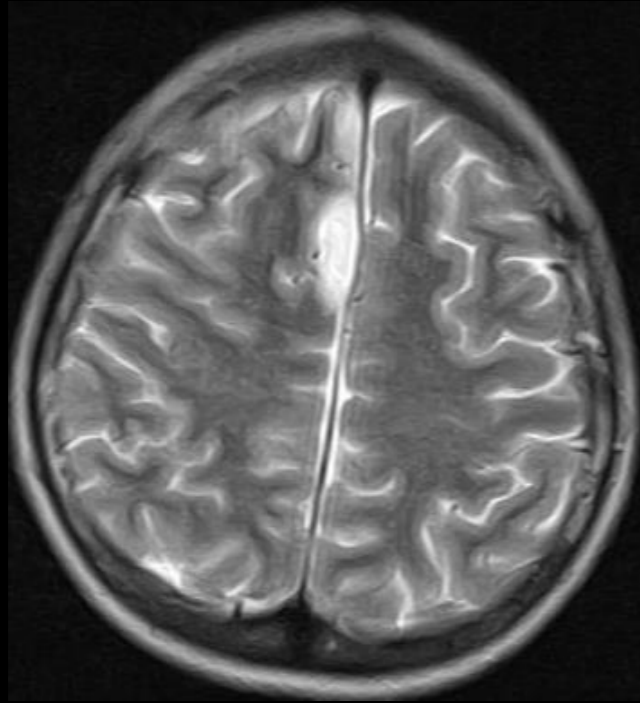
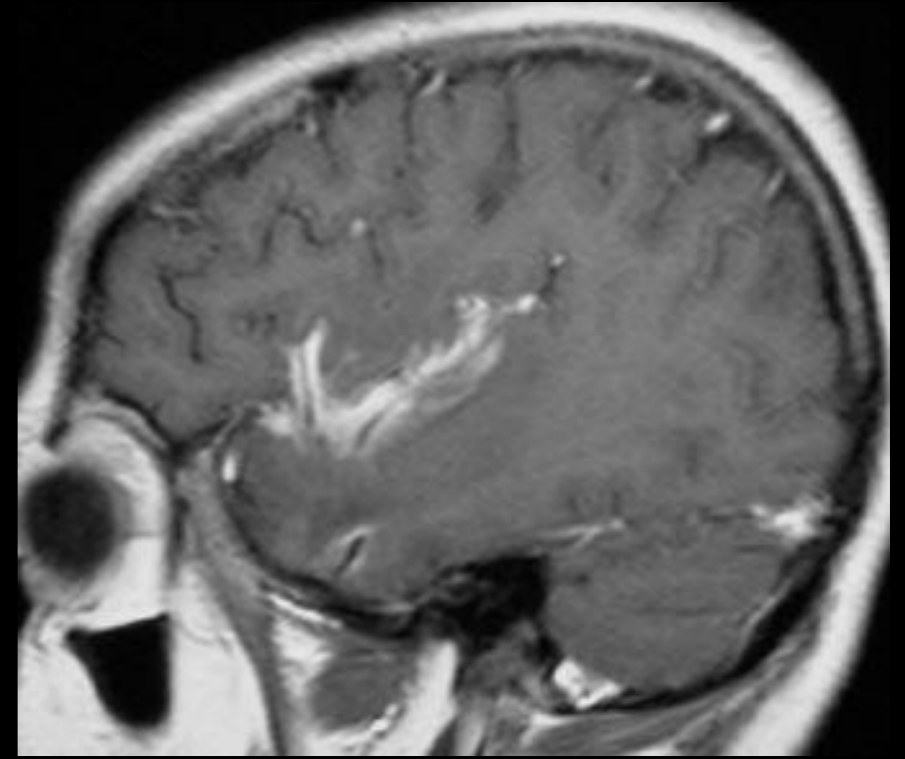
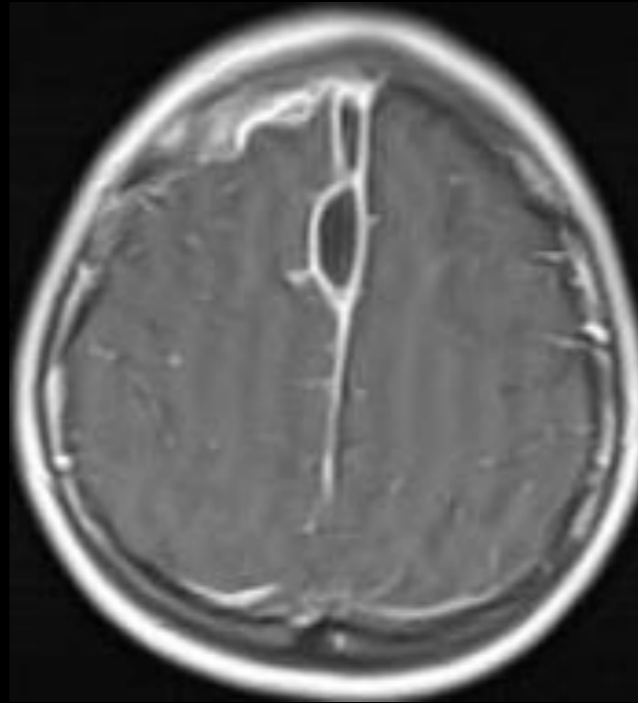
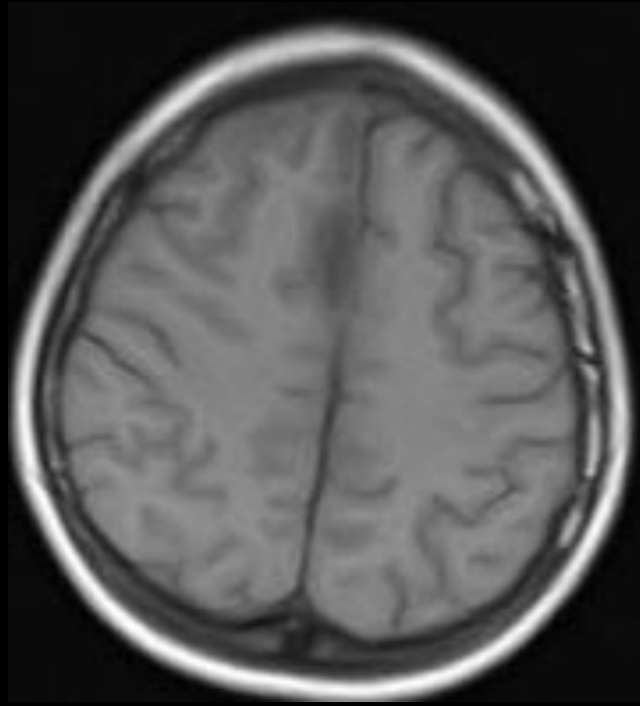
1. Tüberküloom %24
2. Her yerde olabilir (parankim, epidural, subdural)
3. Erken dönemde T2 hipointensite (kazeoz nekroz),

Tb – atipik görünüm



Pakimeningeal
lezyonlar

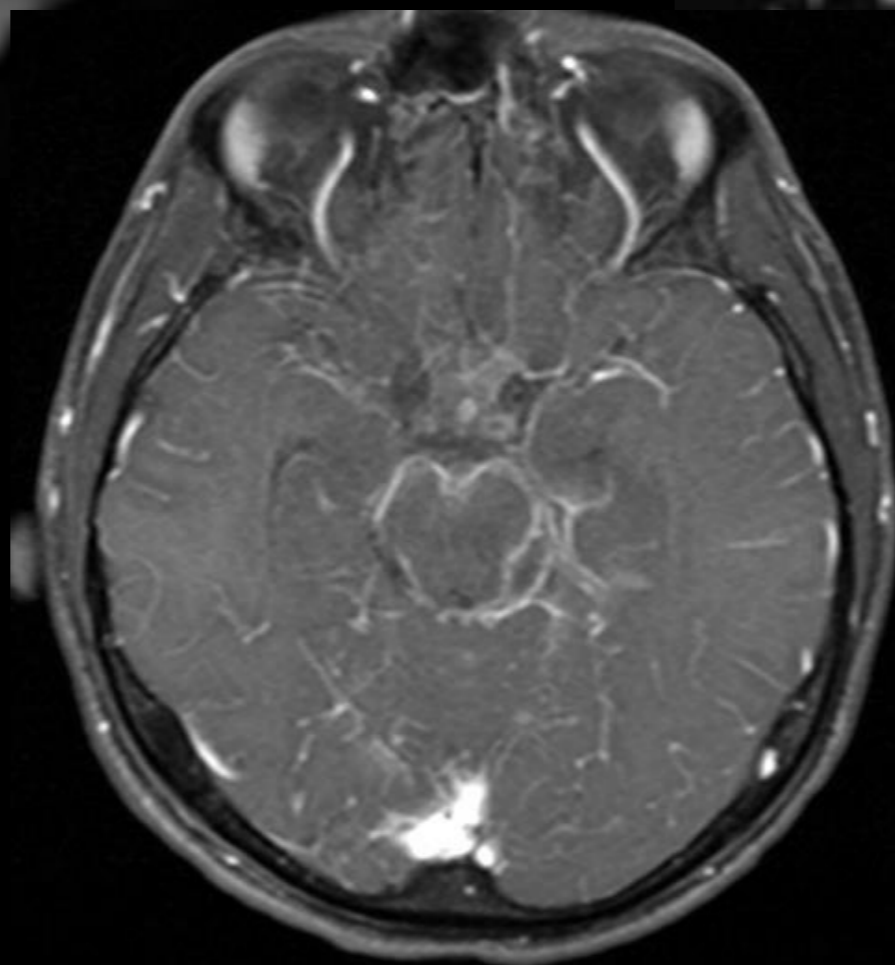
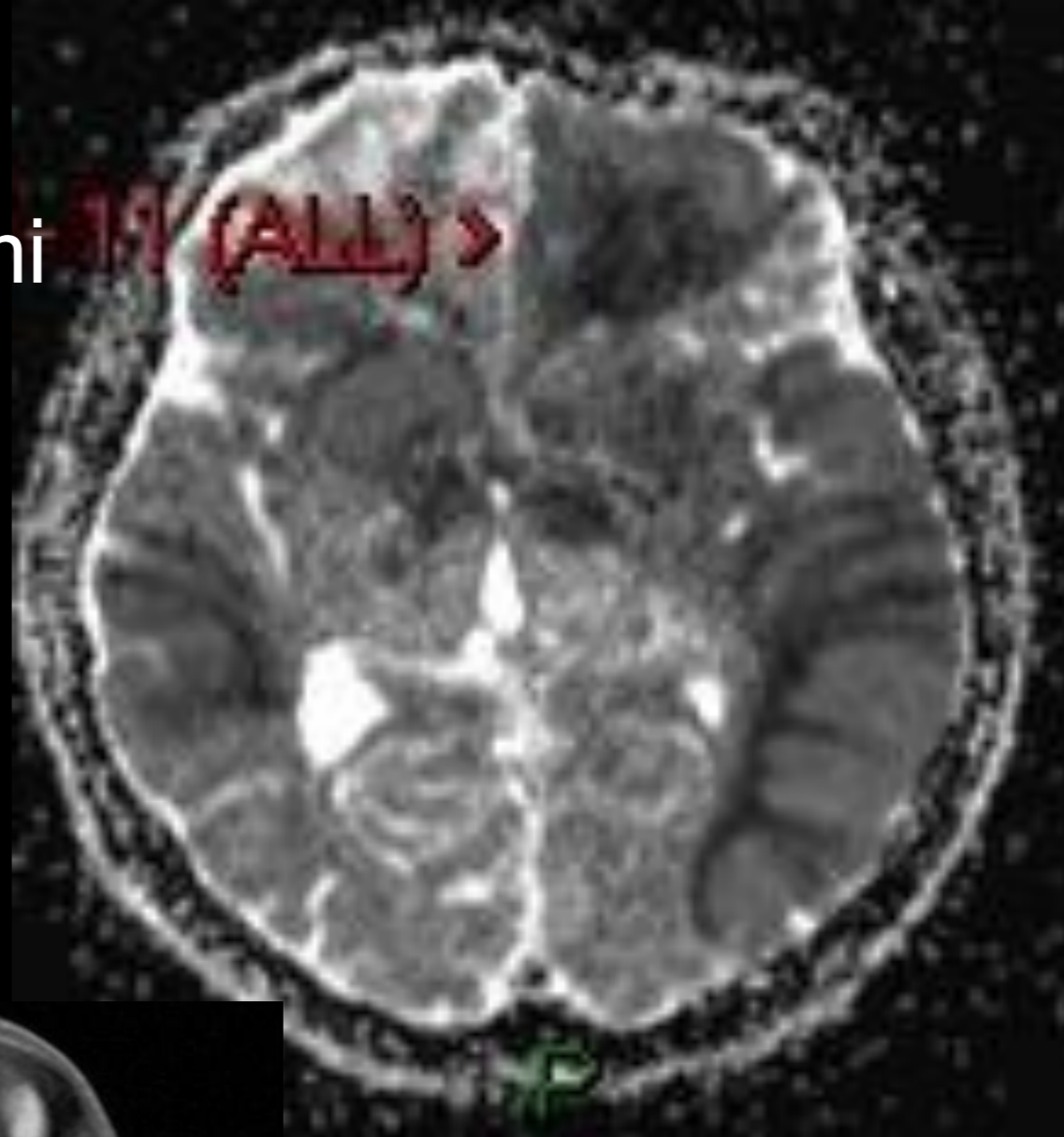
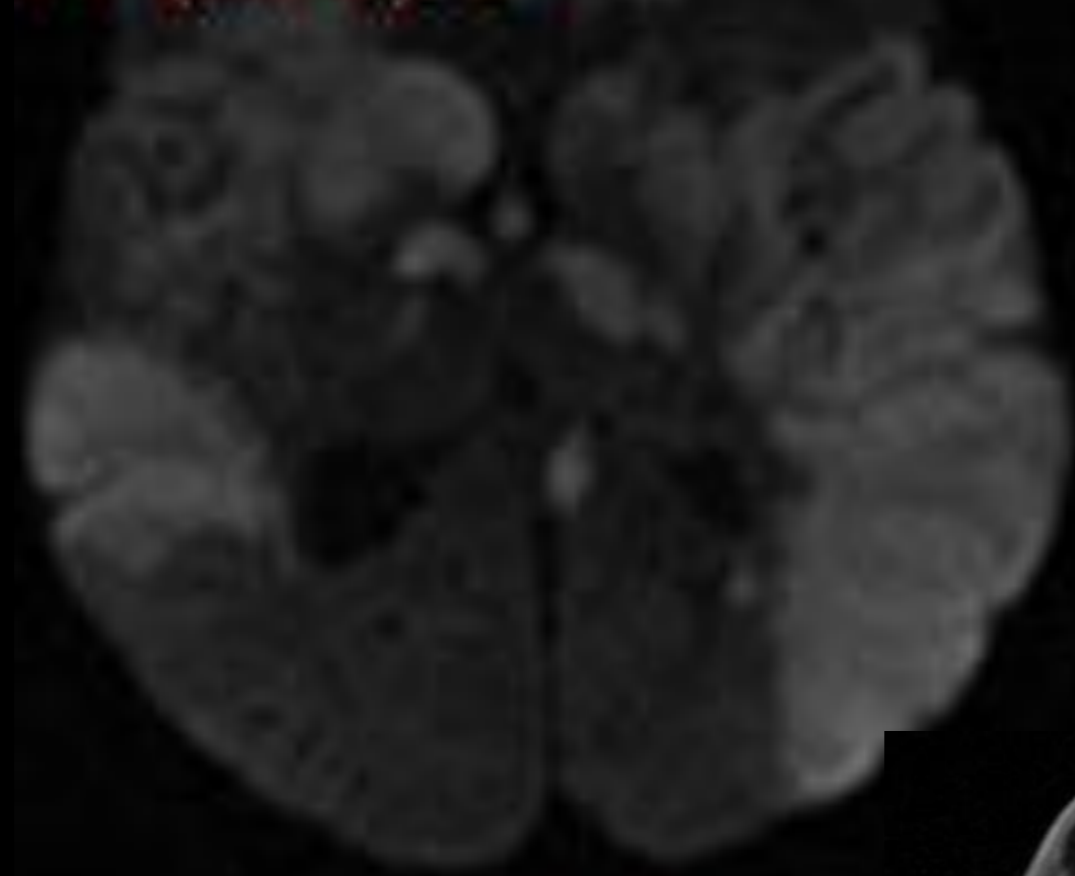
Tb komplikasyonlar



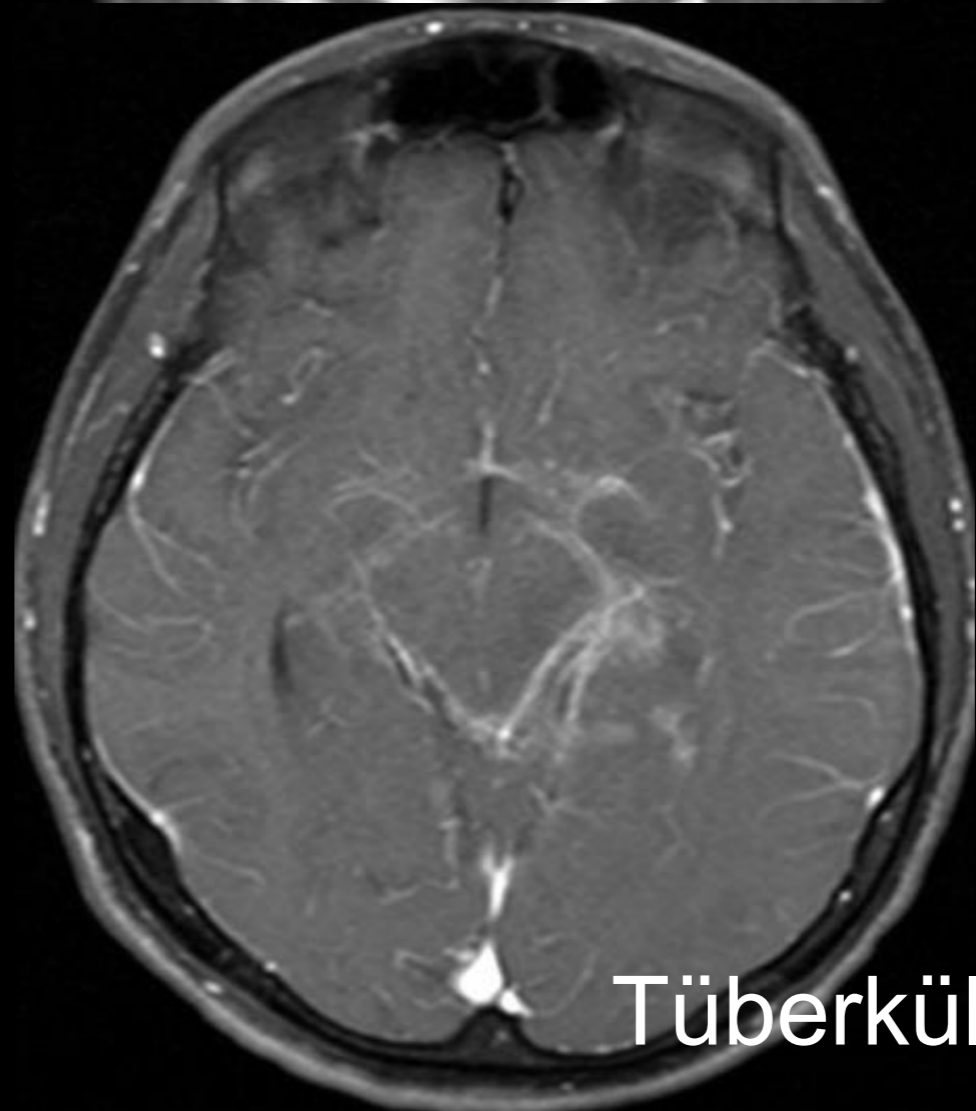
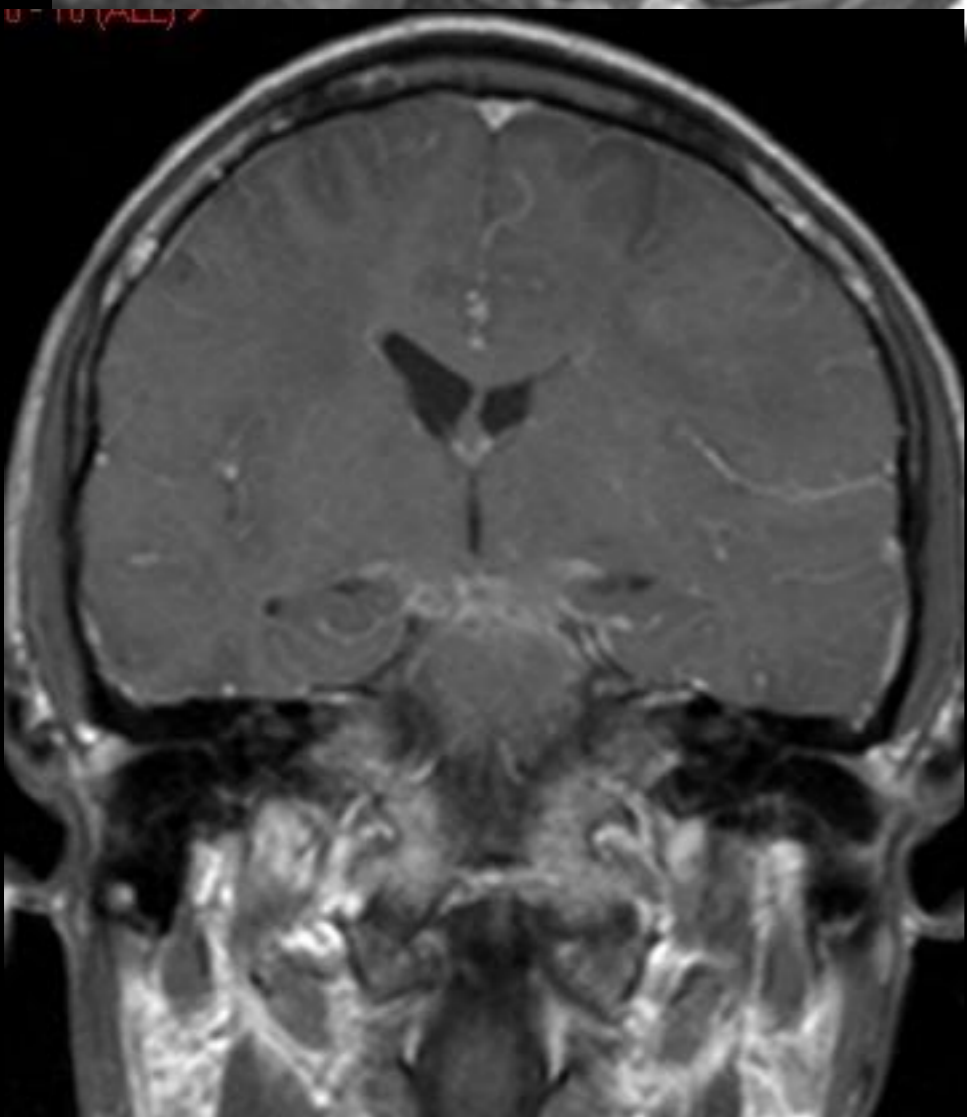
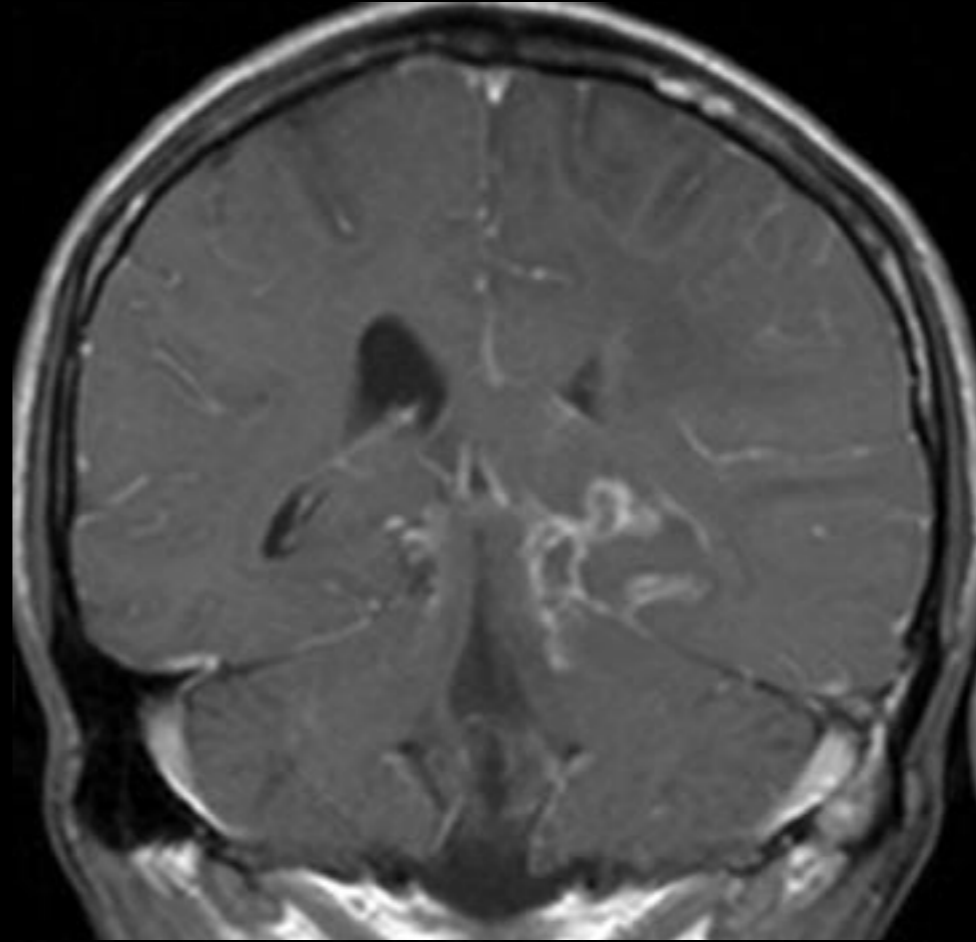
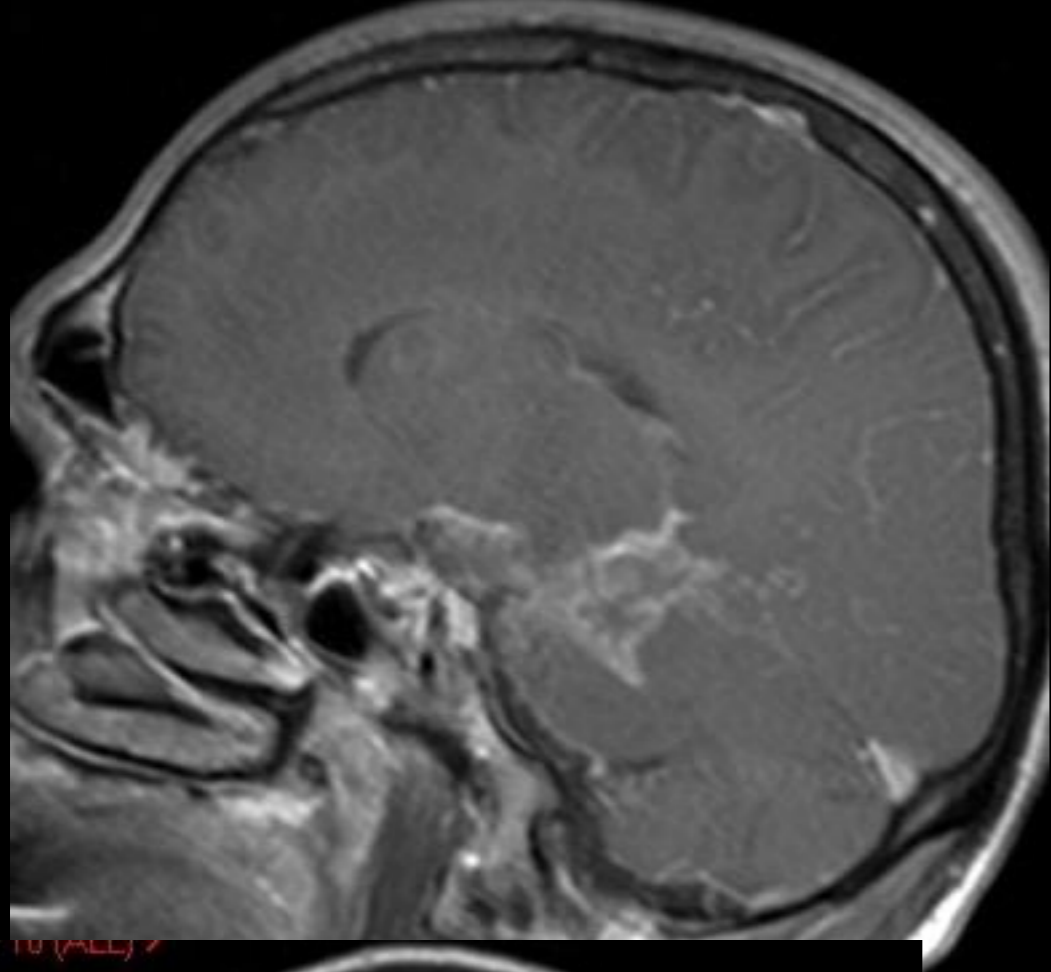
31 (ALL) >

Yaygın iskemi

31 (ALL) >



Bazal menenjit

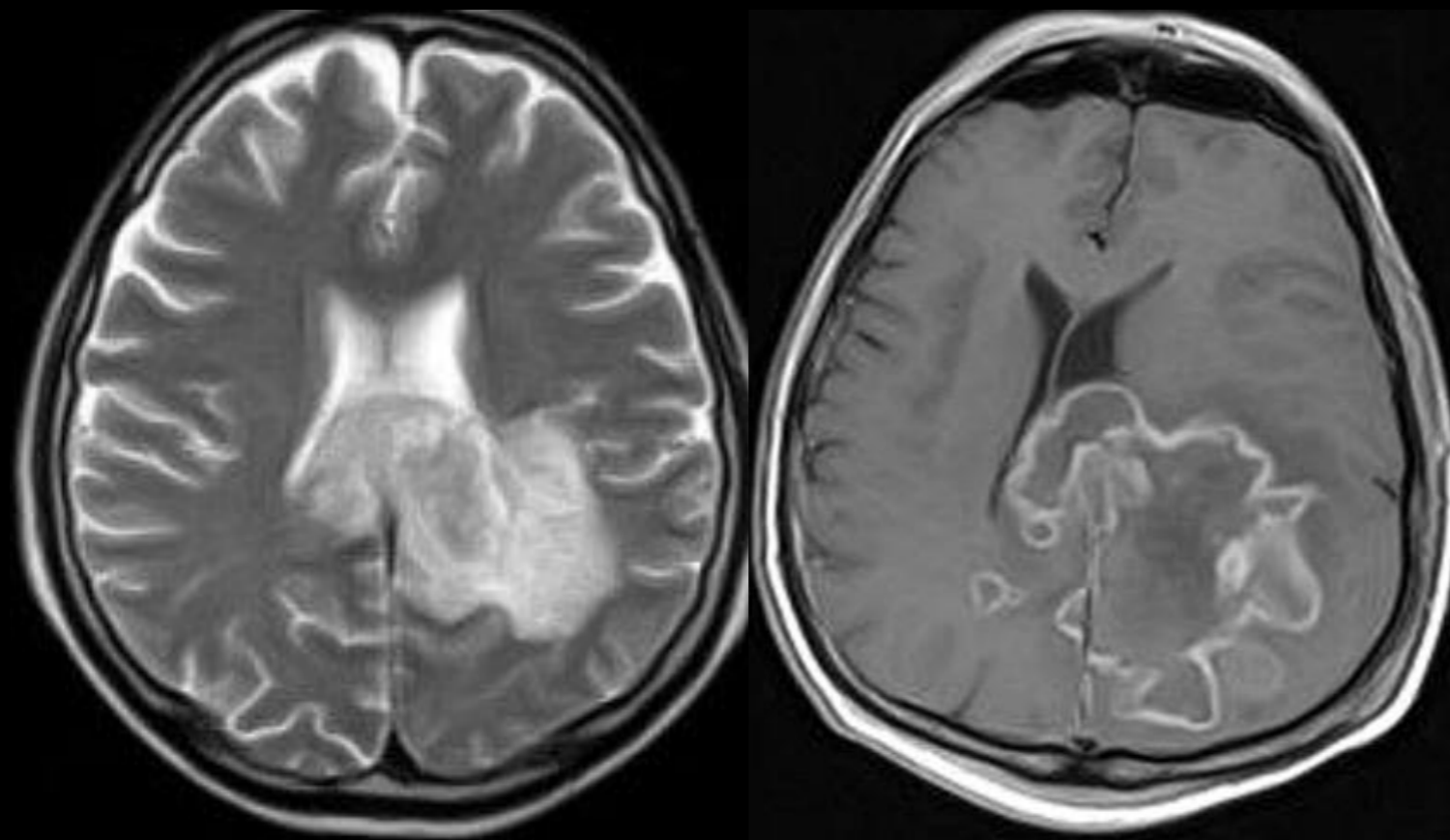


Tüberküloz menenjit

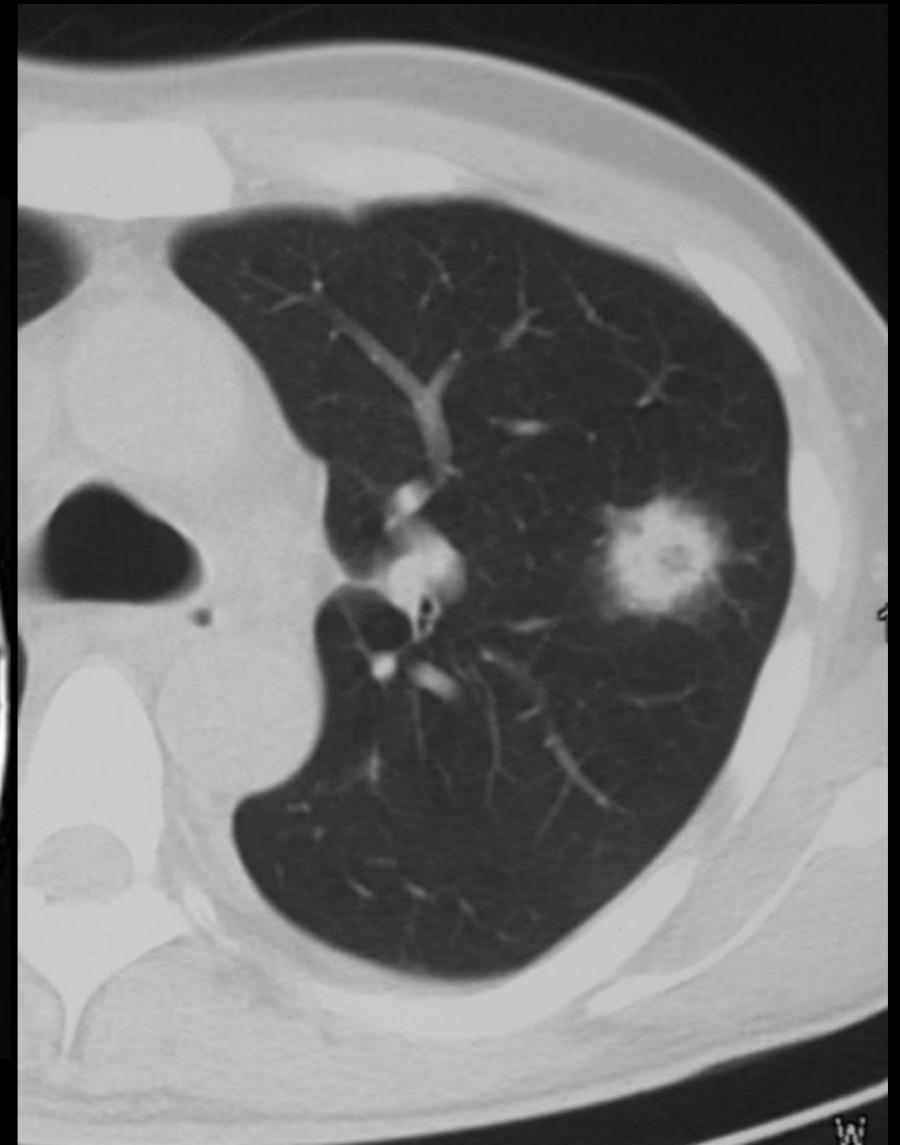
FIRSATÇI İNFEKSİYONLAR

- TOXO
- MUKOR
- ASPERGİLOZ
- CANDİDİAZ
- KOKSİDİOMİKÖZ
- KRİPTOKÖKÖZ

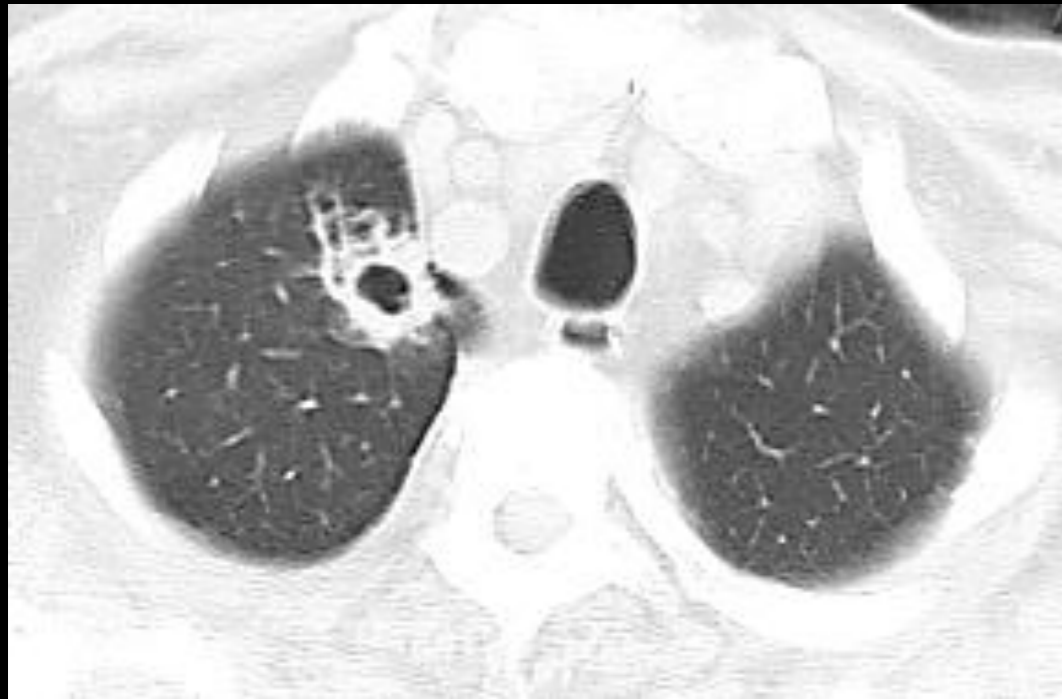Fungal enfeksiyon



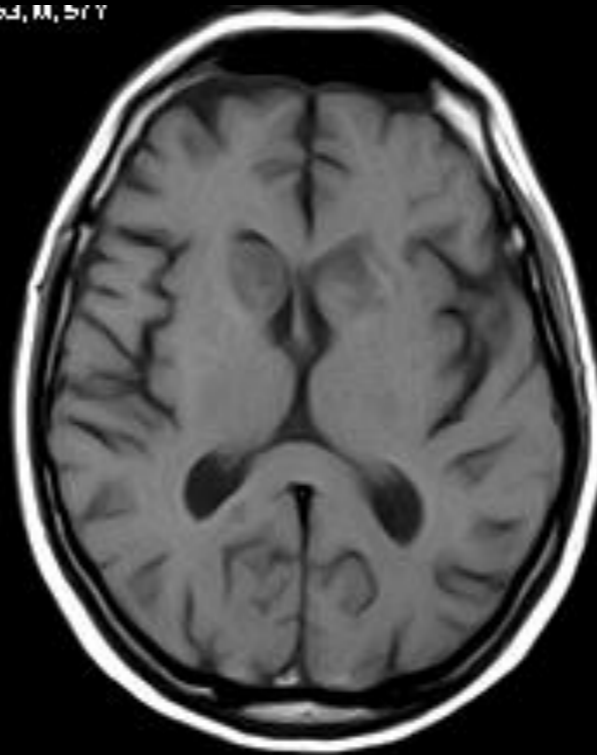
Aspergilloma



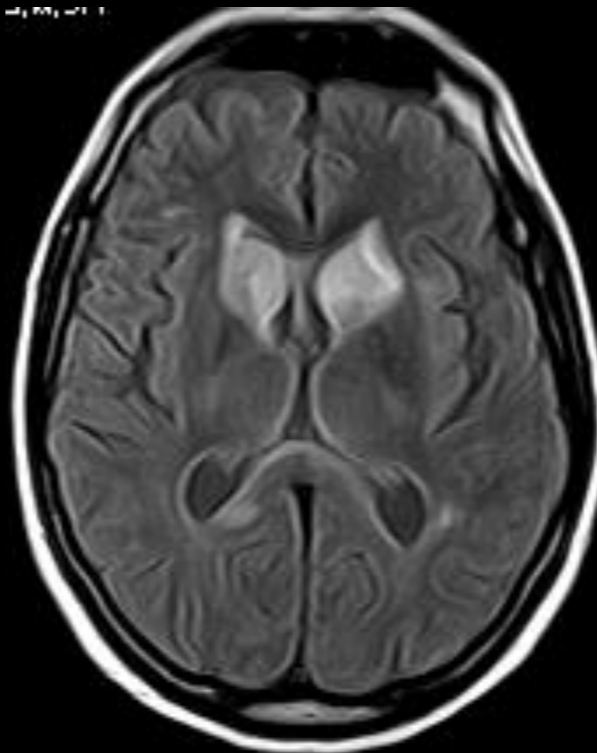
Fungal enfeksiyon



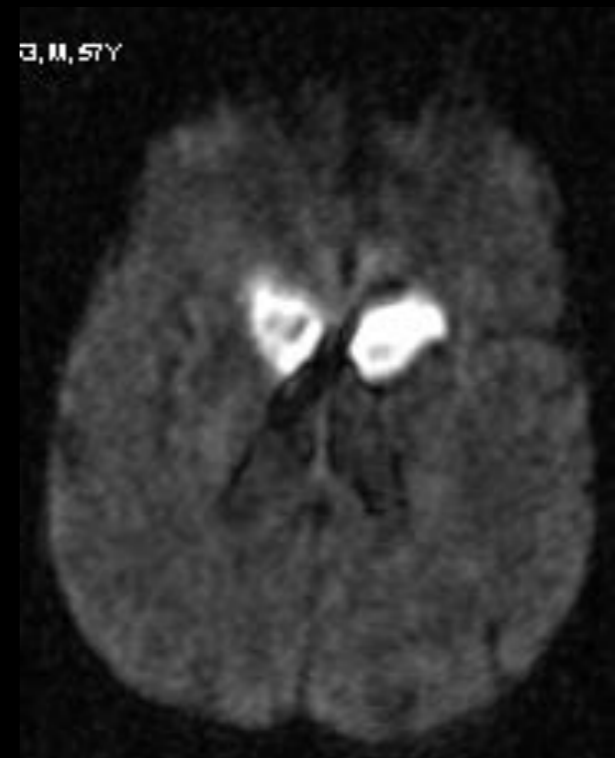
53, M, 57Y



53, M, 57Y



53, M, 57Y



Aspergilloma

P ICKE
8/S
n-66

Y 1
c-02
1 PM
12

AH CERRAHPASA
Sy 4
02 PM
0

00.0
000.0
29.0
1:12*2

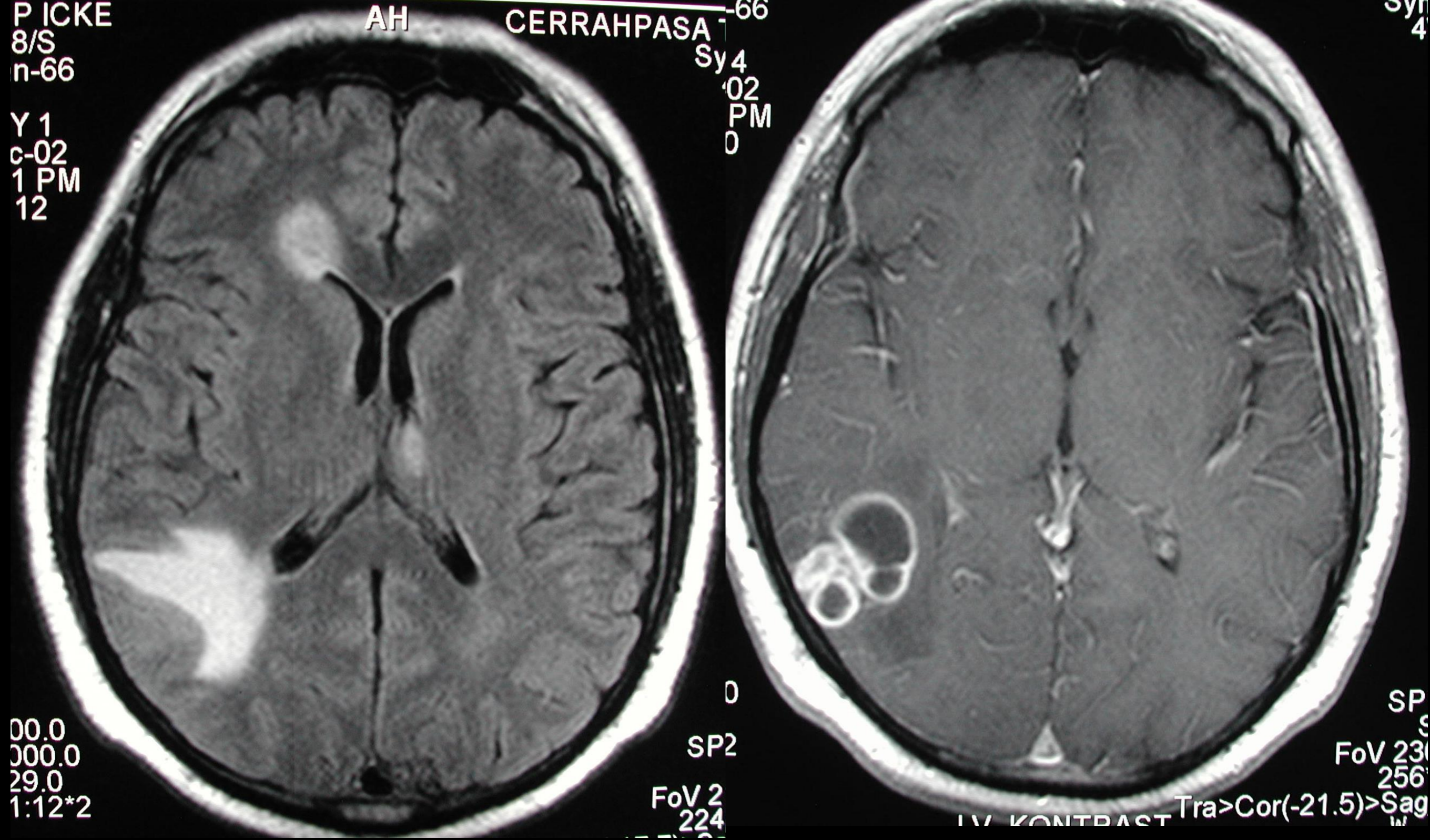
0
SP2
FoV 2
224

Sy 4
4

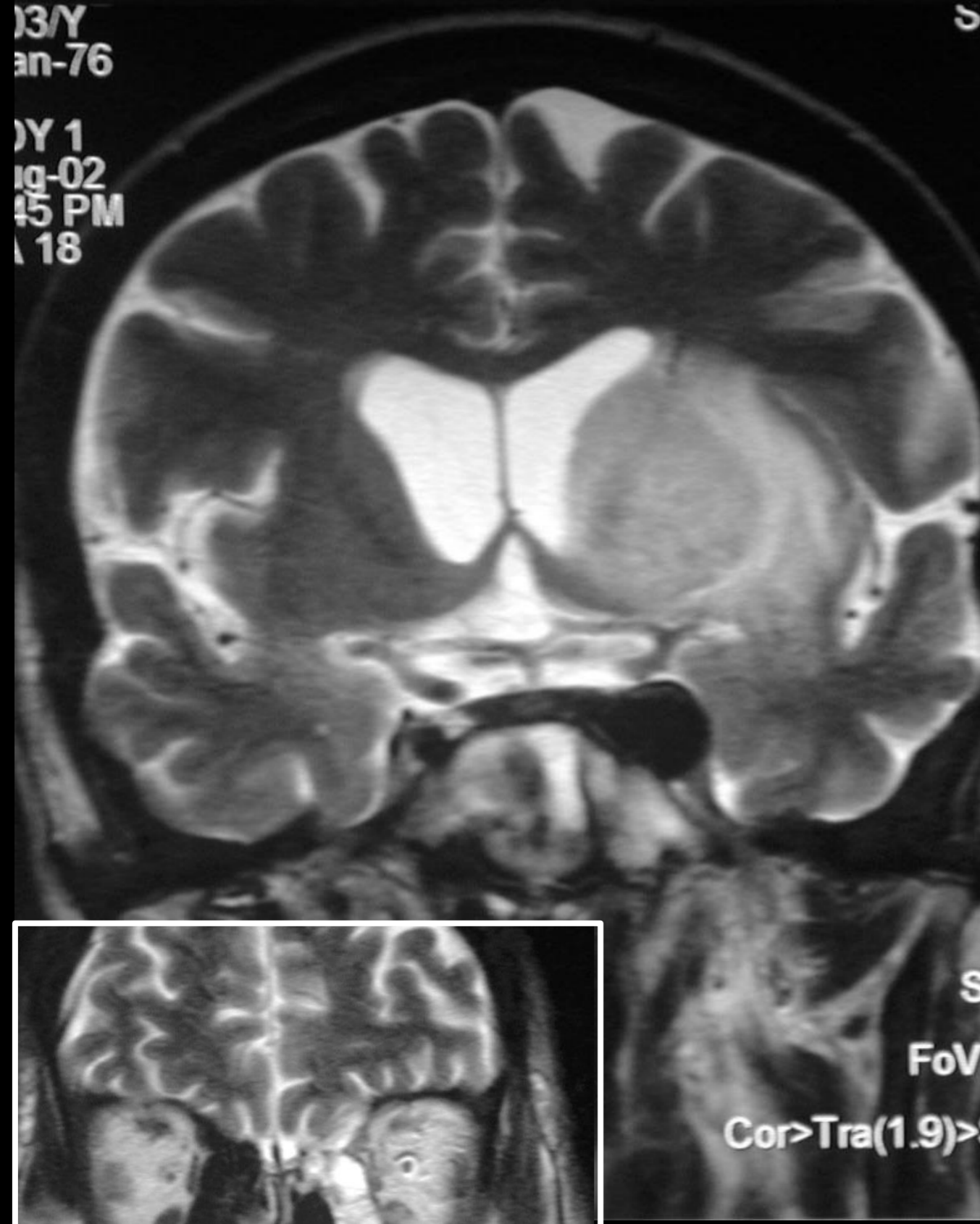SP
FoV 230
256
Tra>Cor(-21.5)>Sag

IV KONTRAST

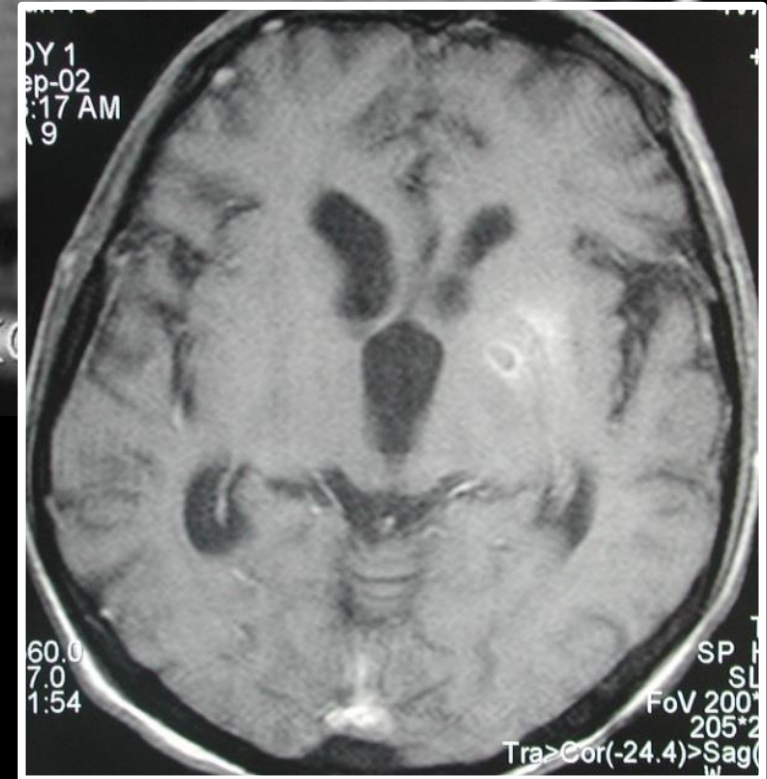
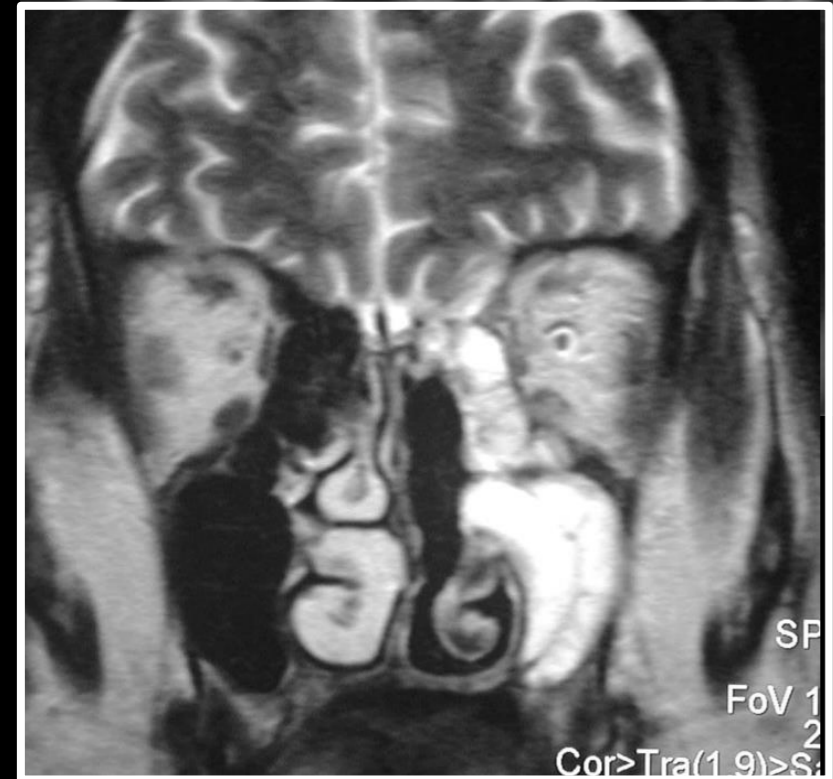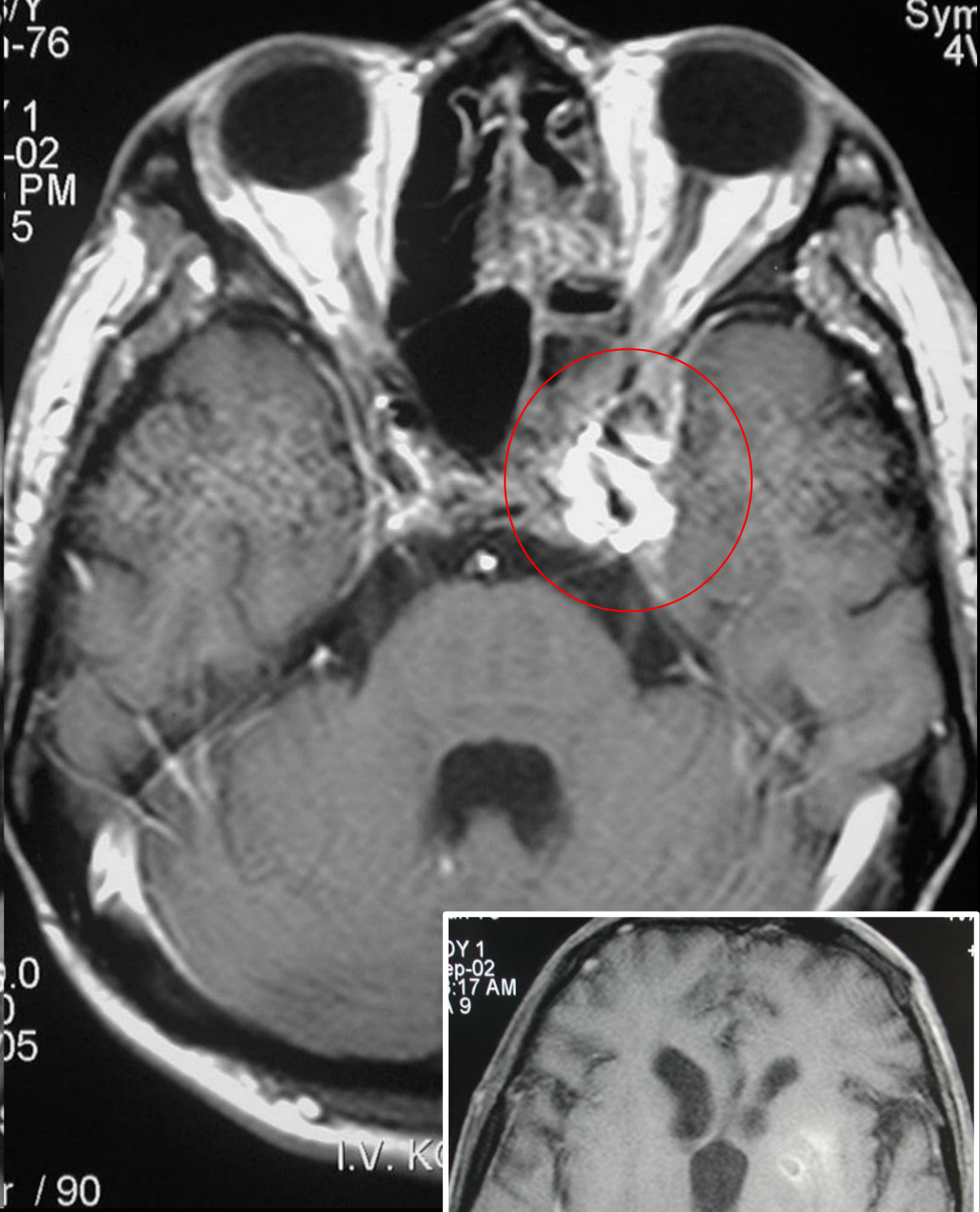
NOKARDİA



3/Y
an-76
DY 1
ig-02
45 PM
18

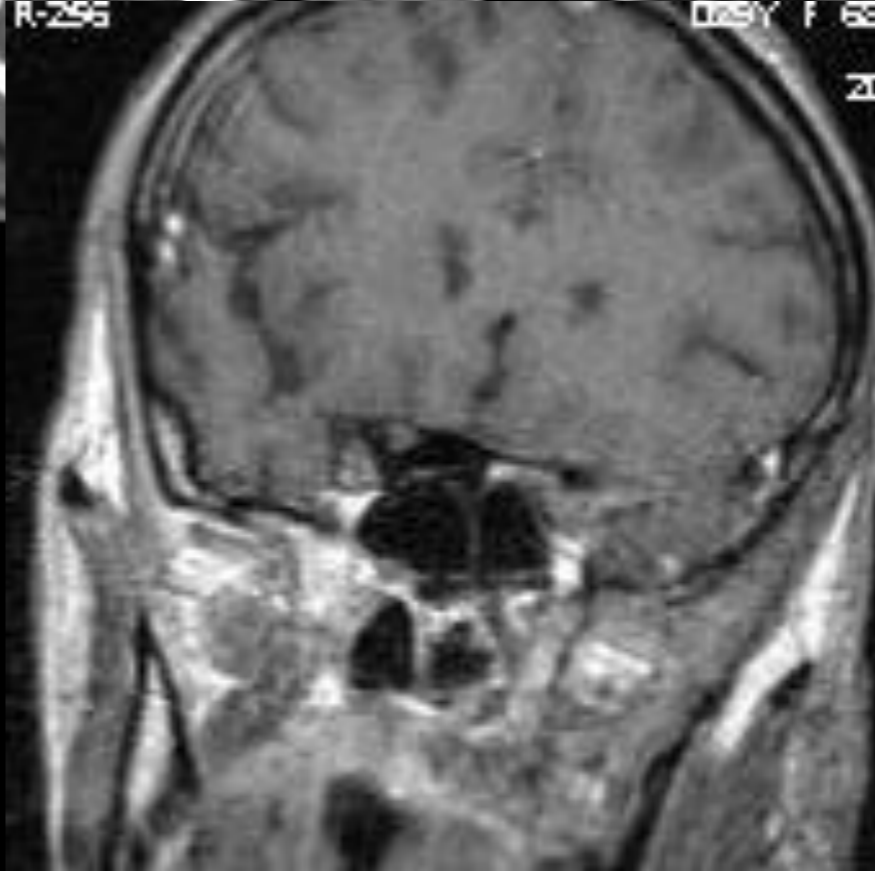
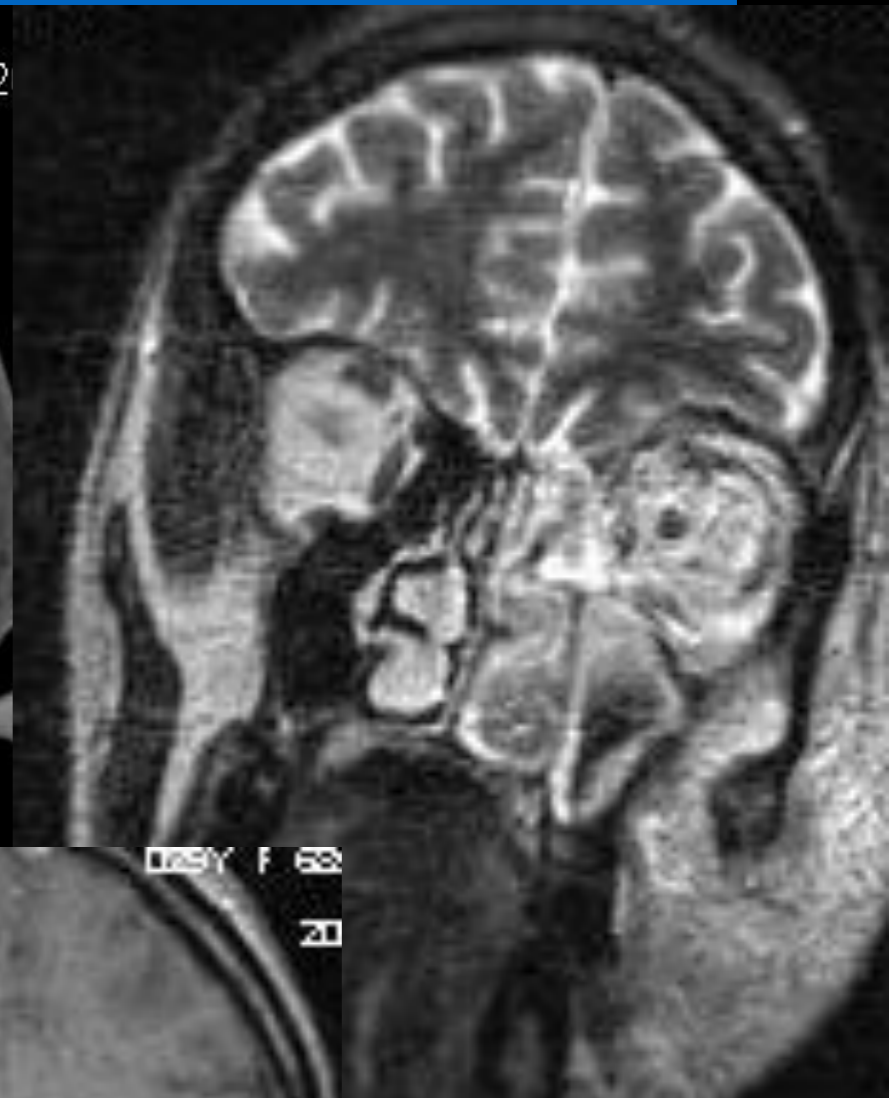
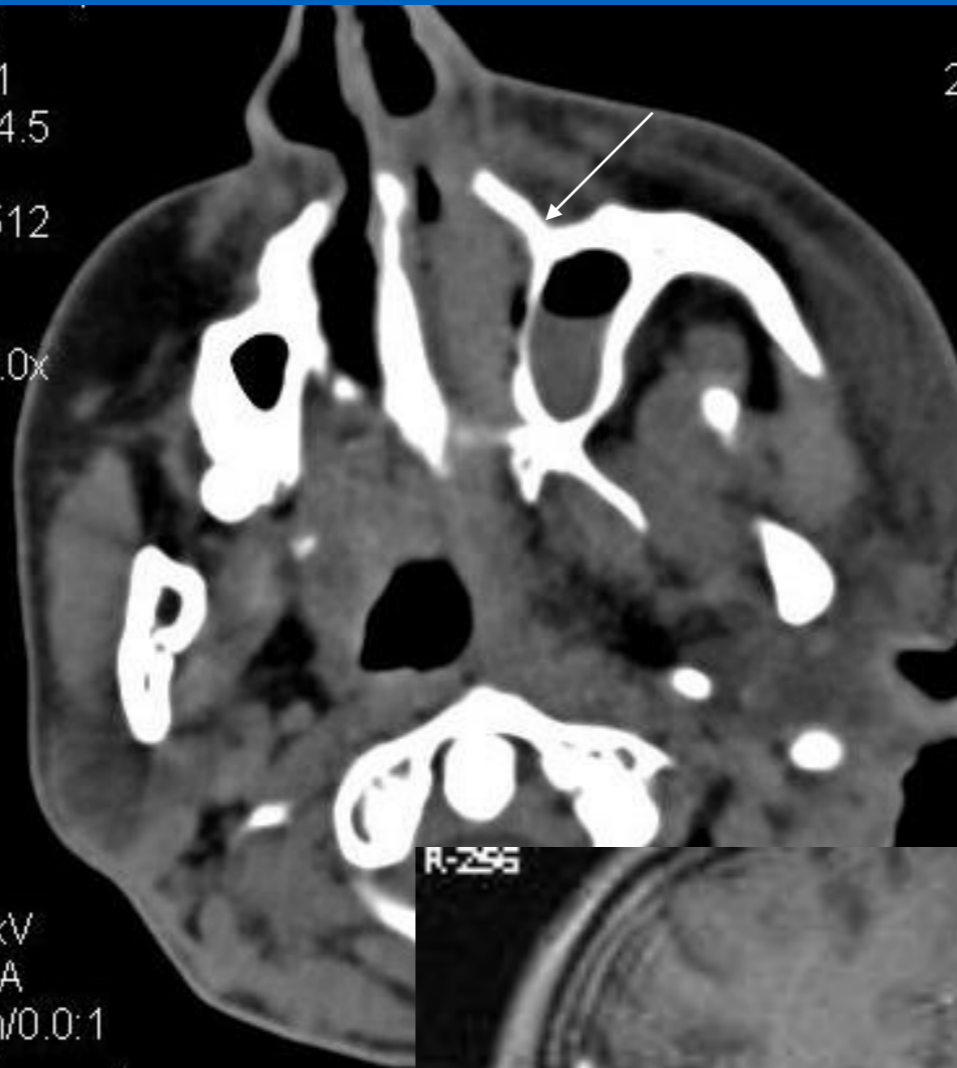
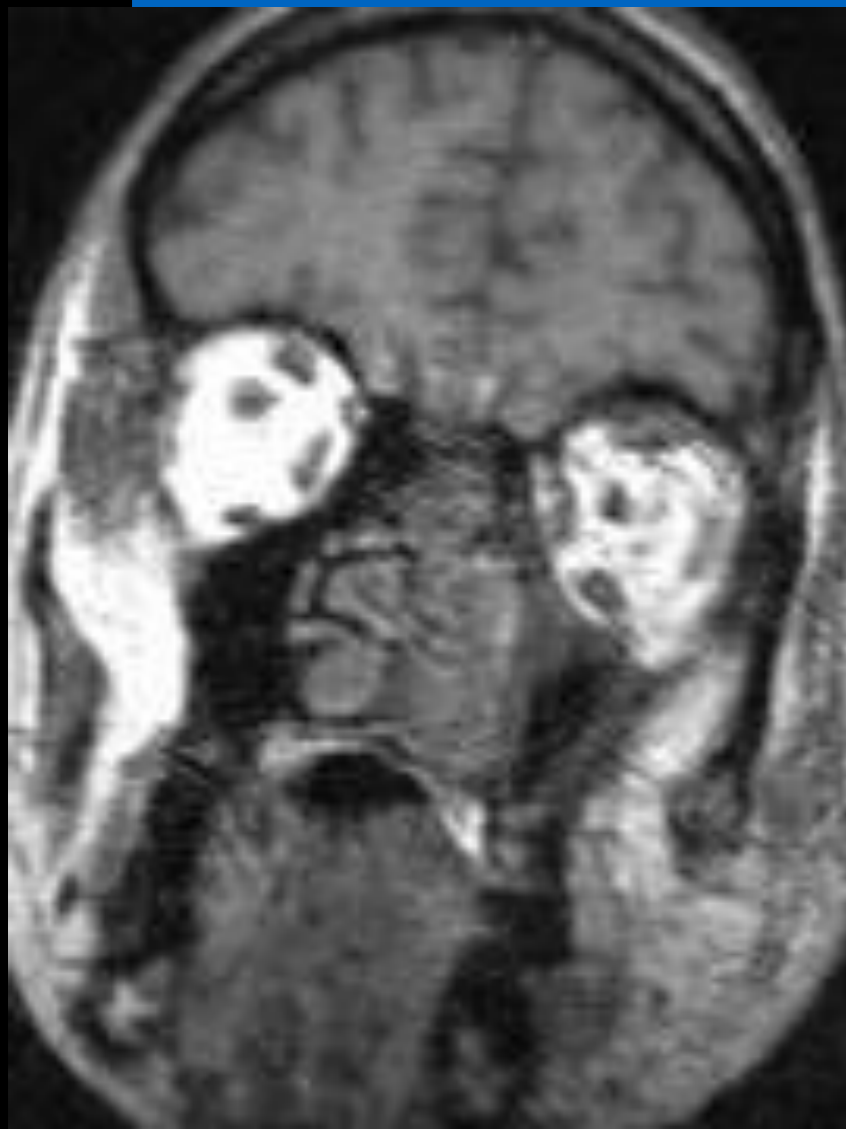
S/Y
-76
1
-02
PM
5



MUKORMIKOZ

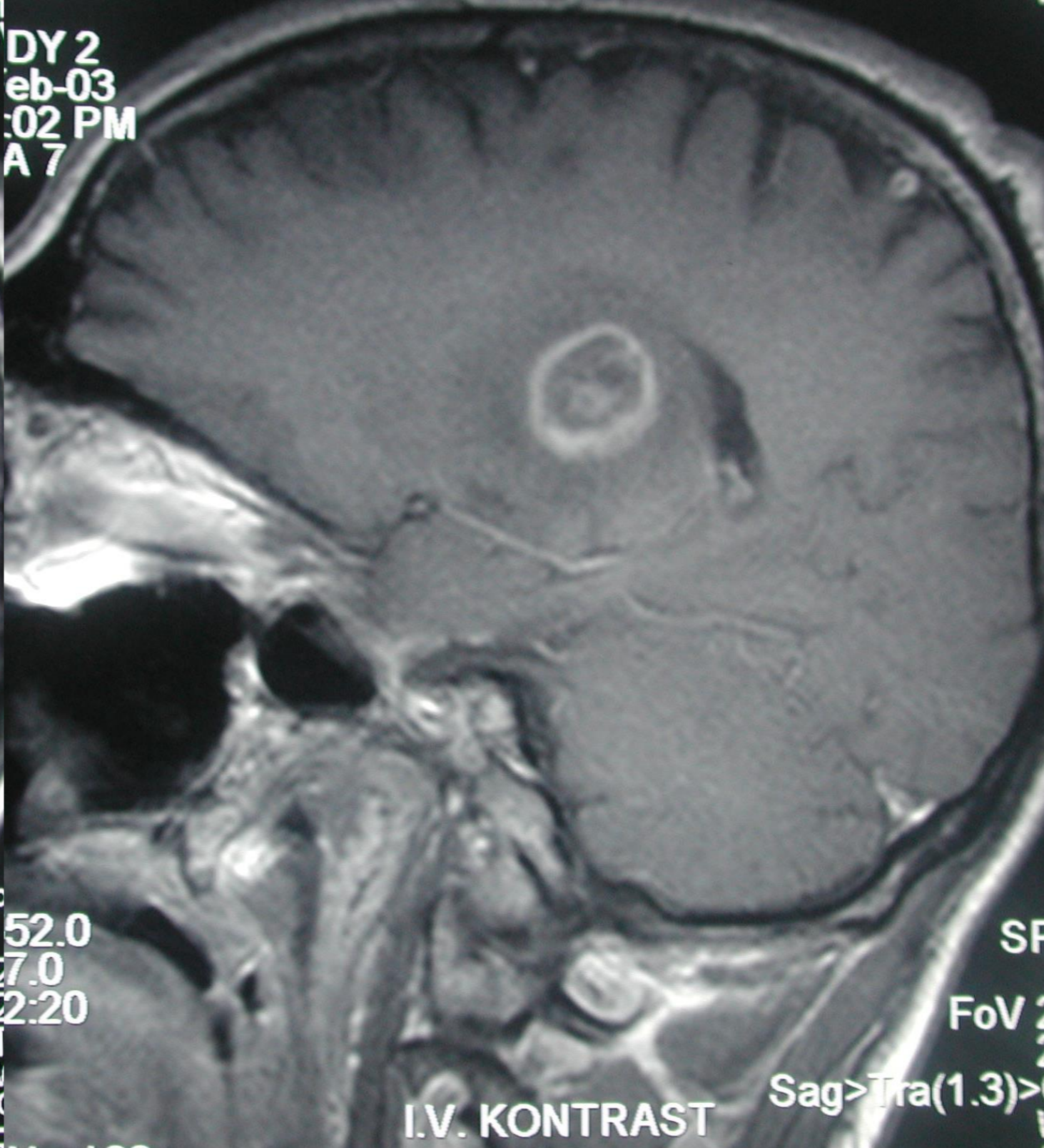
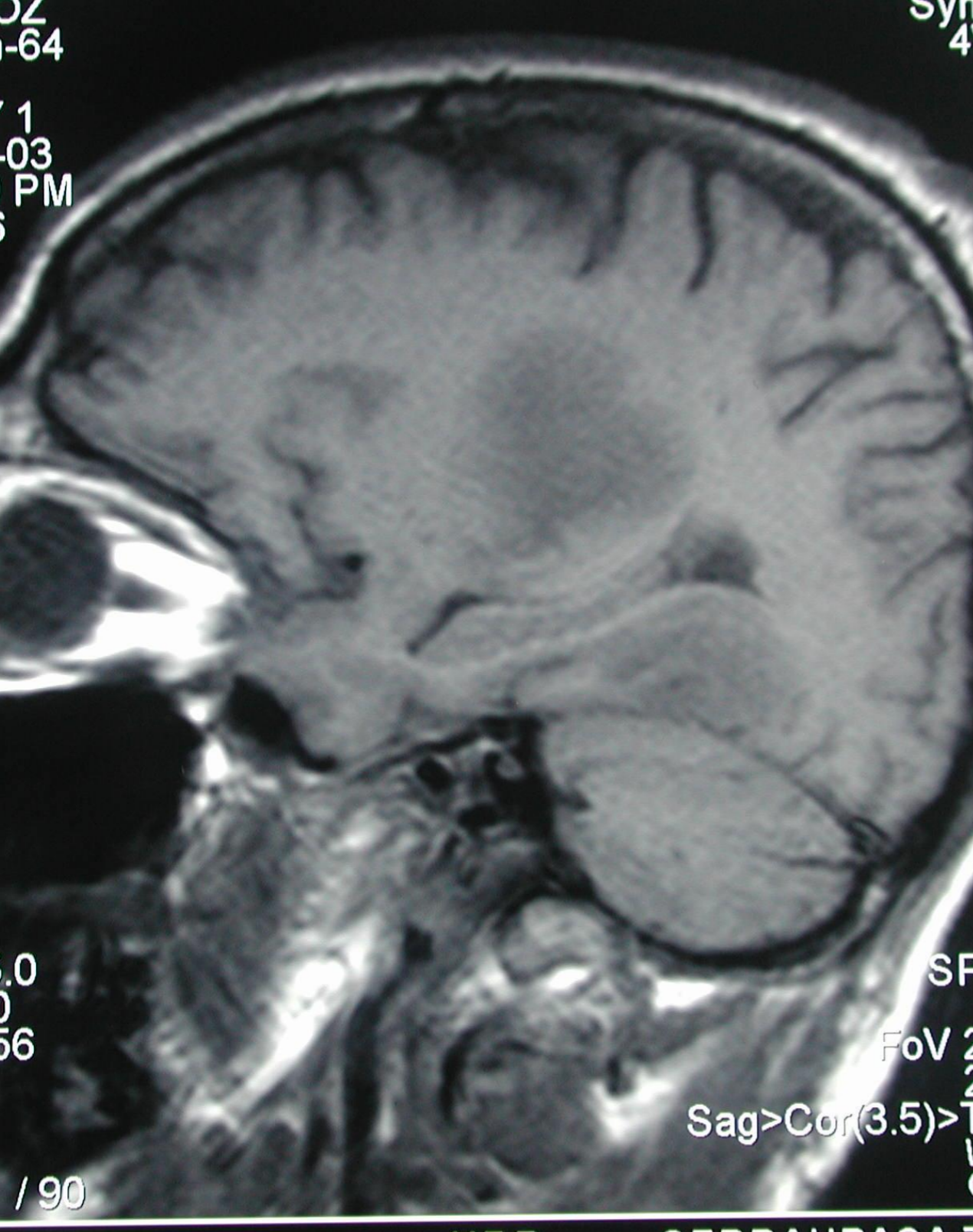
Fungal enfeksiyon

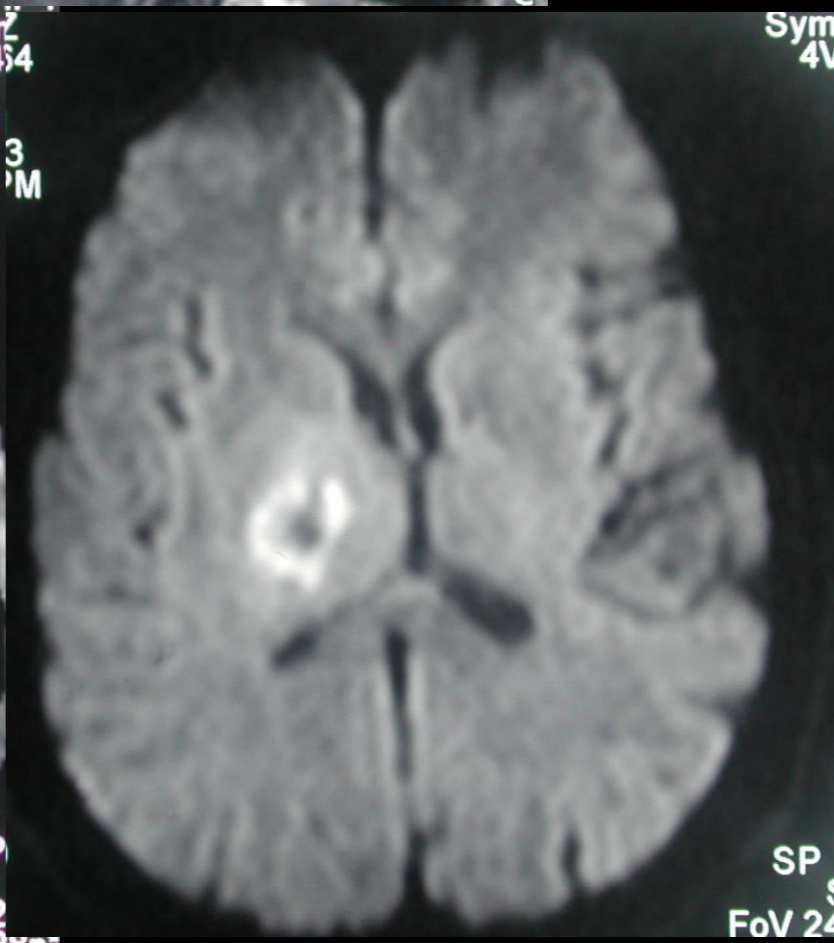
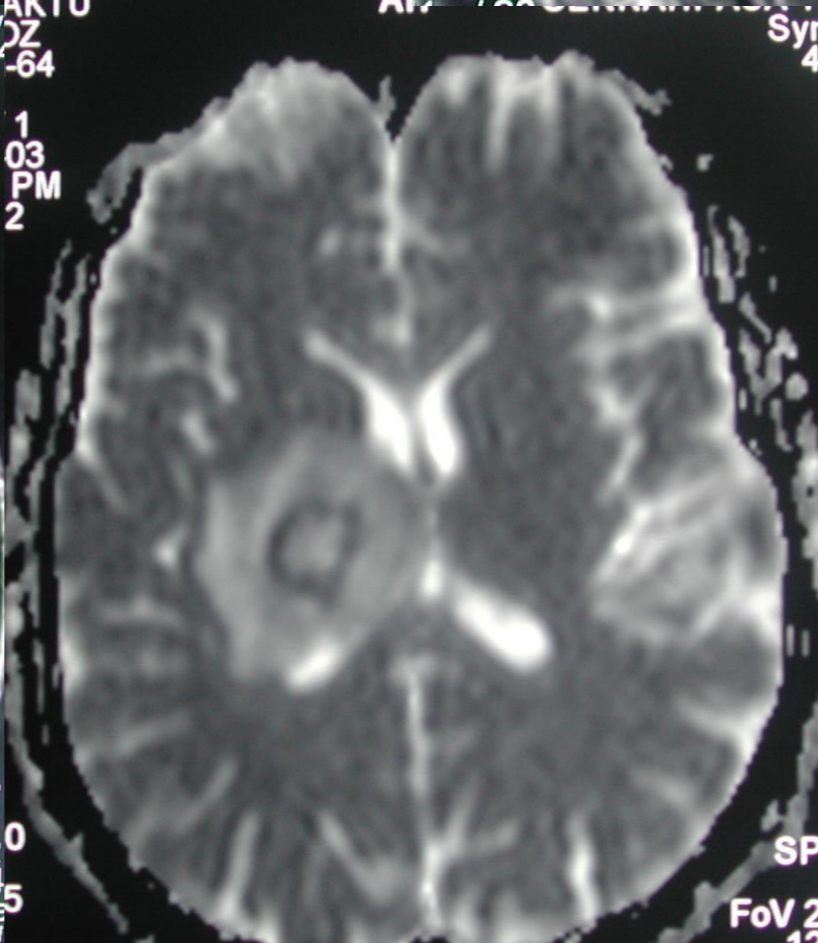
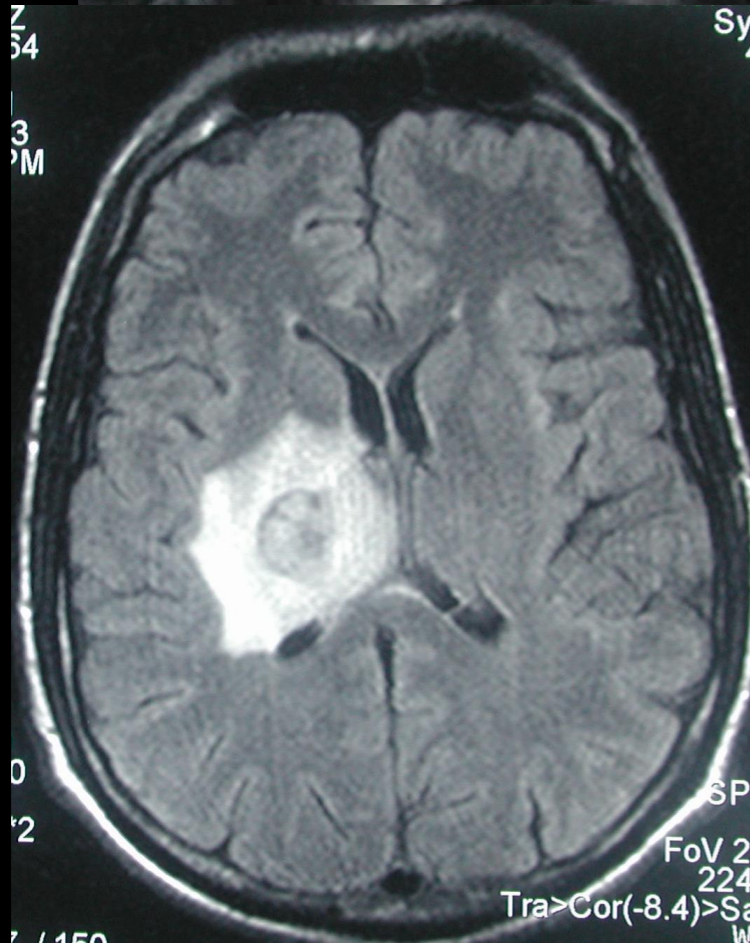
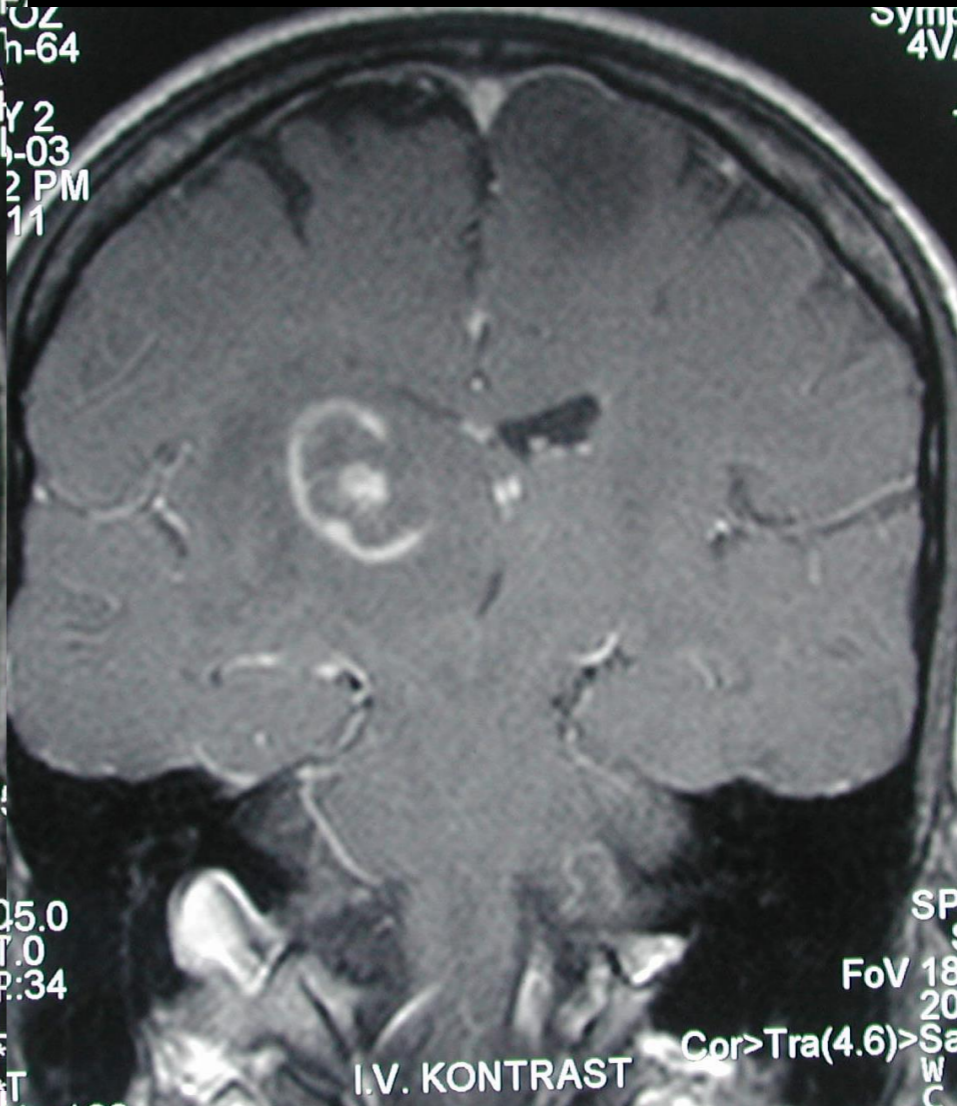
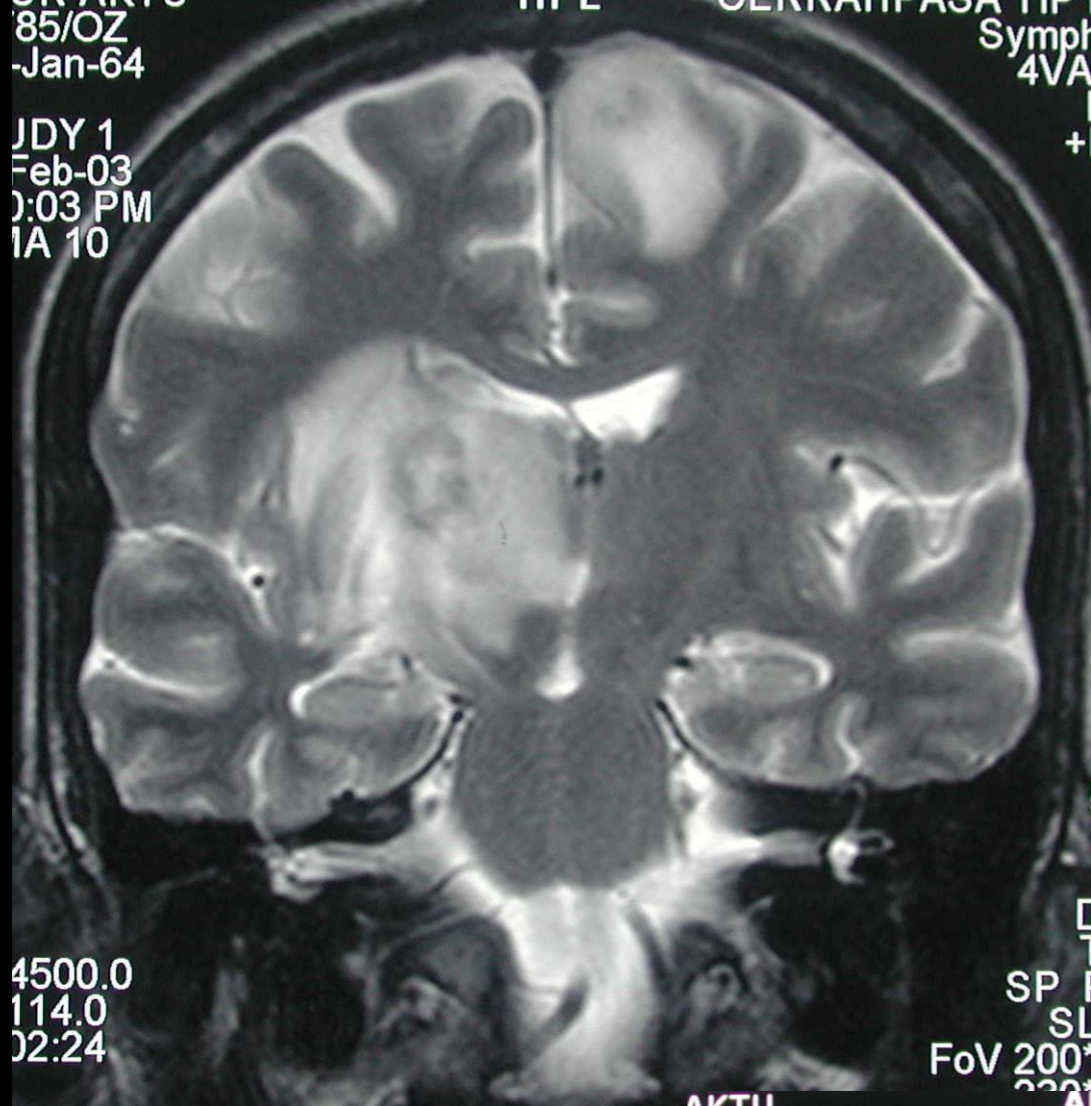


Mukormukozis

TOXO

- AIDSTE EN SIK SSS İNFEKSİYONU
- PERİVENTRİKÜLER SUBKORTİKAL
- TARGET SIGN
- R/O LENFOMA

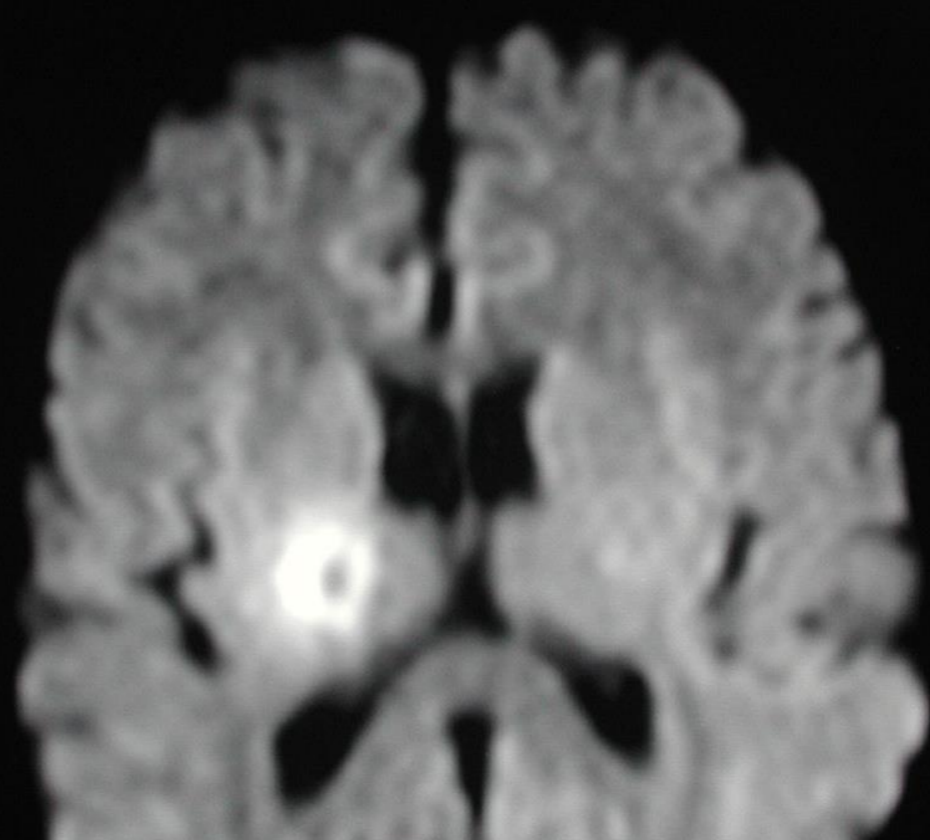
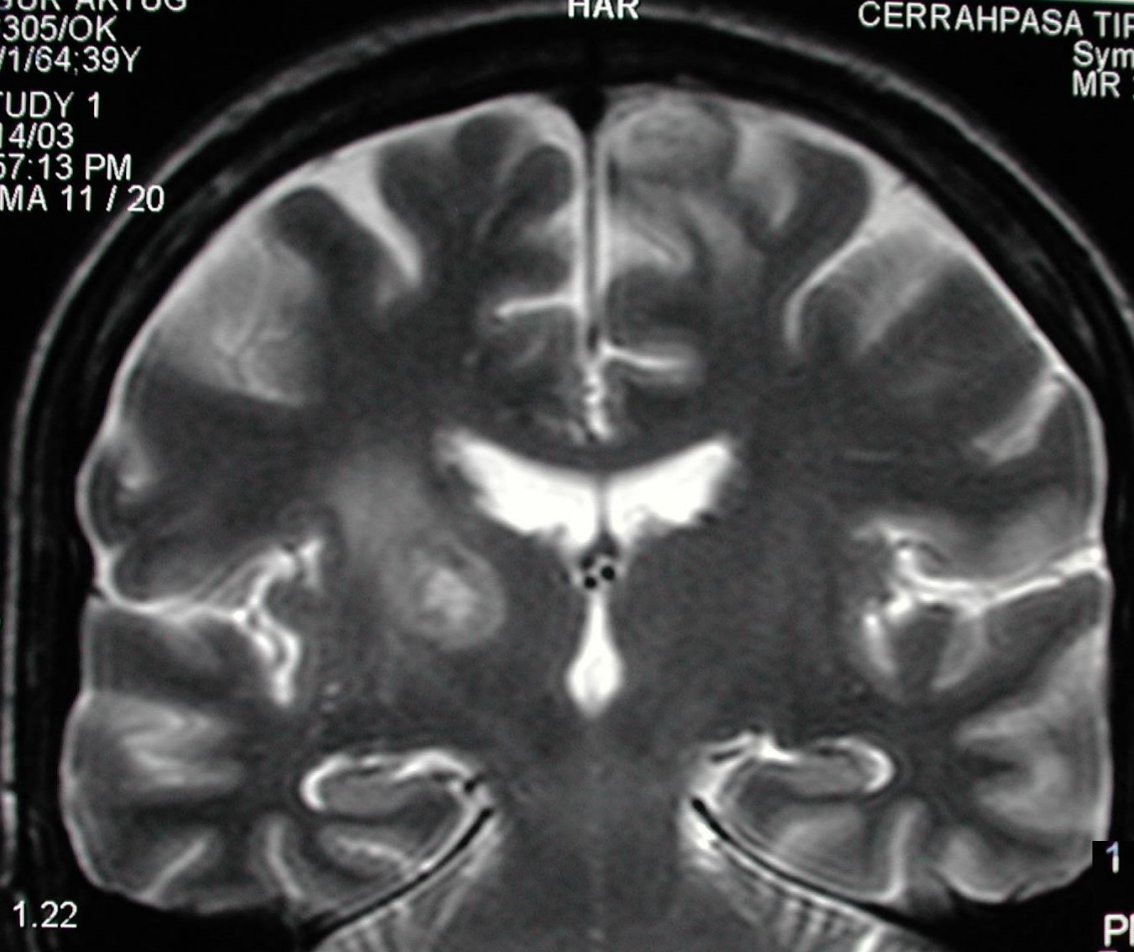




305/OK
11/64:39Y
STUDY 1
14/03
17:13 PM
MA 11 / 20

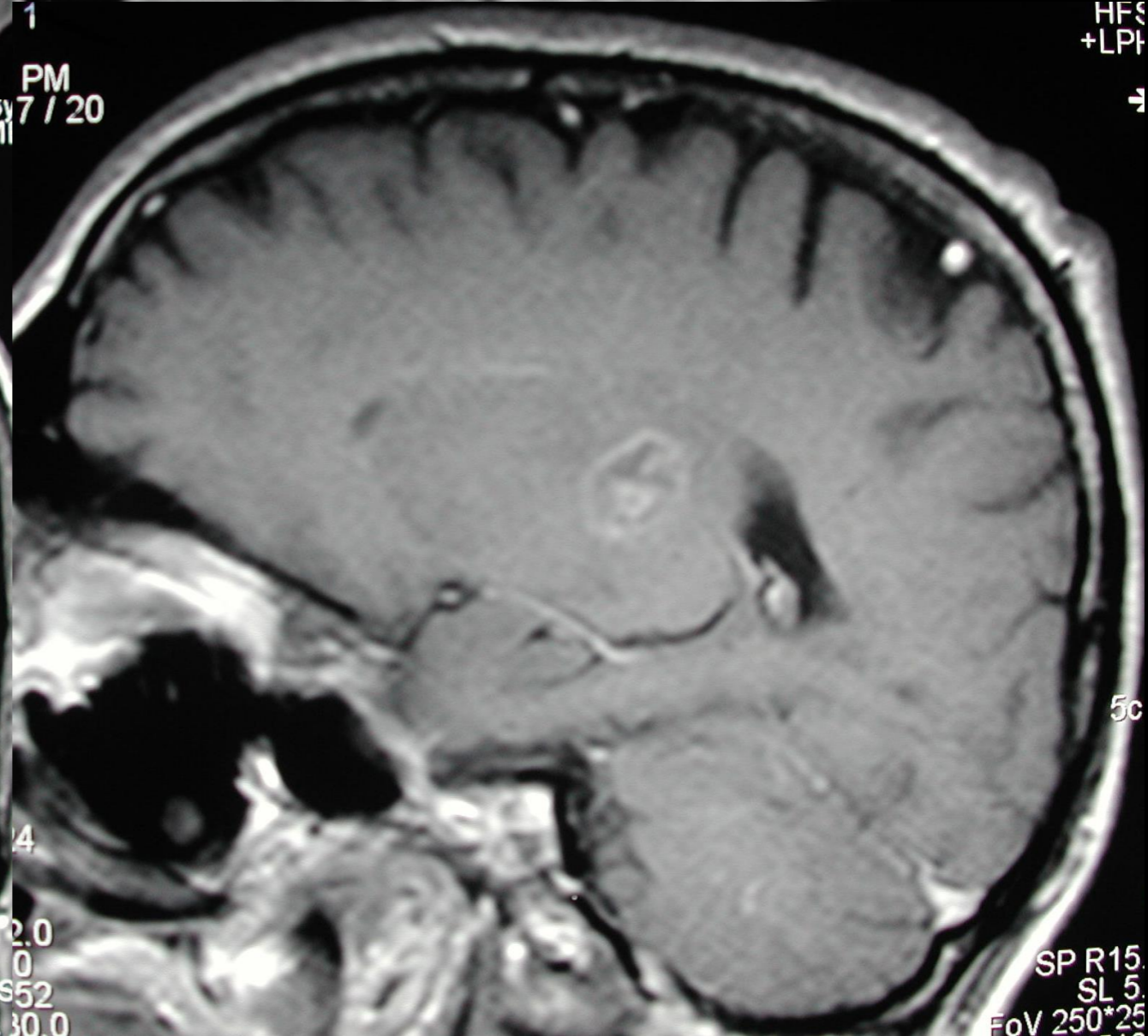
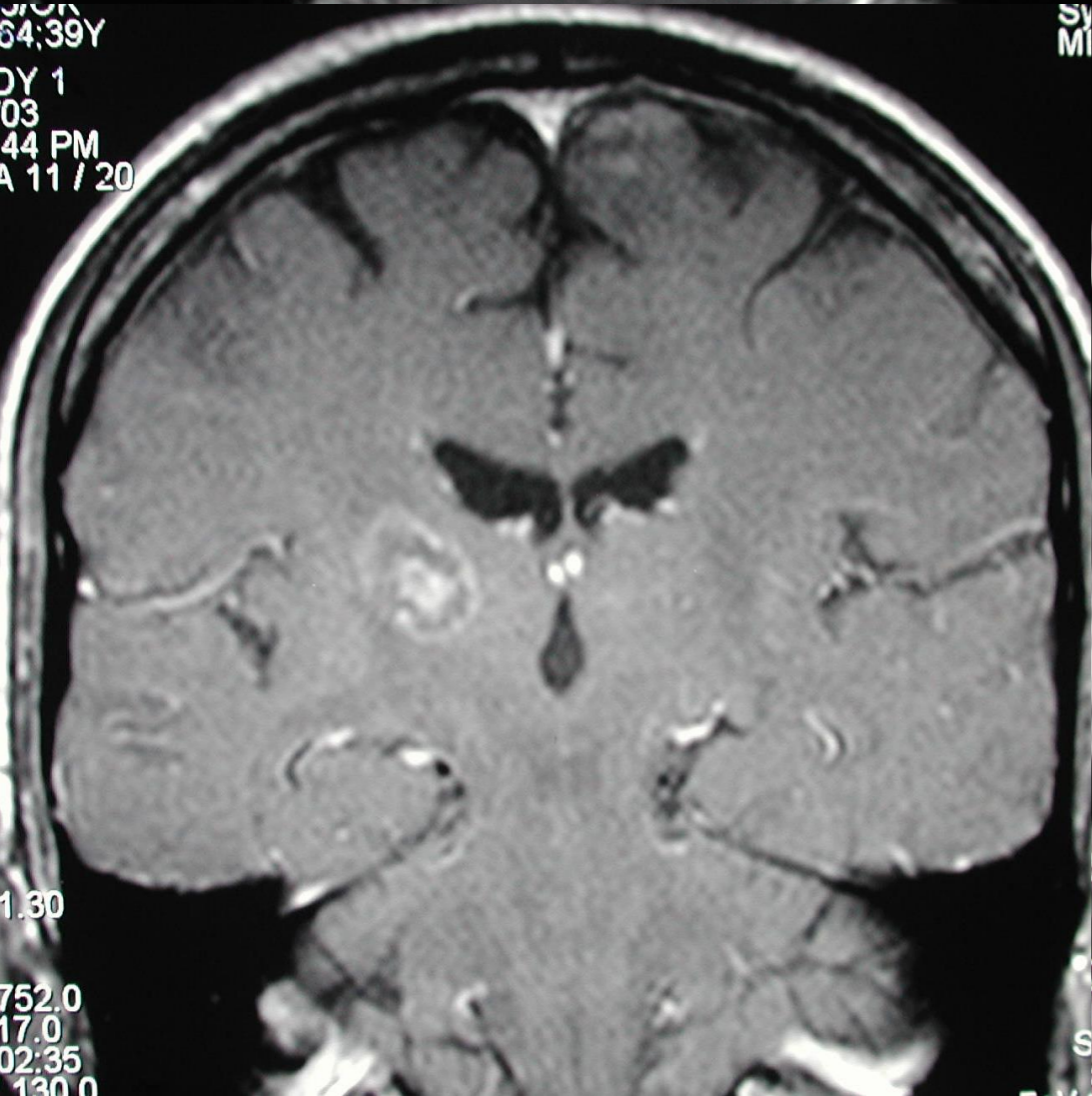HAR

CERRAHPASA TIF
Sym
MR :

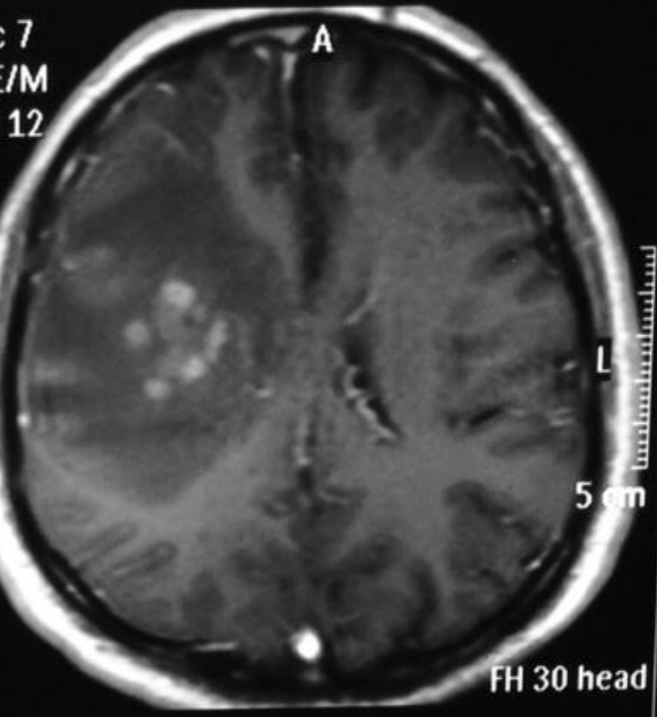
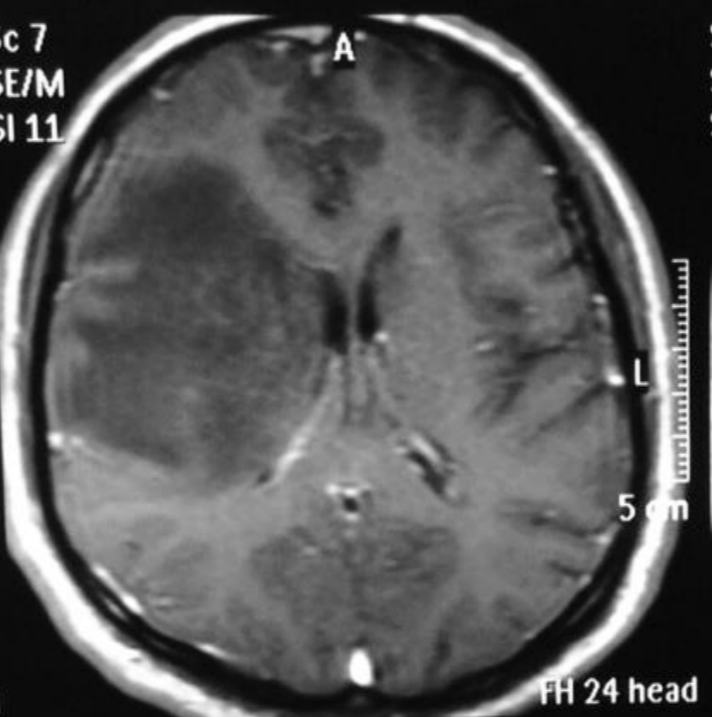
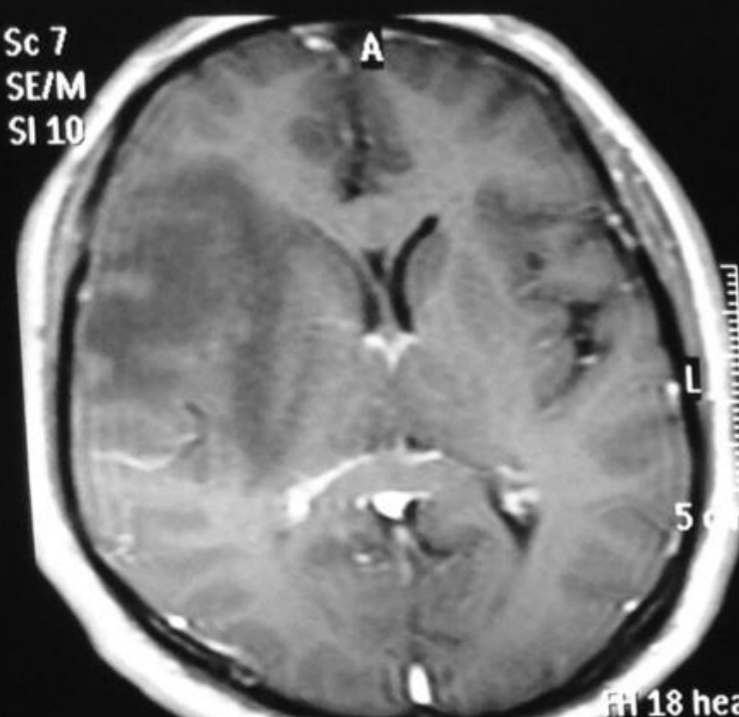
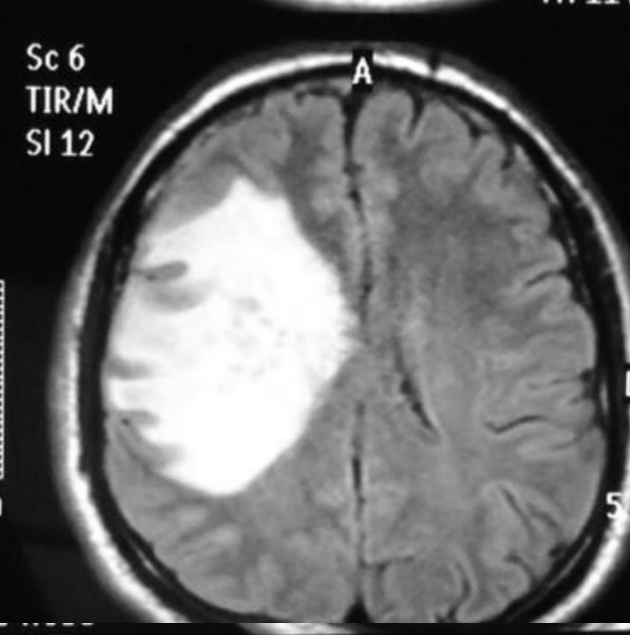
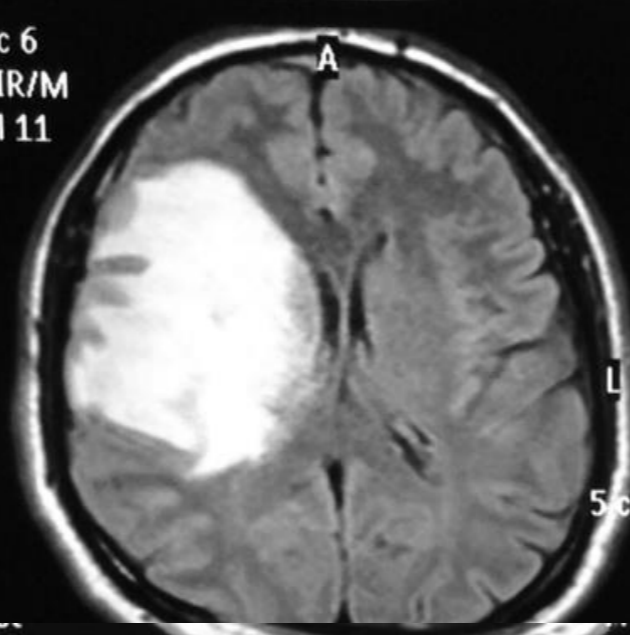
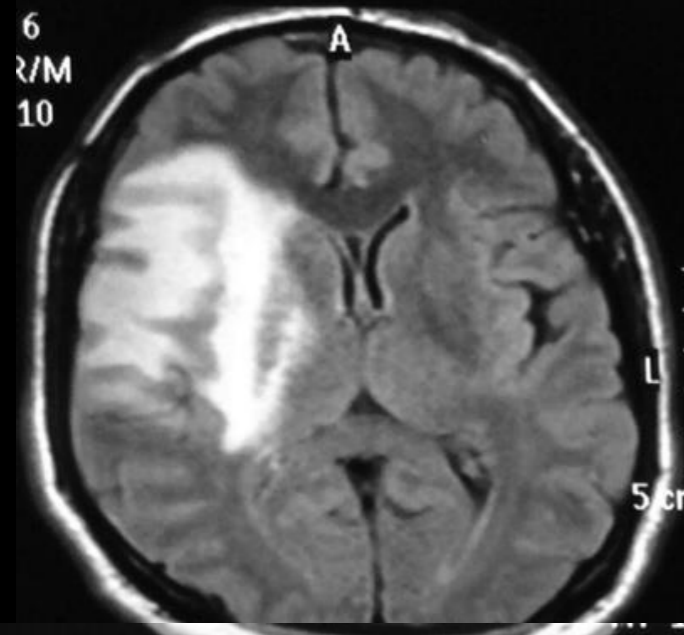
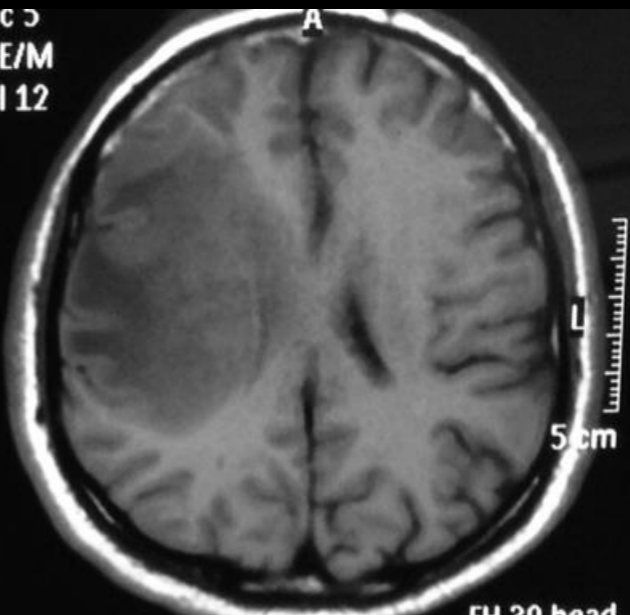
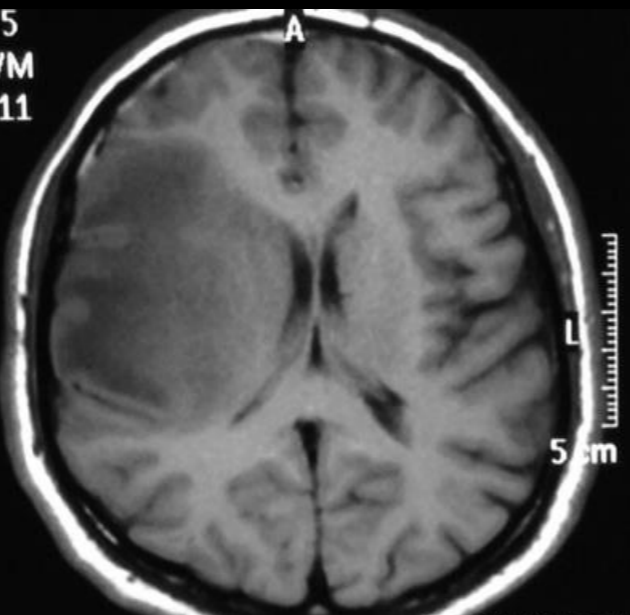
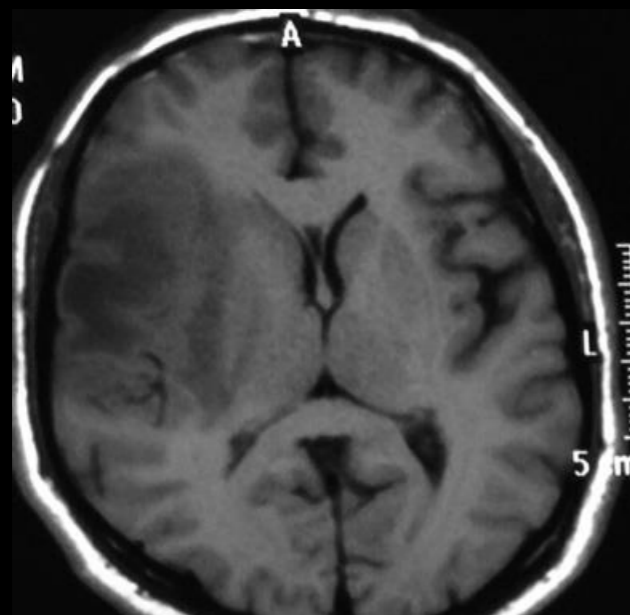


1.5 ay kontrol.

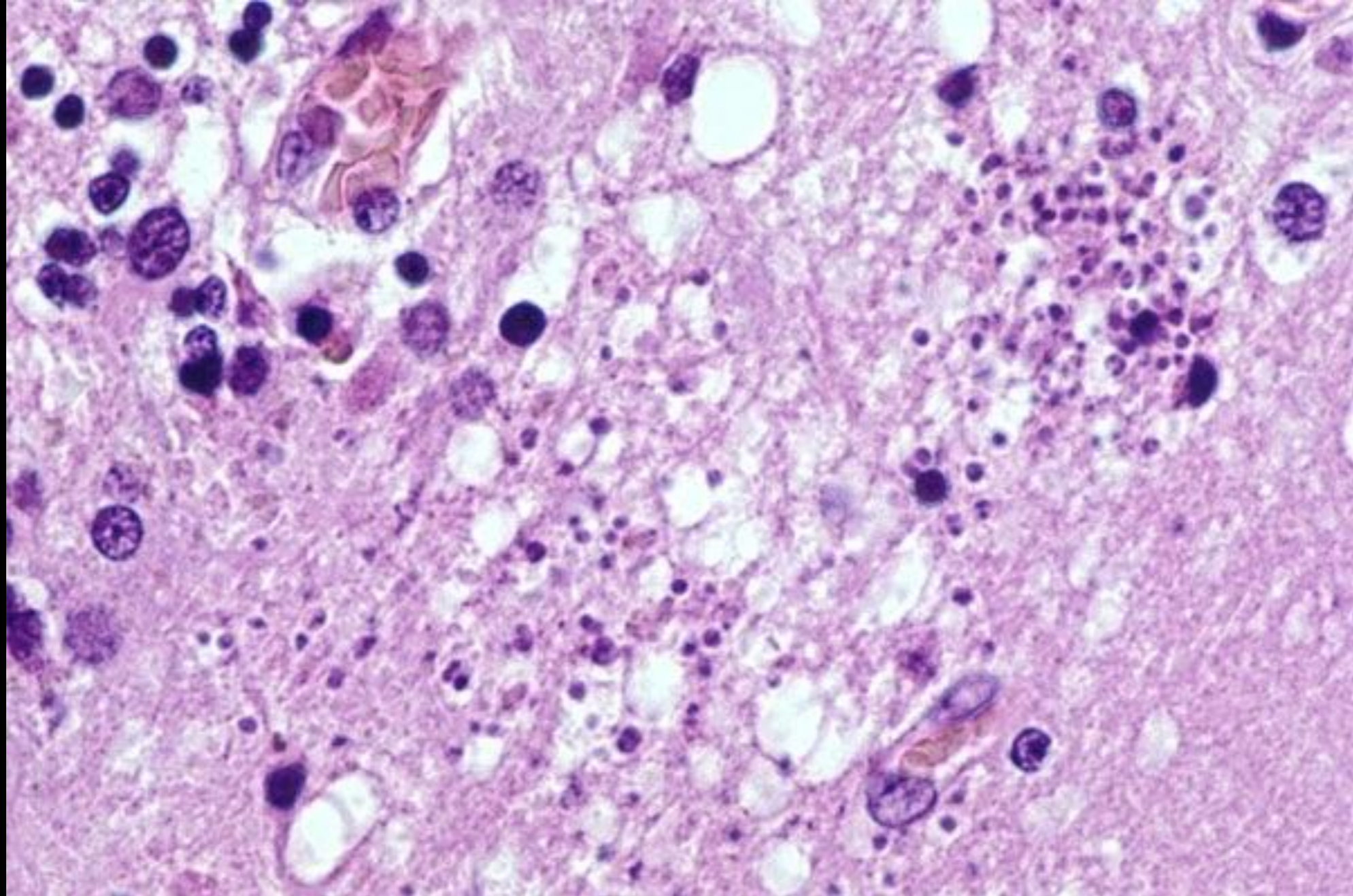
HFS
+LPH



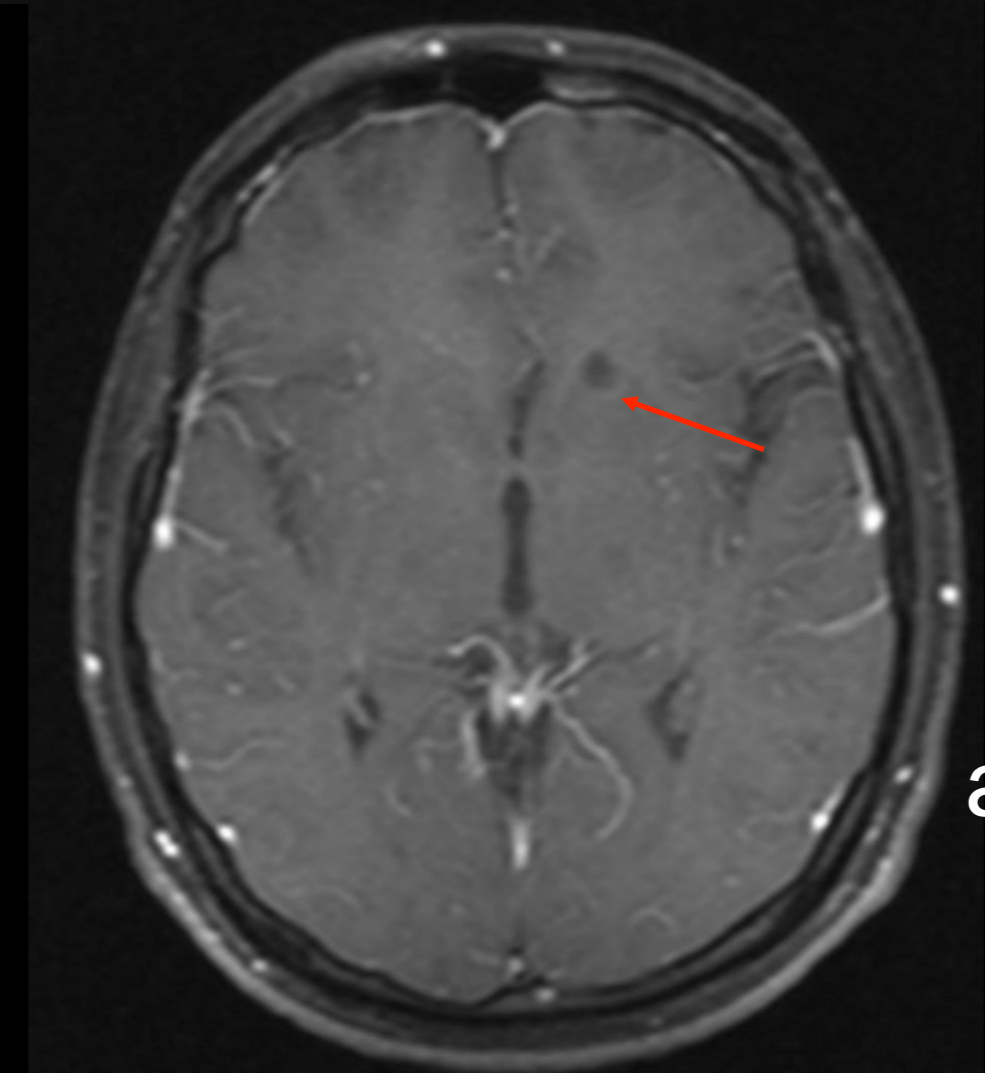
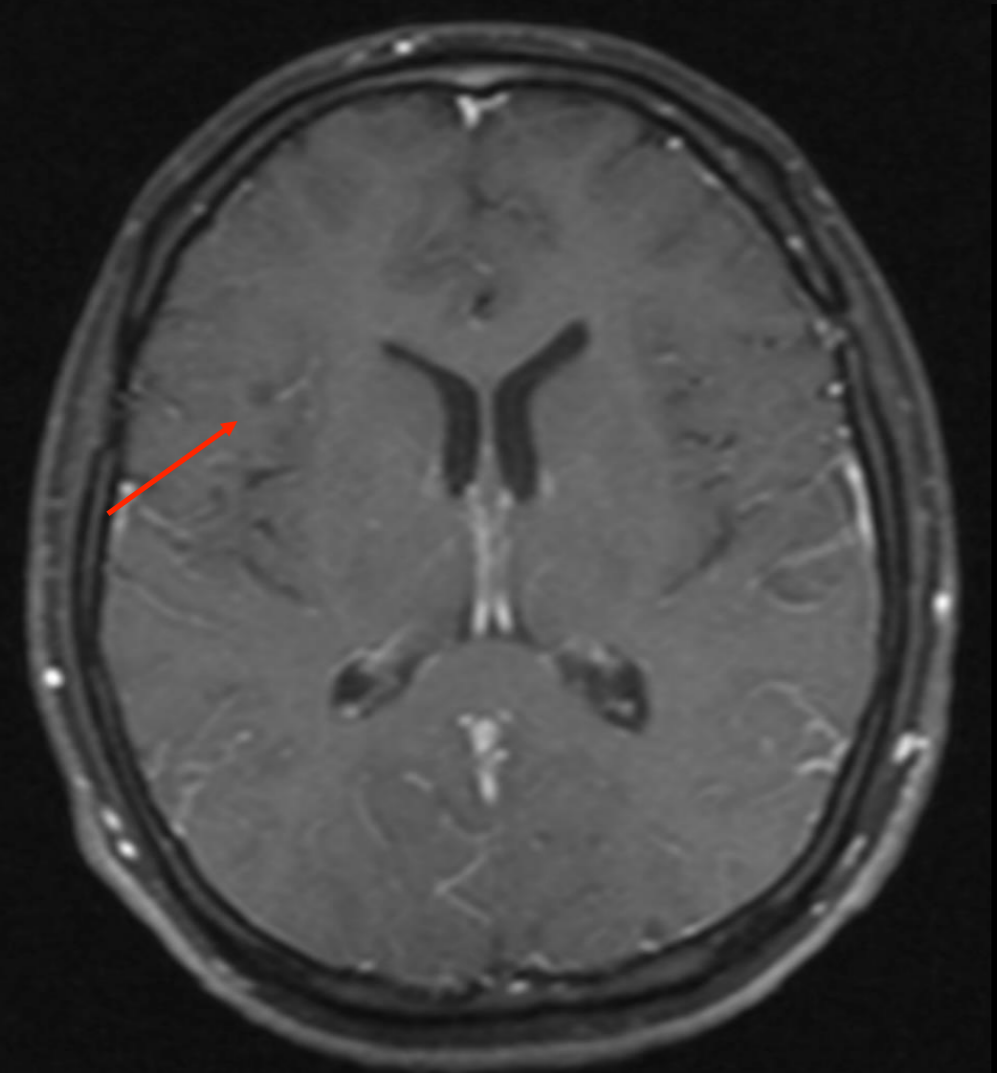
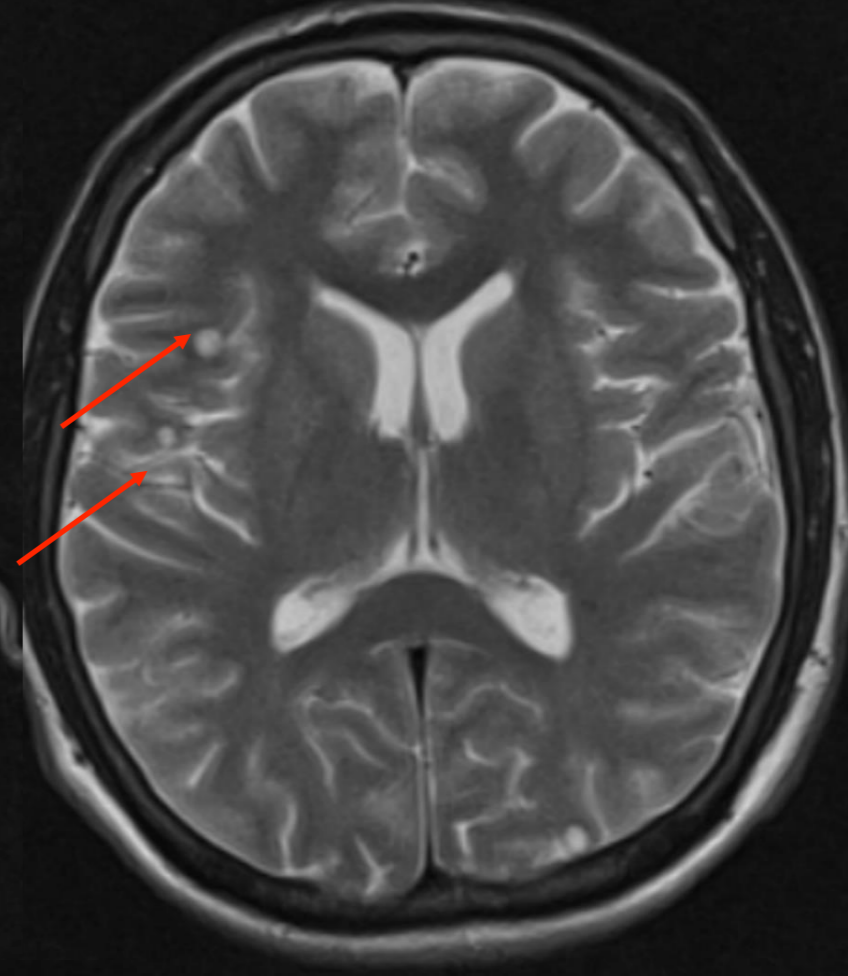
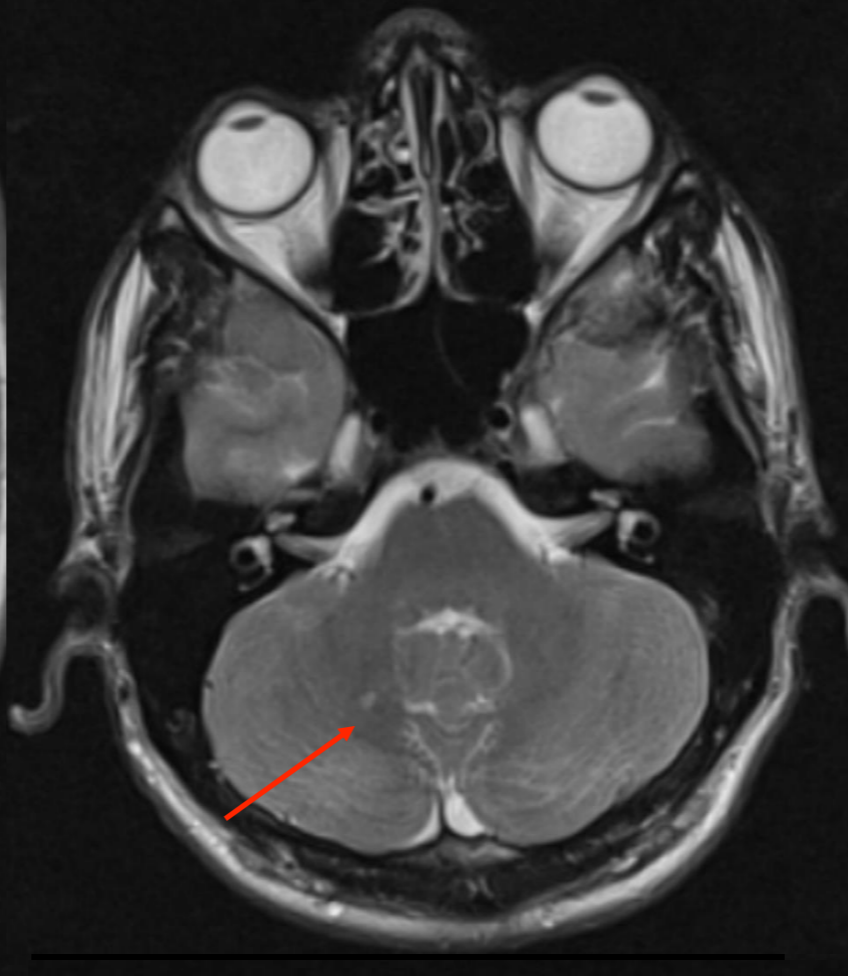
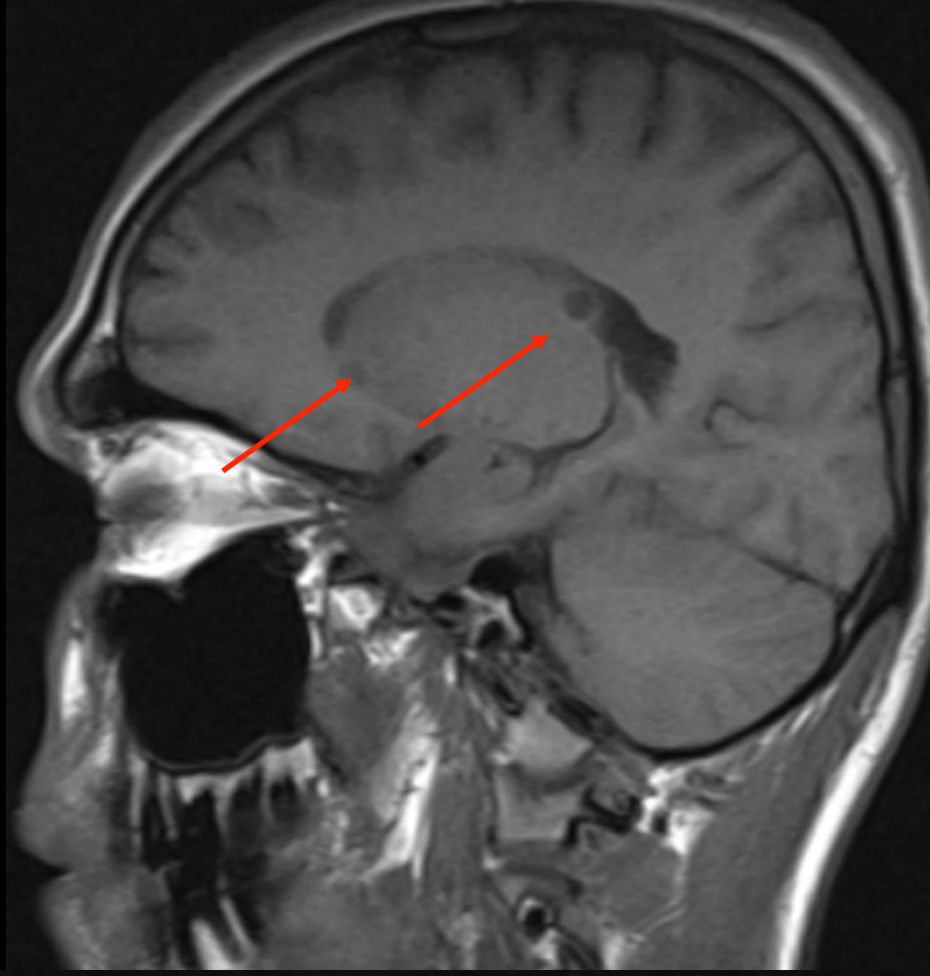
- 61 Y E
- 3 yıl önce mesane karsinomu, TUR ile remisyonda
- Ekim 2013 de gelişen sol taraf motor güçsüzlük
- biyopsi



Serebral toksoplazmozis

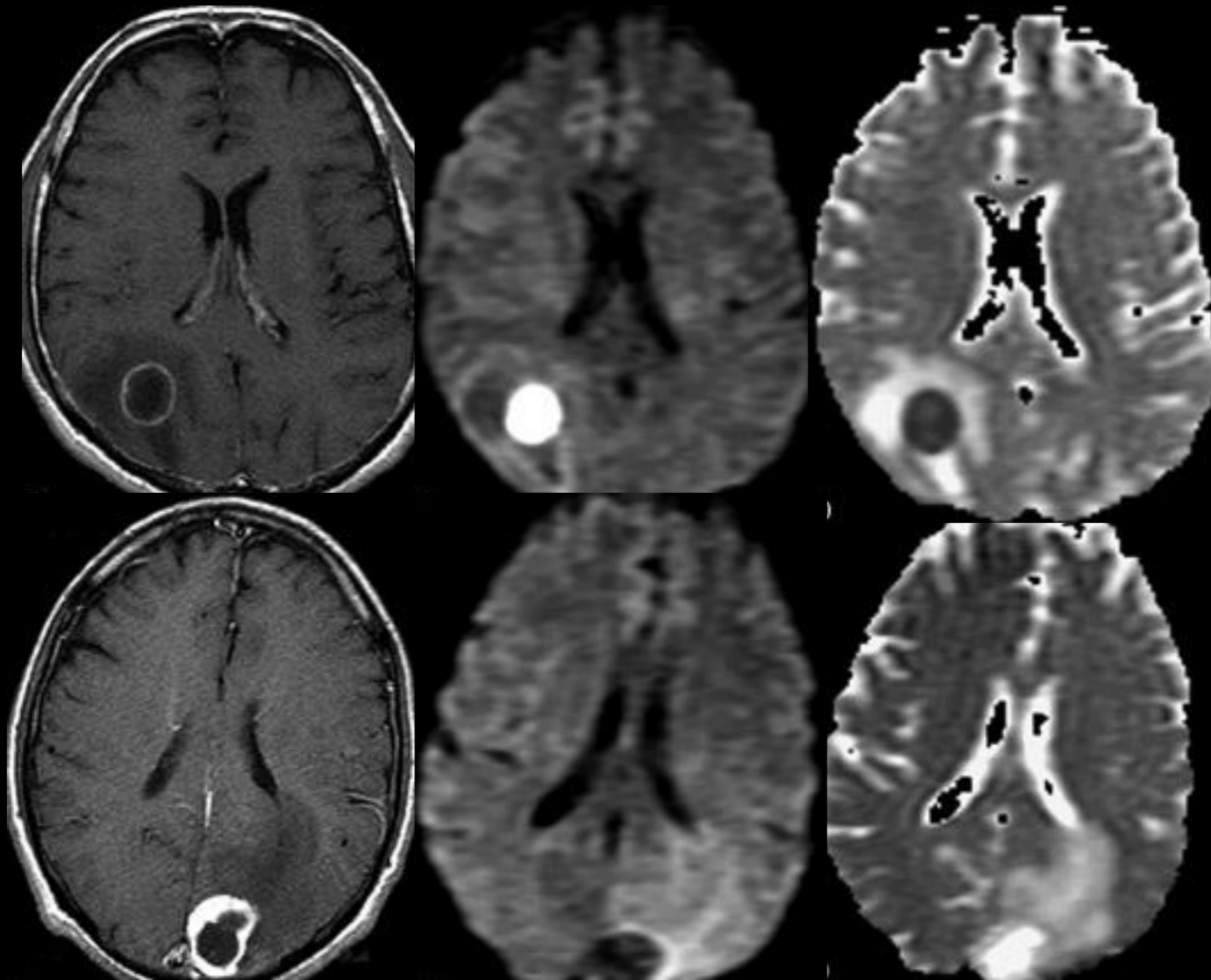


Prof.Dr.Büge Öz izni ile



20 Y E Başağrısı
ateş ve çift görme
Kriptokok

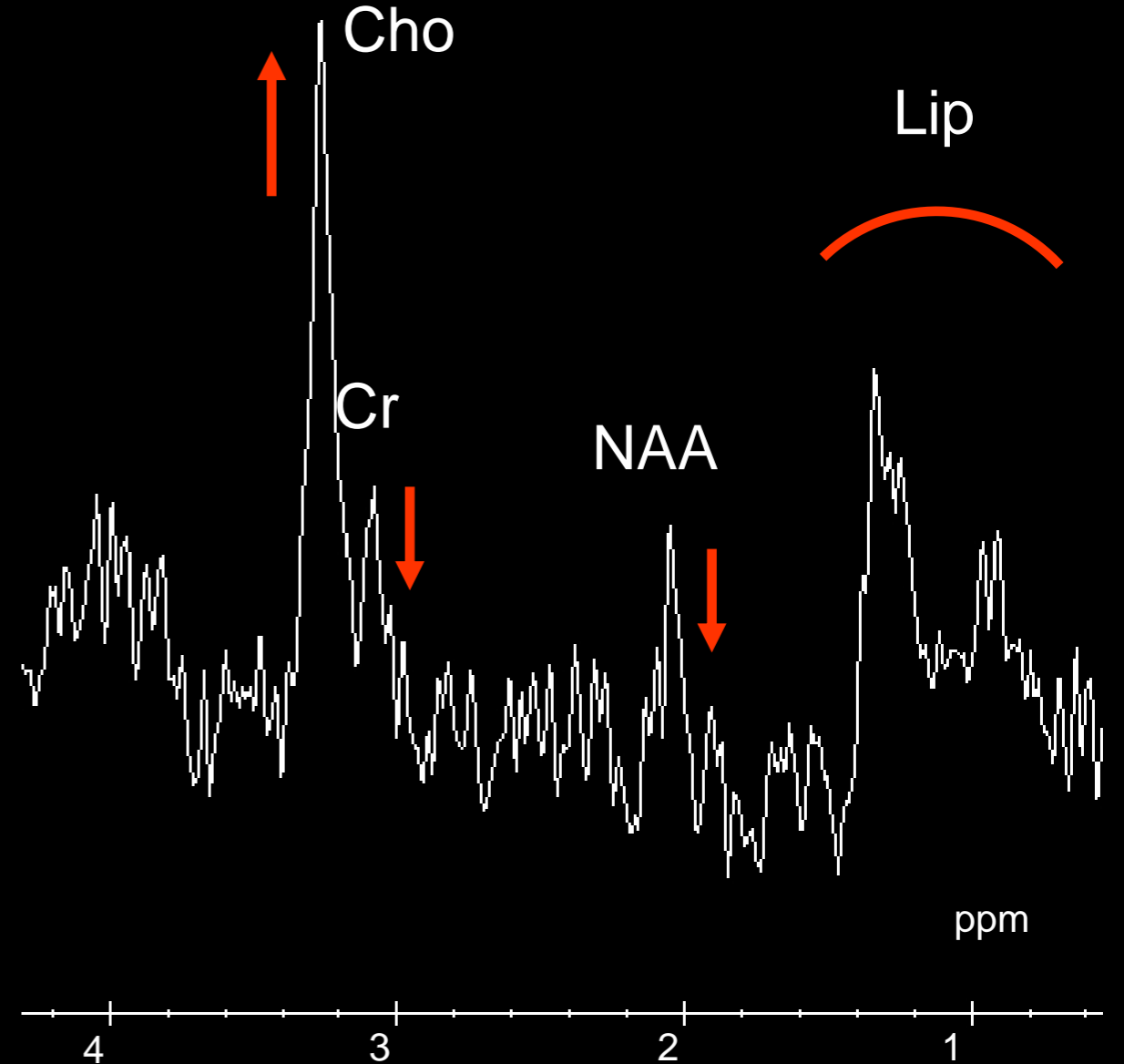
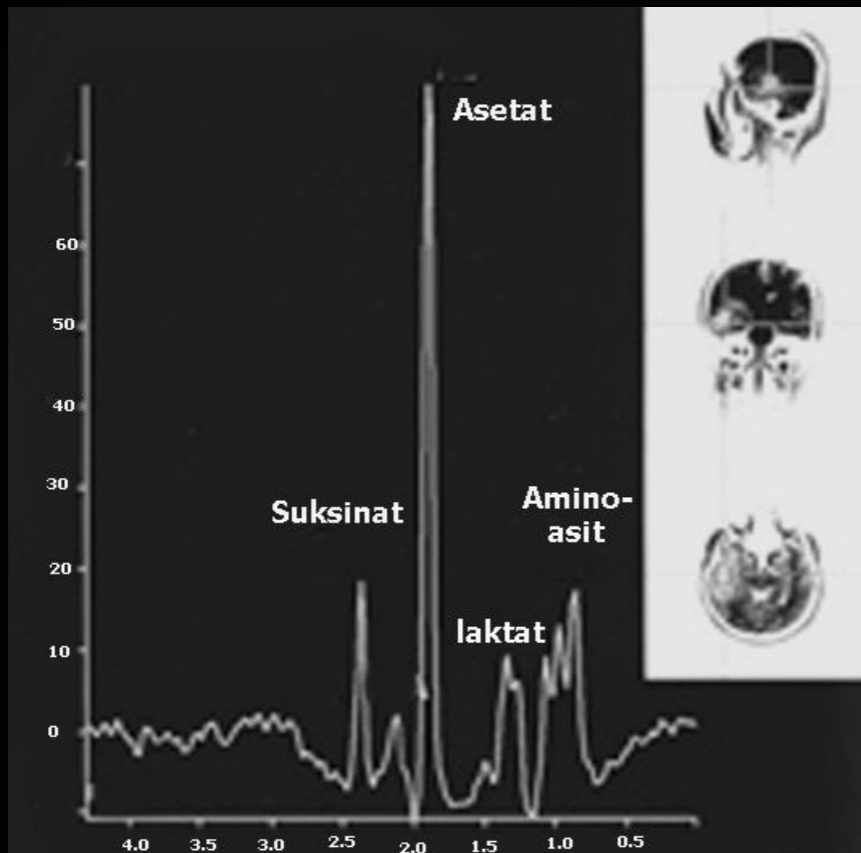
İleri görüntüleme- diffüzyon



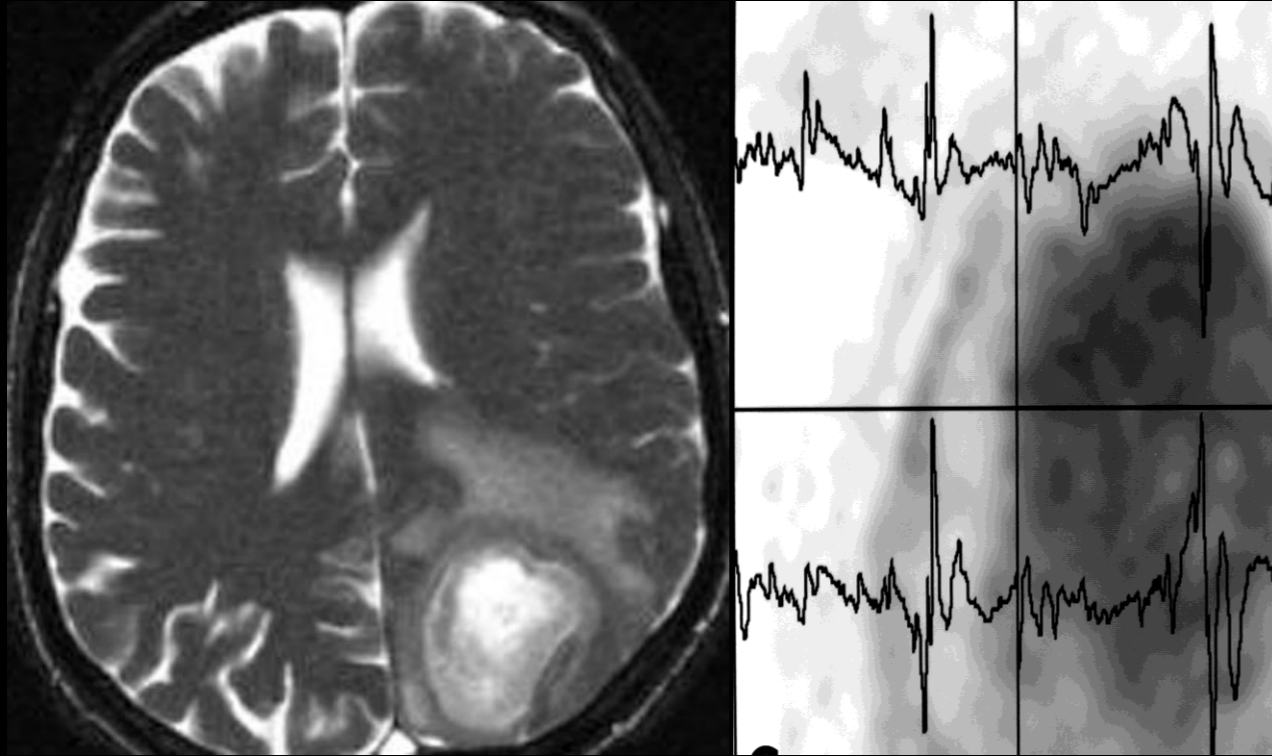
ADC ↓ = Abse

İleri görüntüleme- MRS

- NAA ↓ = nöronal kayıp
- Cho ↑ = hücresel proliferas.
- Cr ↓ = hipermetab.
- Lac = anaerobik metab.
- Lip = nekroz
- Aasitler = duvar yıkımı

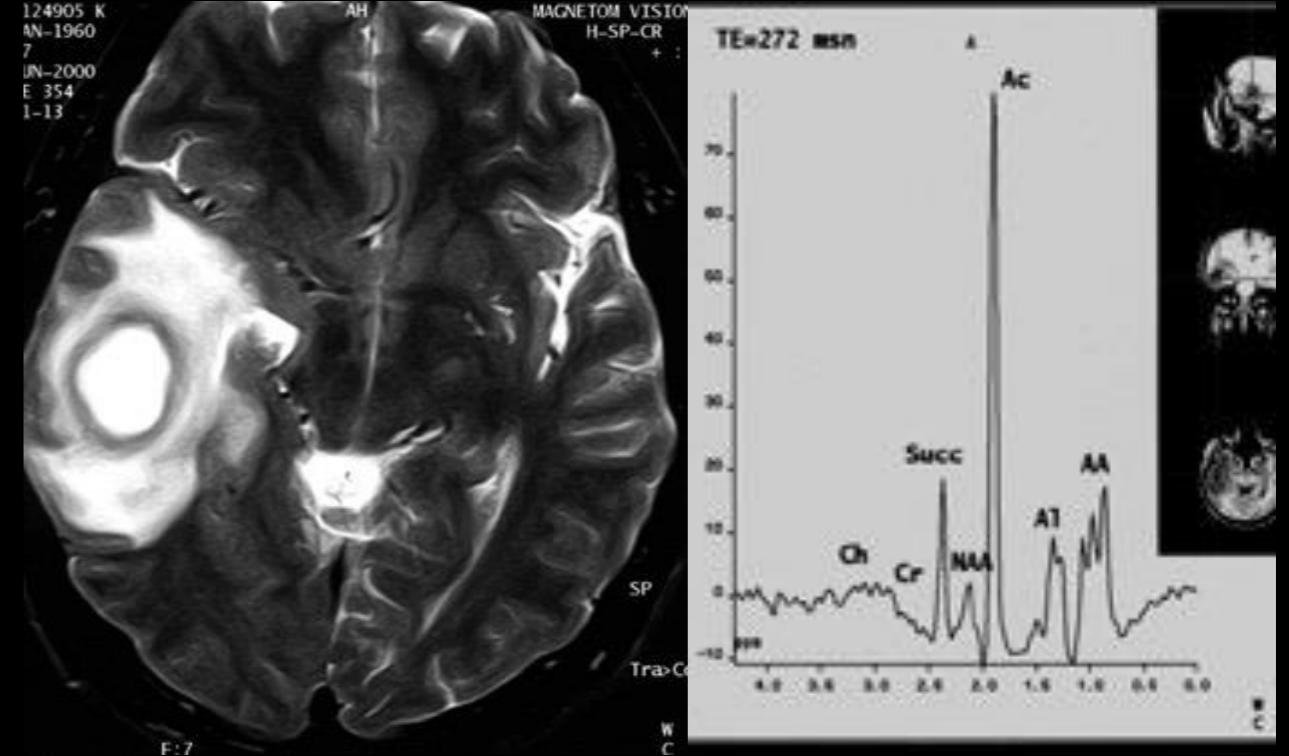


İleri görüntüleme- MRS



Tb absesi

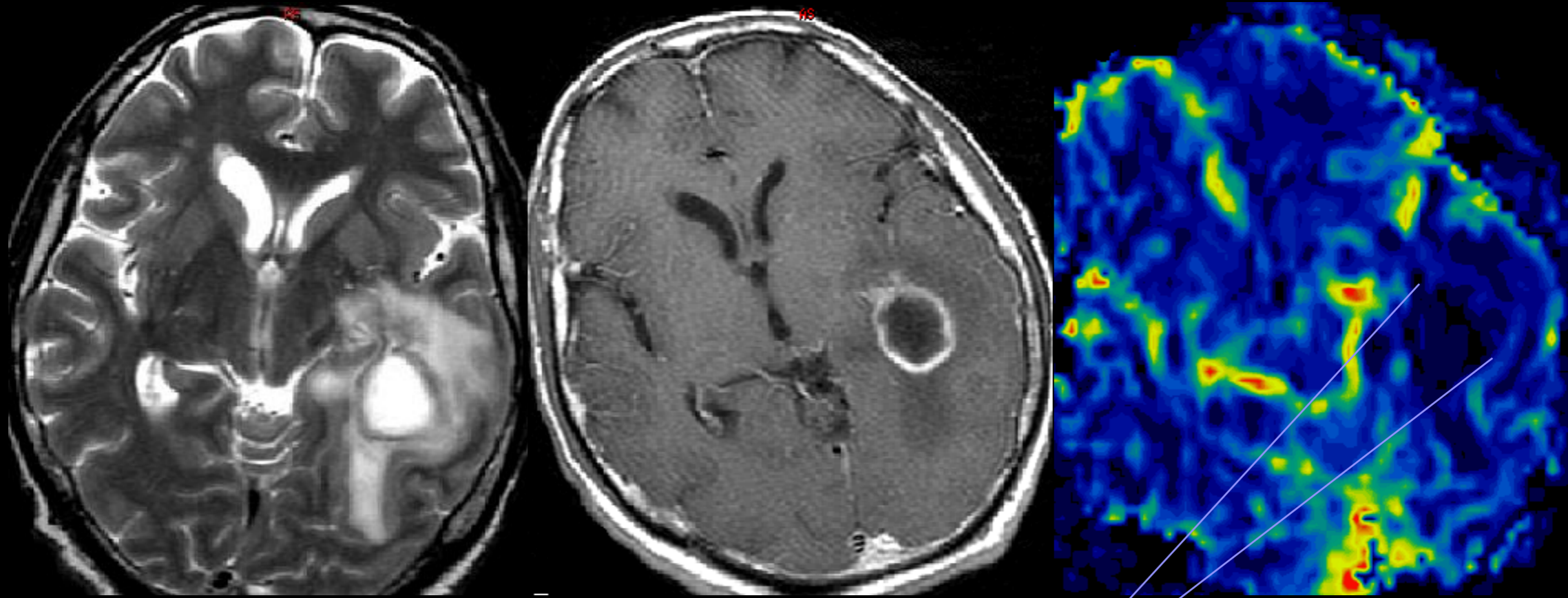
Lipid bantında artma



Bakteriyel abse

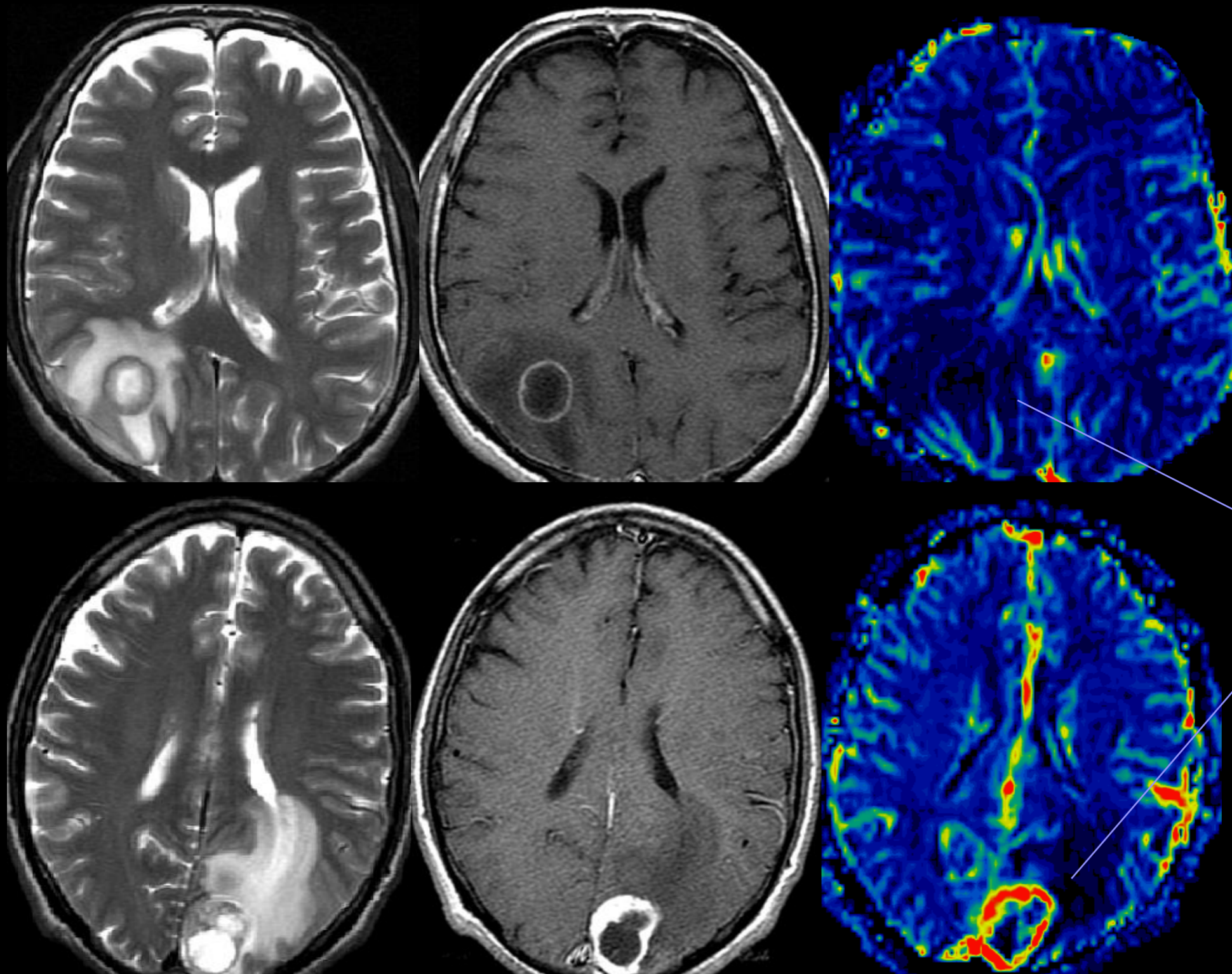
Amino asitler (valin, lösin, isolosin)

İleri görüntüleme- perfüzyon



Kapsülde CBF ve CBV ↓ : İnflamasyon

İleri görüntüleme- perfüzyon



Bakteriyel abse

Perfüzyonal
anormallik

RCC metastaz

Ayırıcı tanı

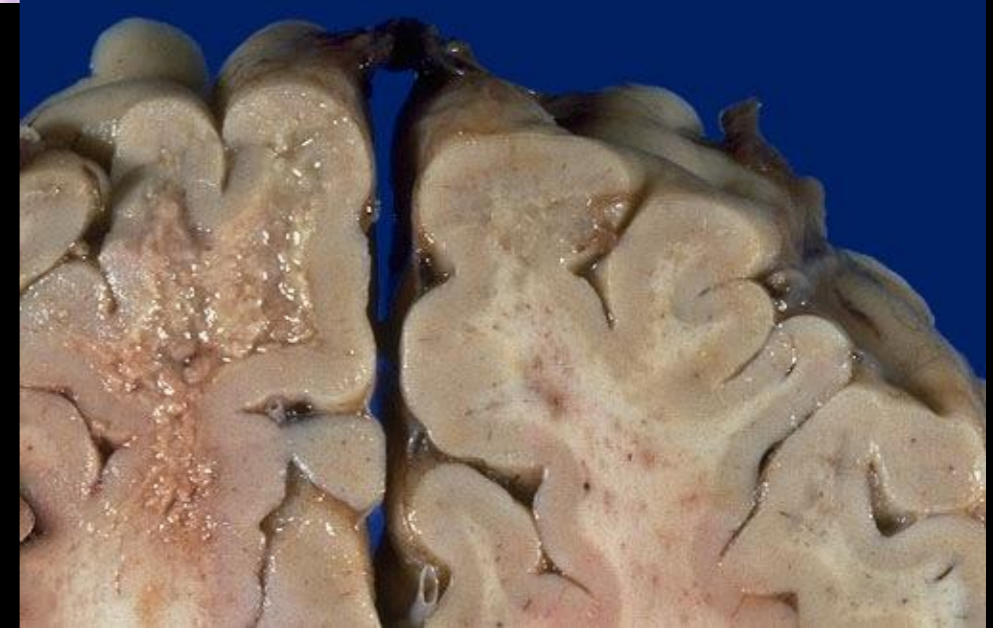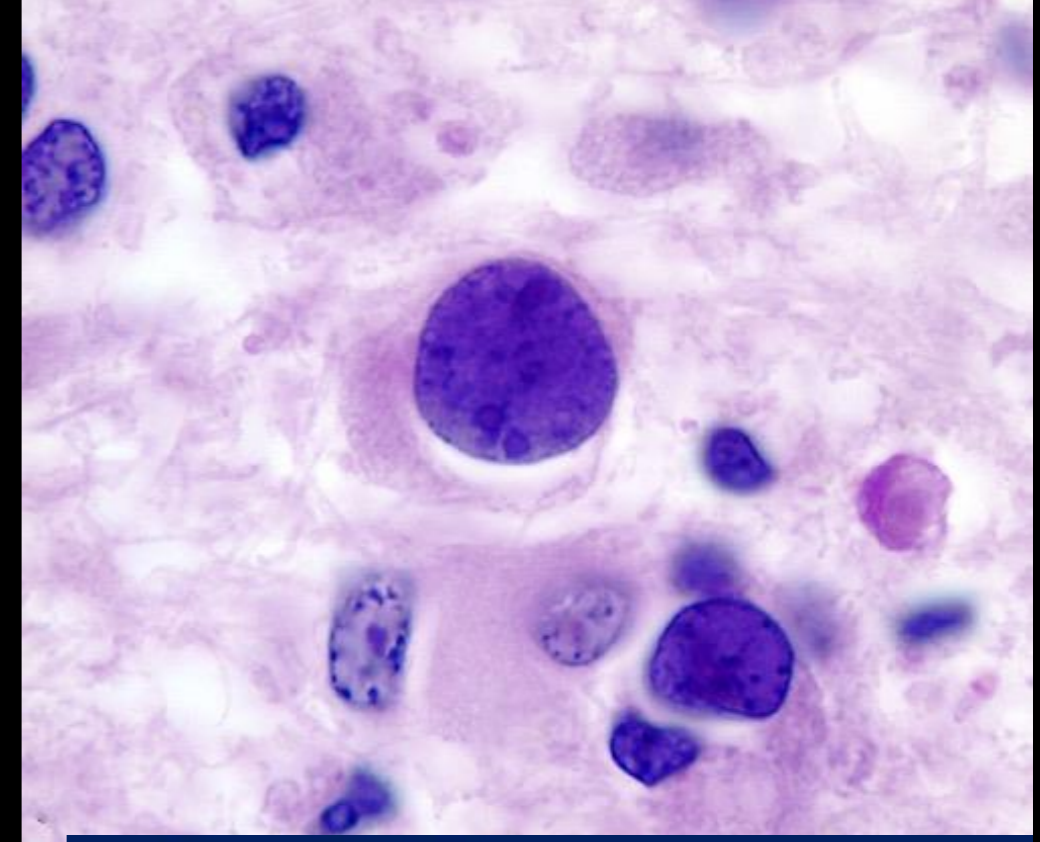
- Klinik bilgi
- Bulguların ortaya çıkışı
- İmmün yetmezlik
- Ensefalit klinik bulguları
- İleri görüntüleme
 - MRS, DWI

PML

- İmmun yetmezlikte (AIDS, transplantasyon)
- Papova virüsü (JC virüsü)
- Bilateral asimetric T2 hiperintens lezyonlar
- Kontrast (-), kitle etkisi (-)
- Korpus kallosumu geçince tümörü taklit edebilir
- Boyutu artınca santralinde nekroz olabilir

PML (JC polyomavirus)

- HIV, Transplantasyon, İmmün baskılı, Natalizumab kullanan hastalarda
 - Litik demiyelinasyon yapar!
 - HAART ile ilişkisi sıkı değildir!
 - Kitle etkisi ya da kontrastlanma yoktur!!
 - Lezyon merkezi ve periferinde farklı DWI
-
- Kortikomedüller bileşkeden başlar.
 - Birleşerek konfluen hal alır.
 - İnfekte oligodendrosit nukleusu içinde viral partikül yükleri-intranuklear cisimler



REVIEW ARTICLE

A.K. Bag
J.K. Curé
P.R. Chapman
G.H. Roberson
R. Shah



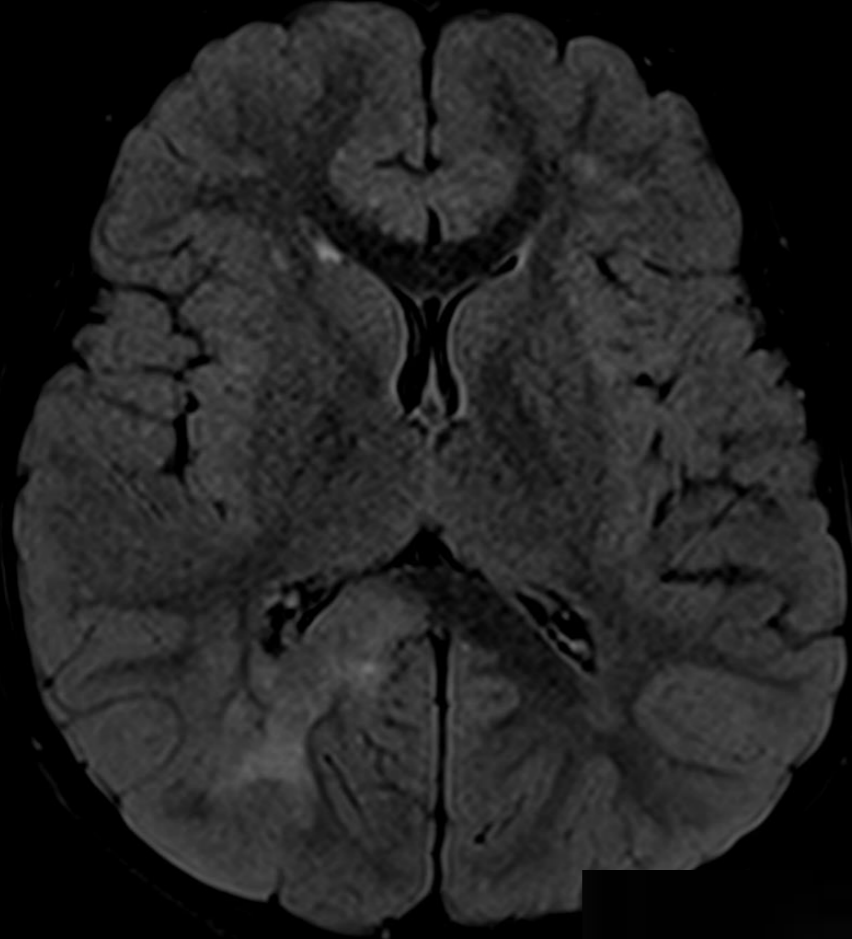
JC Virus Infection of the Brain

SUMMARY: Since its initial description, there have been significant changes in the epidemiology, pathogenesis, and clinical and imaging manifestations of JCV infection of brain. The most common clinical manifestation is PML. Other recently described CNS manifestations are JCE, JCVGCN, and JCM. Although AIDS is the most common predisposing factor for JCV reactivation, there is increasing incidence of brain manifestations of JCV reactivation in non-HIV settings, including different rheumatologic, hematologic, and oncologic conditions; monoclonal antibody therapy; transplant recipients; primary immunodeficiency syndromes; and even in patients without any recognizable immune deficiency. IRIS may develop secondary to restoration of immunity in HIV-positive patients with PML receiving antiretroviral therapy. This is of profound clinical significance and needs to be diagnosed promptly. Imaging plays a crucial role in the diagnosis of the disease, monitoring of treatment response, identifying disease progression, and predicting prognosis. In this article, current understanding of the epidemiology, pathogenesis, clinical presentations, and all aspects of imaging of JCV infection of the brain have been comprehensively reviewed.

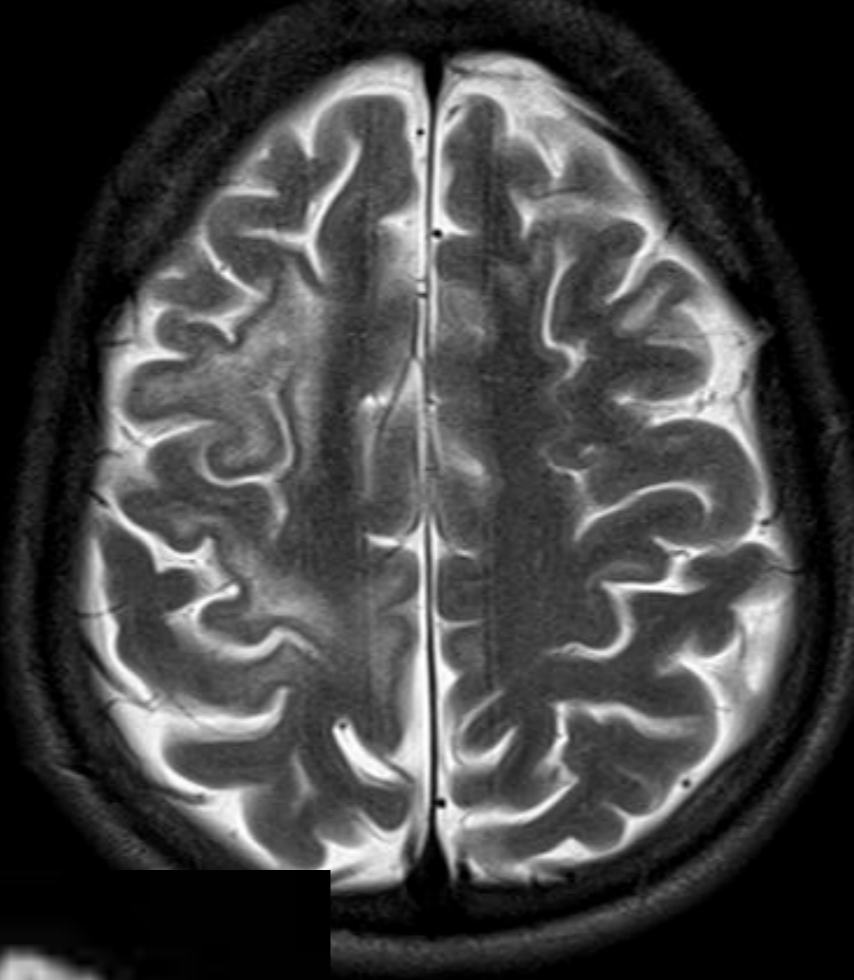PML

- JC virüs oligodendrositlere tropizm gösterir
- Bu nedenle beyinde herhangi bir bölge etkilenebilir
- Asimetrik, multifokal, supratentoriyel lobar ak madde tutulumu en sık patern
- Subkortikal ak maddede ekspansil lezyon
- En sık parietal lob tutulumu
- Spinal kord tutulumu çok nadir

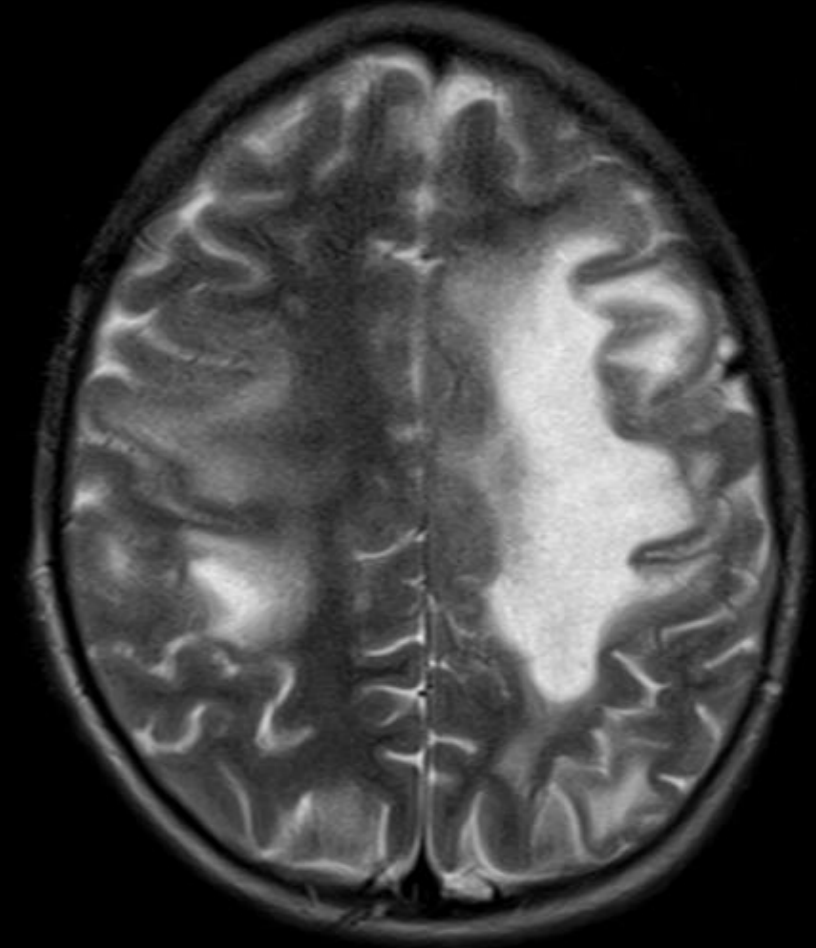
PML: SUBKORTİKAL ARKUAT TUTULUMU



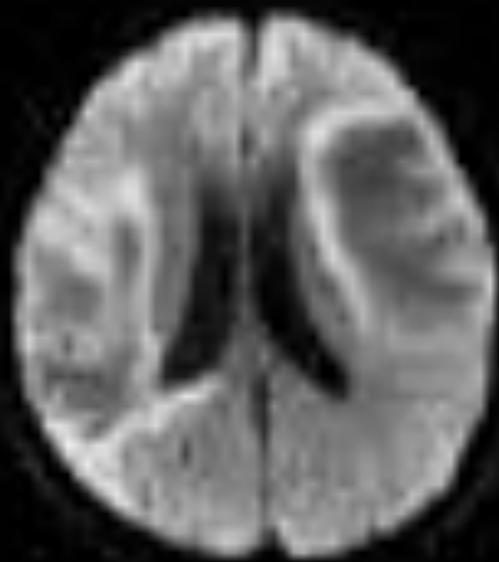HIV



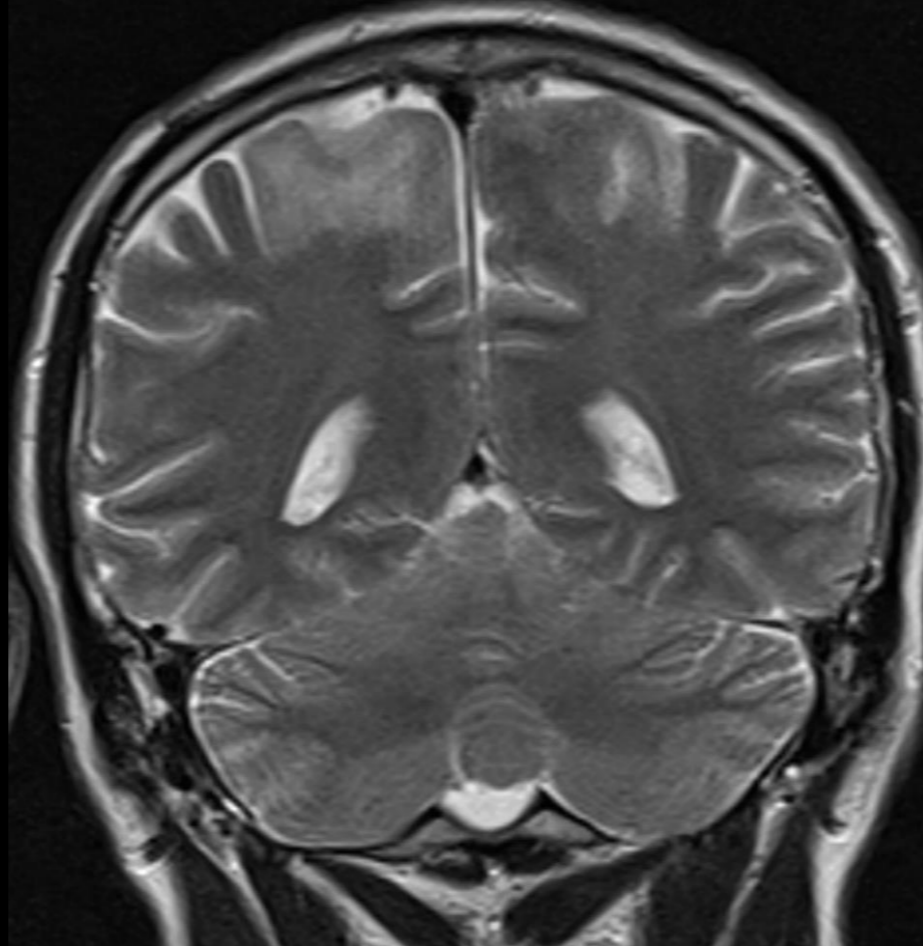
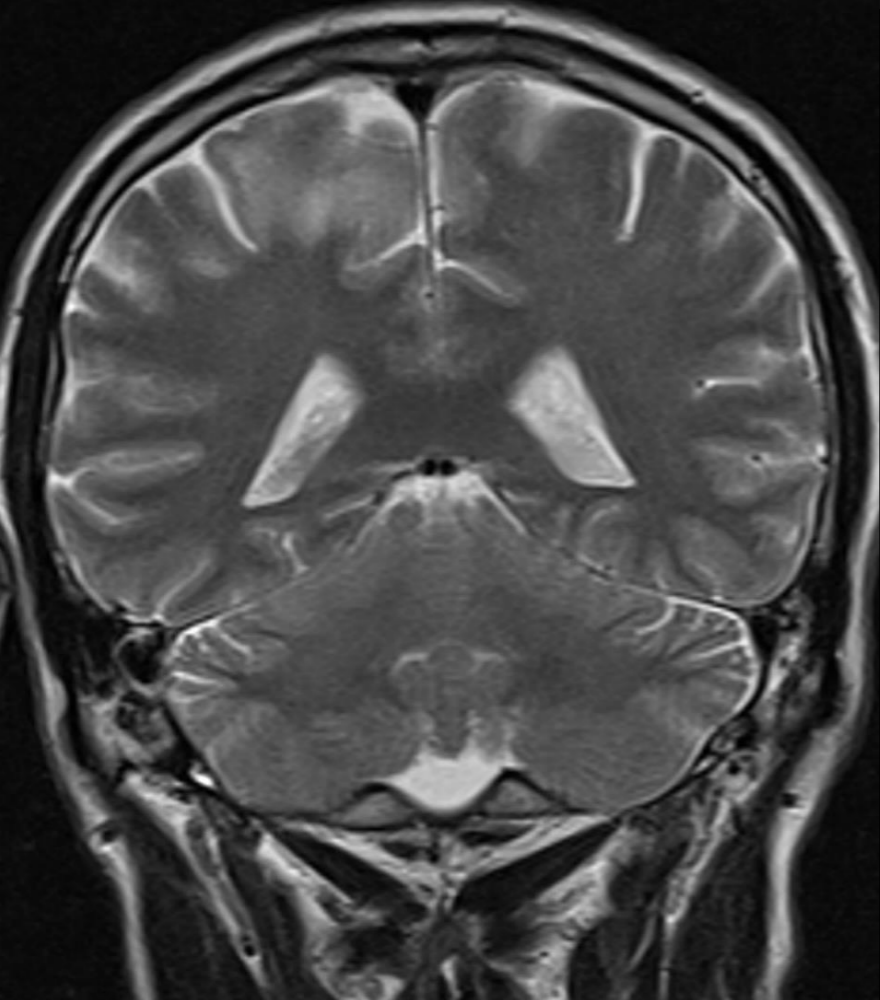
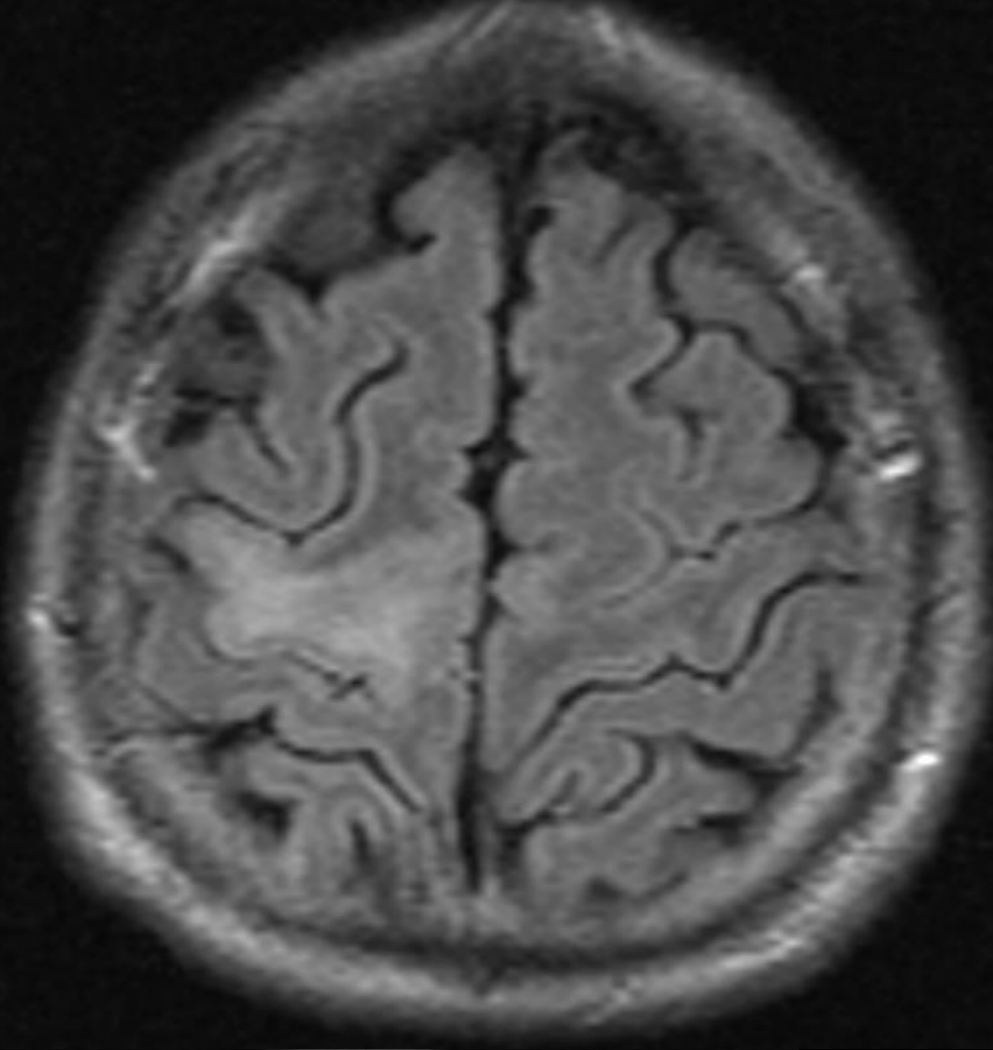
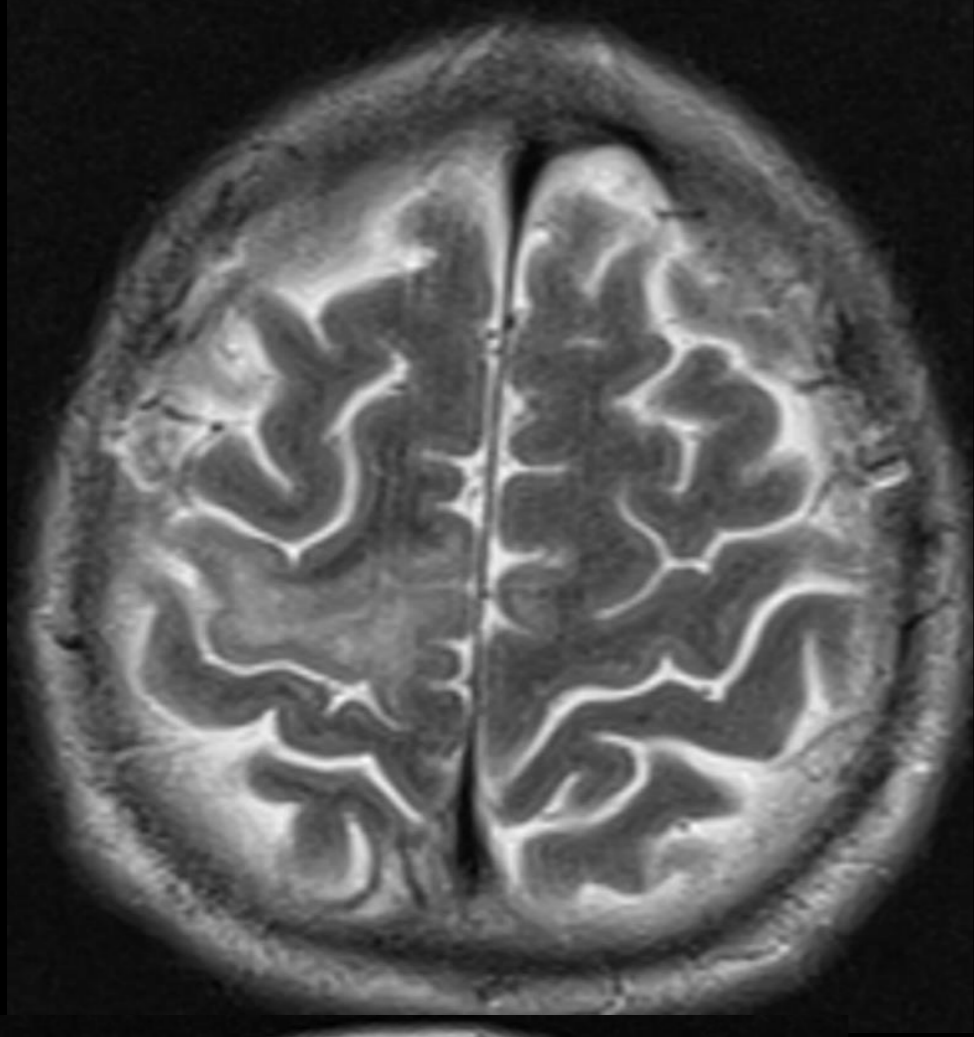
CVID

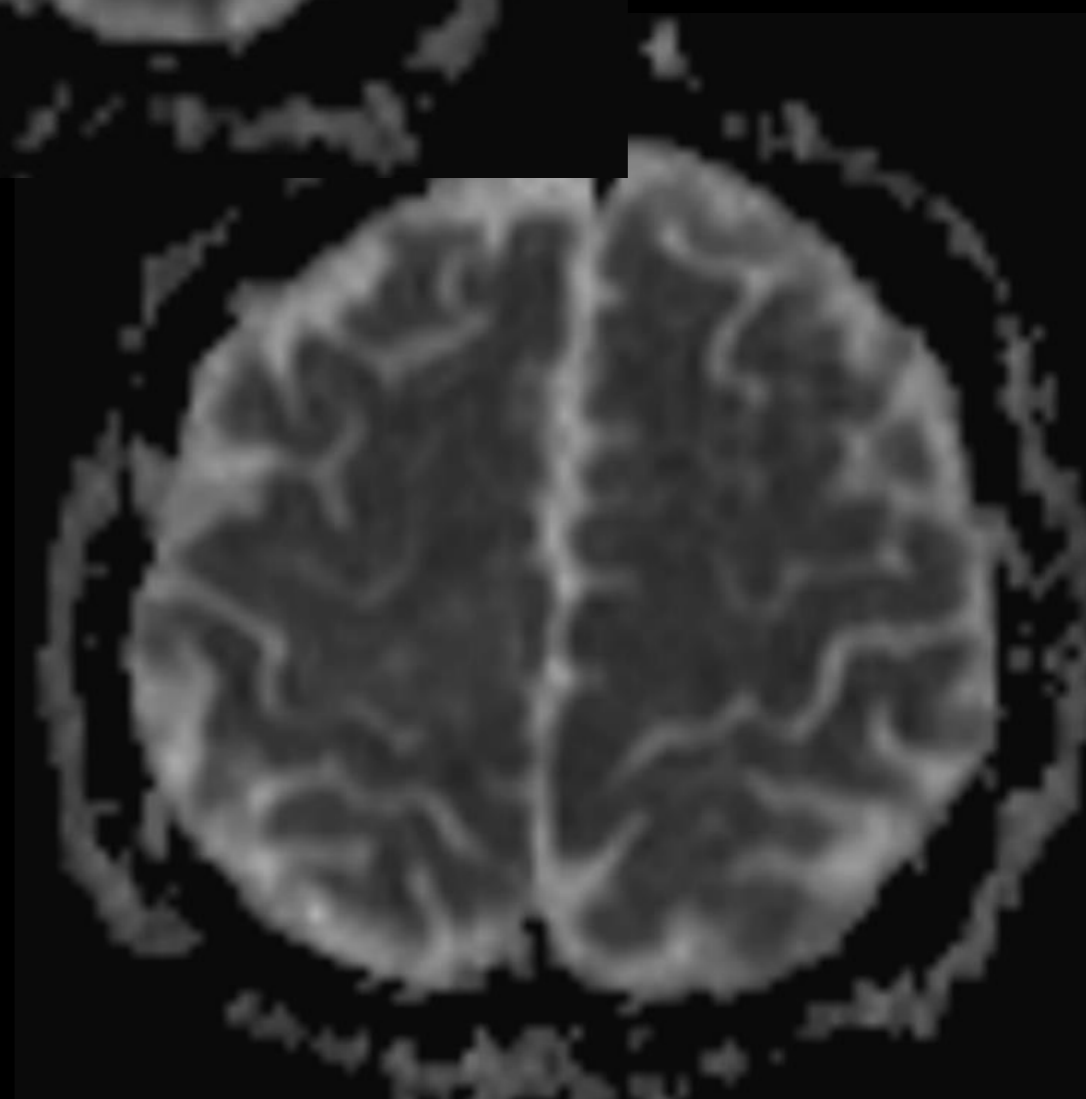
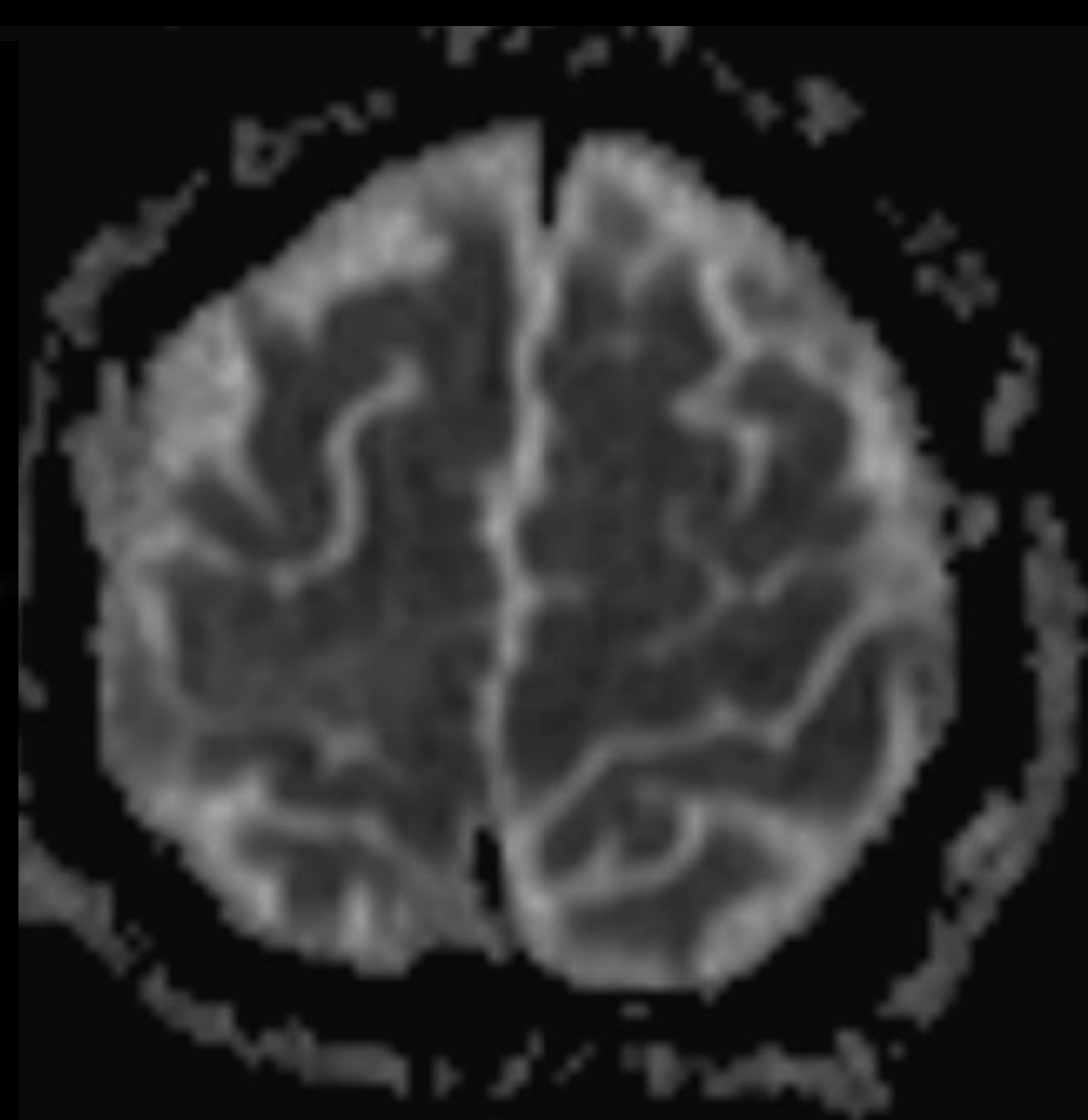
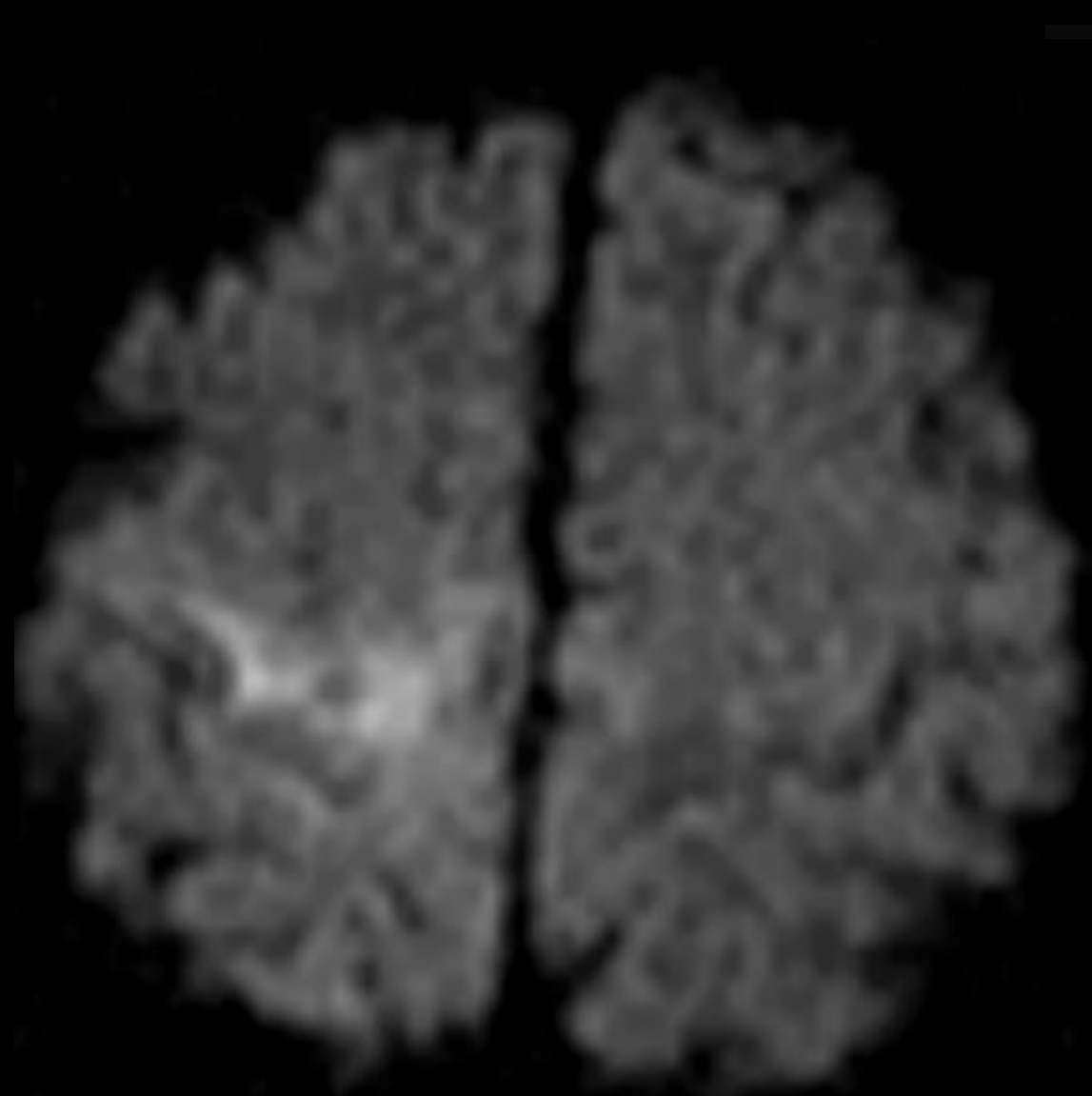


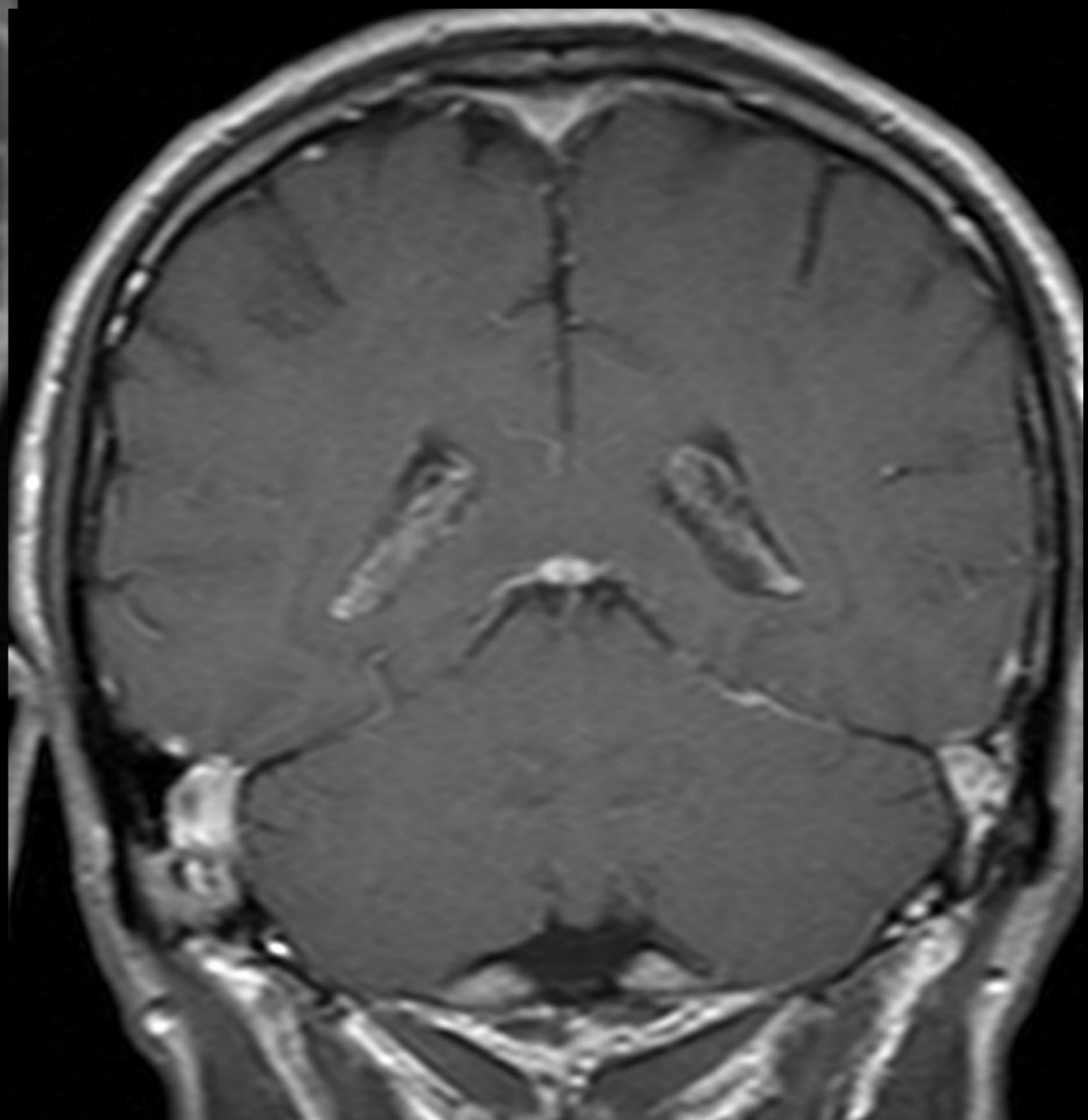
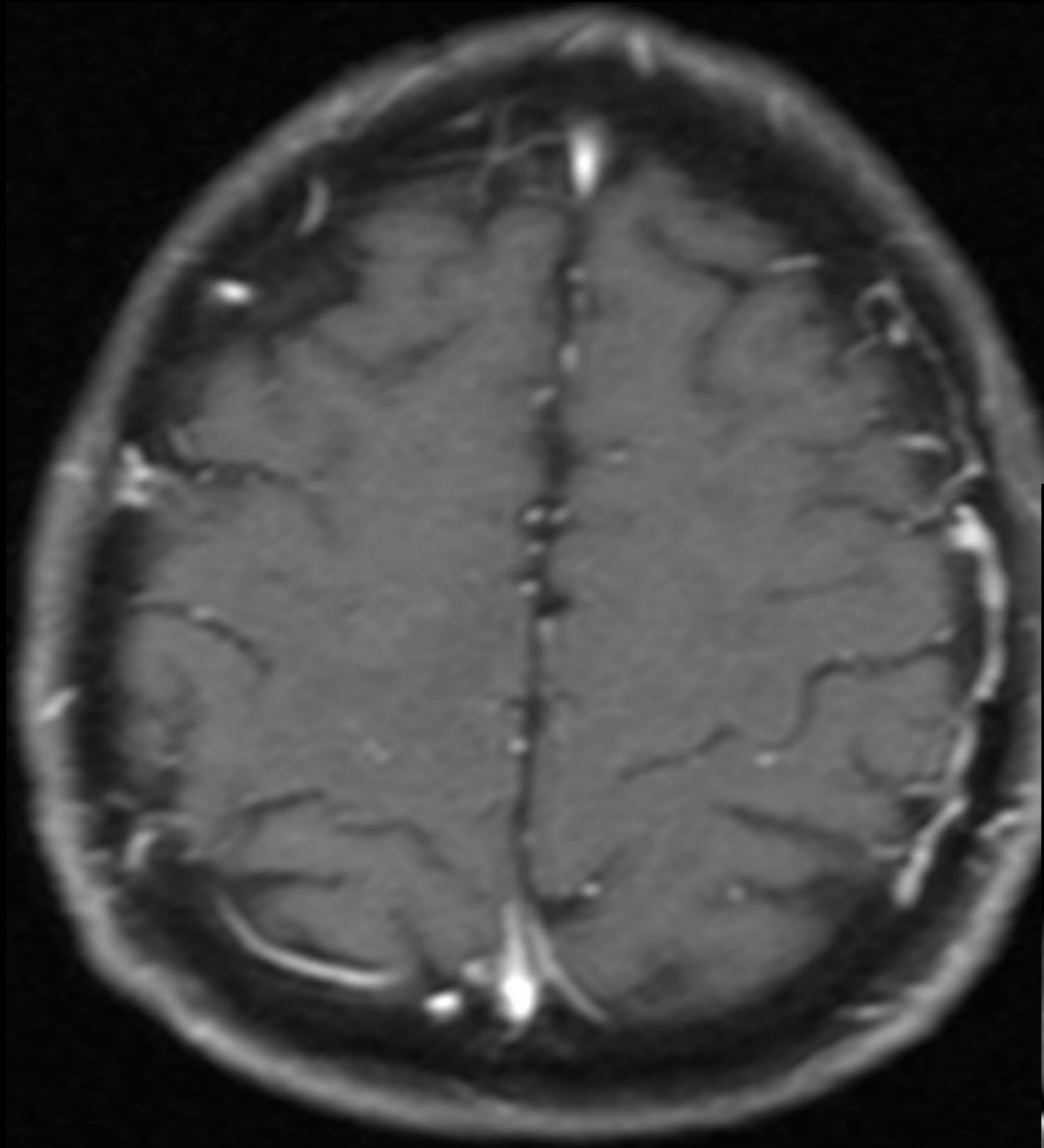
Natalizumab



Marjinal difüzyon kısıtlanması







PML A.Tanı

- HIVE - U lifleri tutulmaz
- IRIS - sık birliktelik
- Diğer fırsatçı enf.lar

IRIS

- Provokan ajana göre görüntüleme bulguları değişebilir
- Hızla artan kitle etkisi sık g
- Kontrastlanma değişken, sıklıkla düzensiz

CNS–Immune Reconstitution Inflammatory Syndrome in the Setting of HIV Infection, Part 1: Overview and Discussion of Progressive Multifocal Leukoencephalopathy–Immune Reconstitution Inflammatory Syndrome and Cryptococcal–Immune Reconstitution Inflammatory Syndrome

M.J.D. Post, M.M. Thurnher, D.B. Clifford, A. Nath, R.G. Gonzalez, R.K. Gupta, and K.K. Post

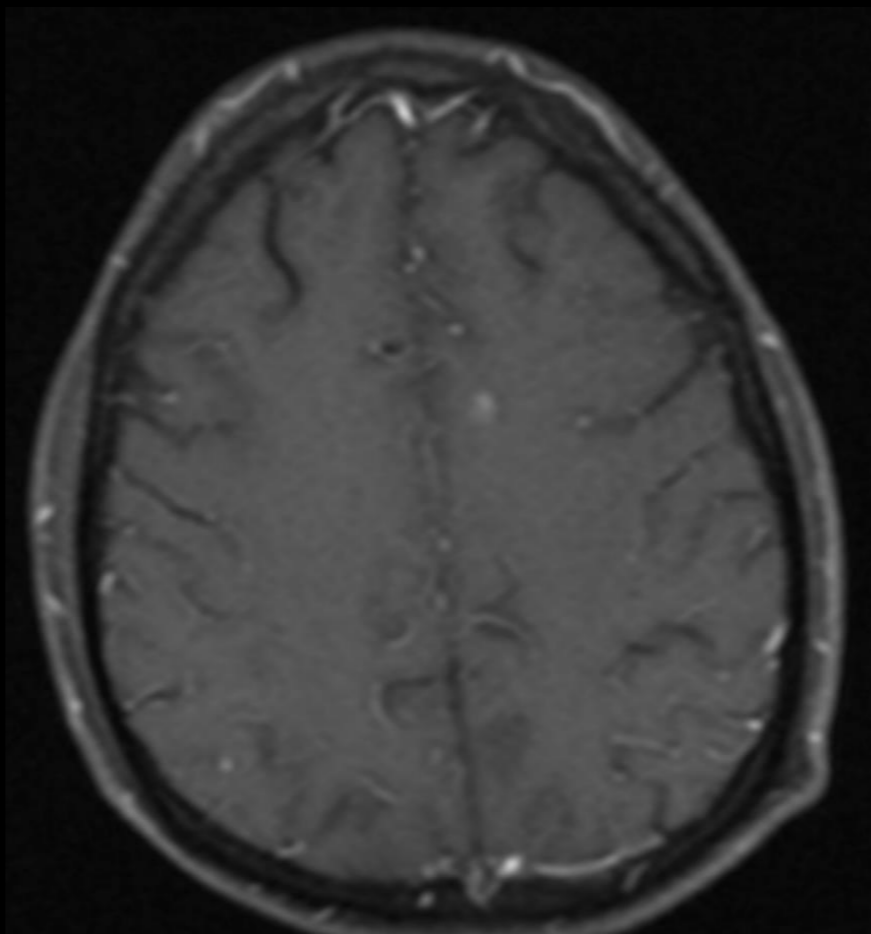
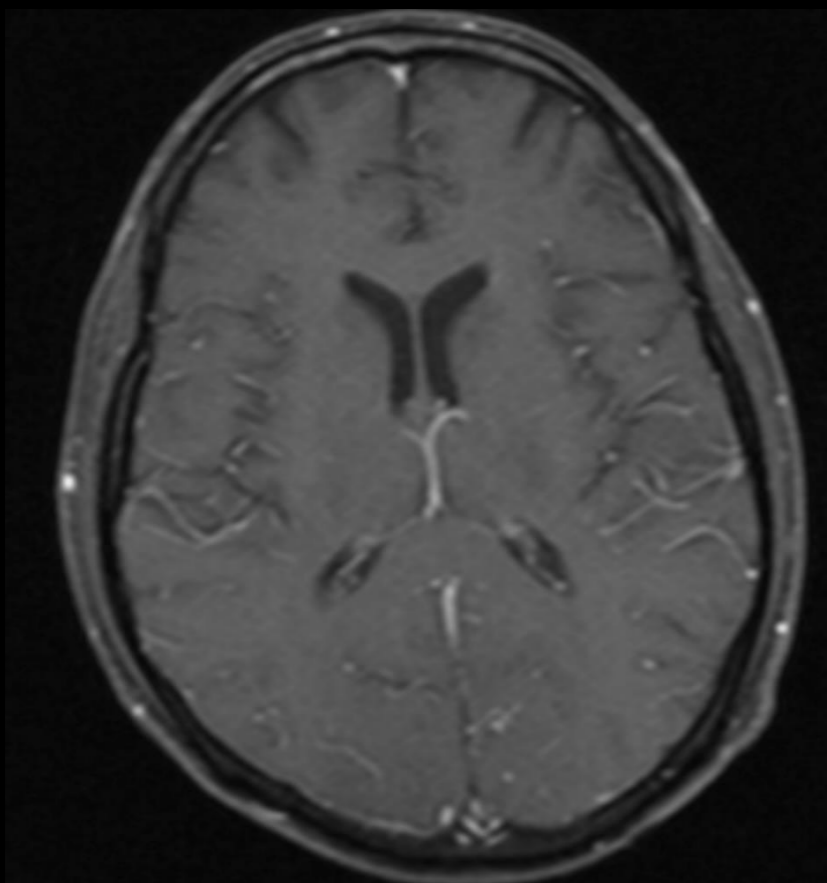
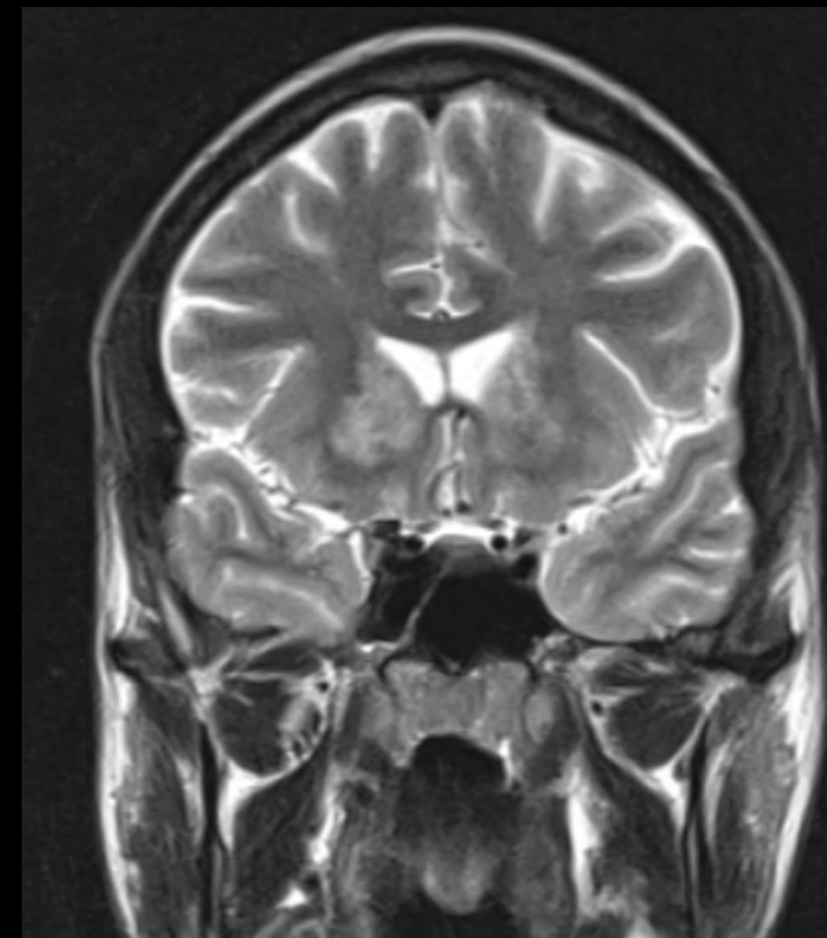
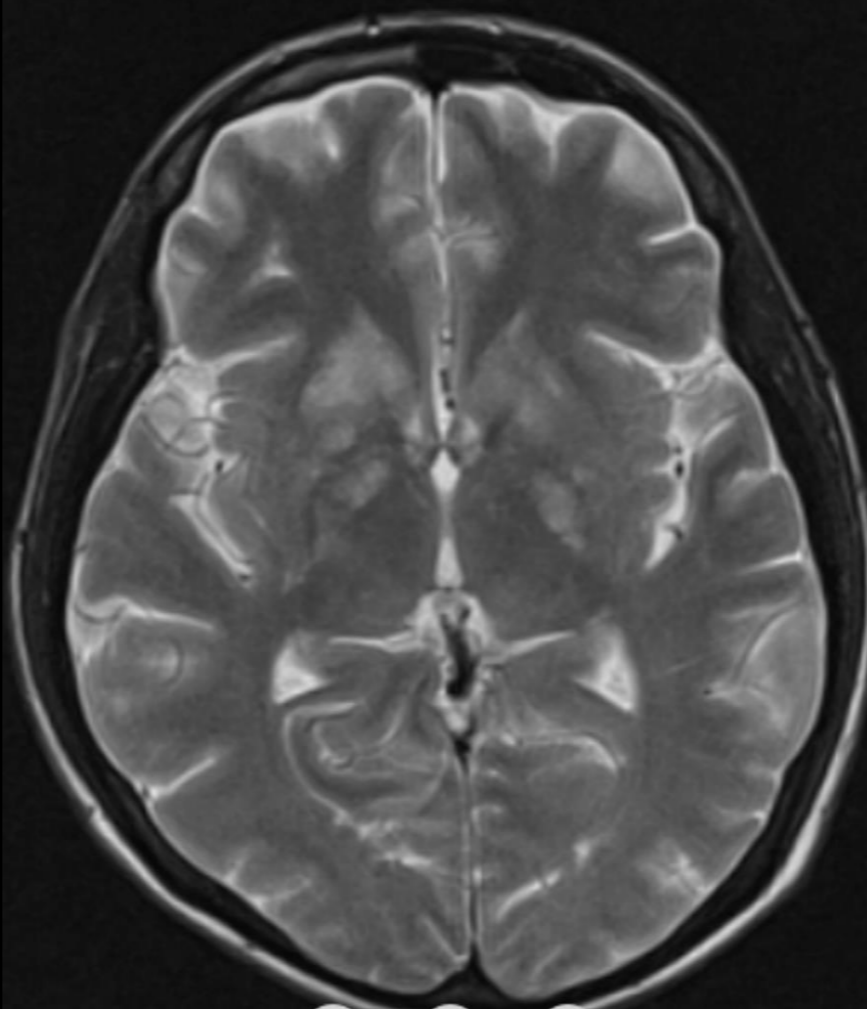
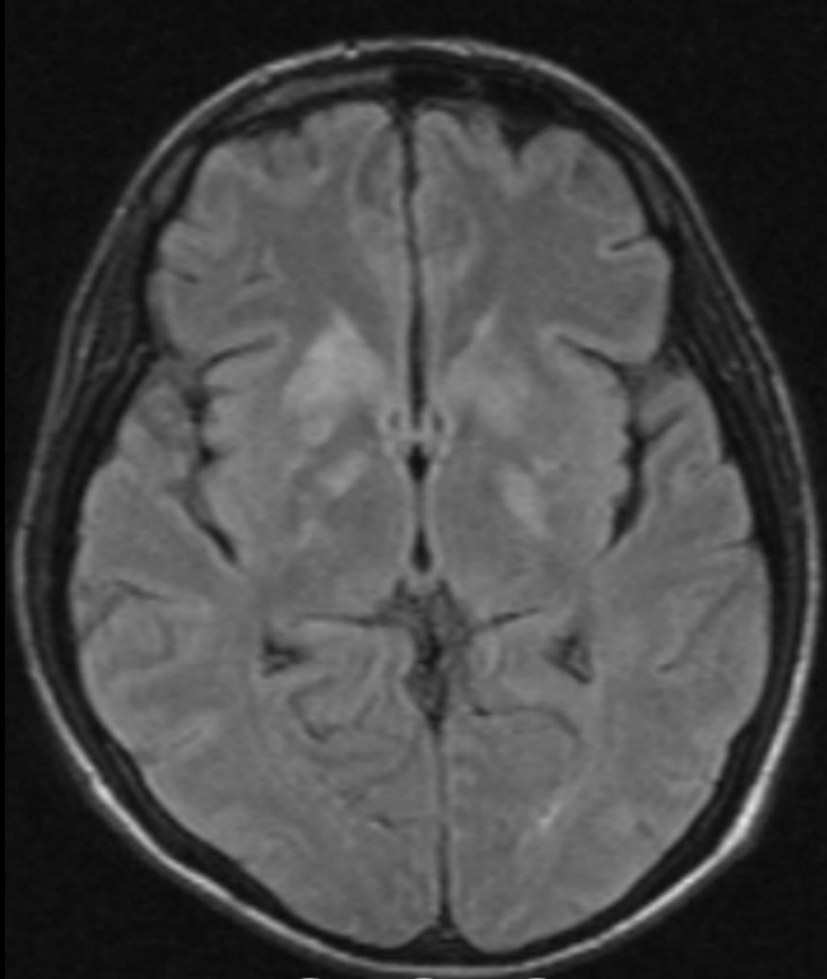
REVIEW ARTICLE

CNS–Immune Reconstitution Inflammatory Syndrome in the Setting of HIV Infection, Part 2: Discussion of Neuro–Immune Reconstitution Inflammatory Syndrome with and without Other Pathogens

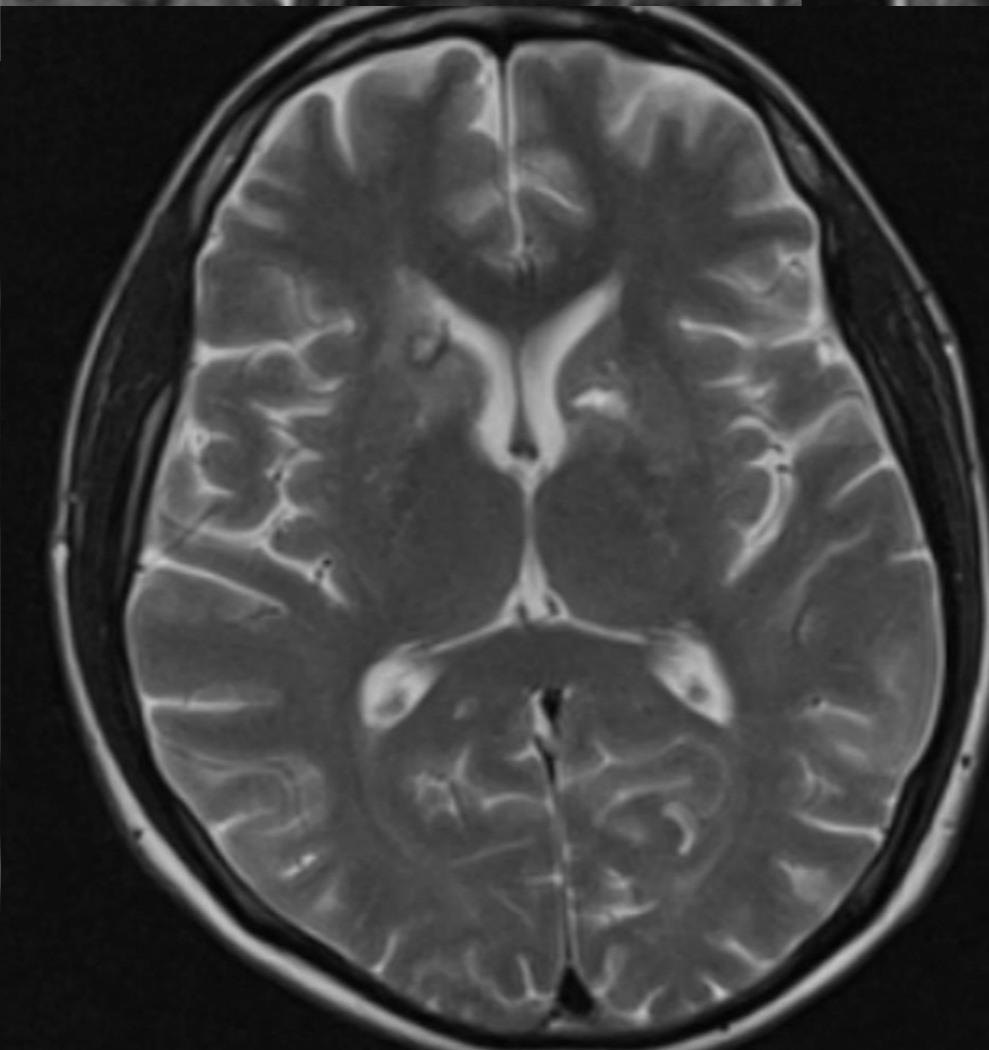
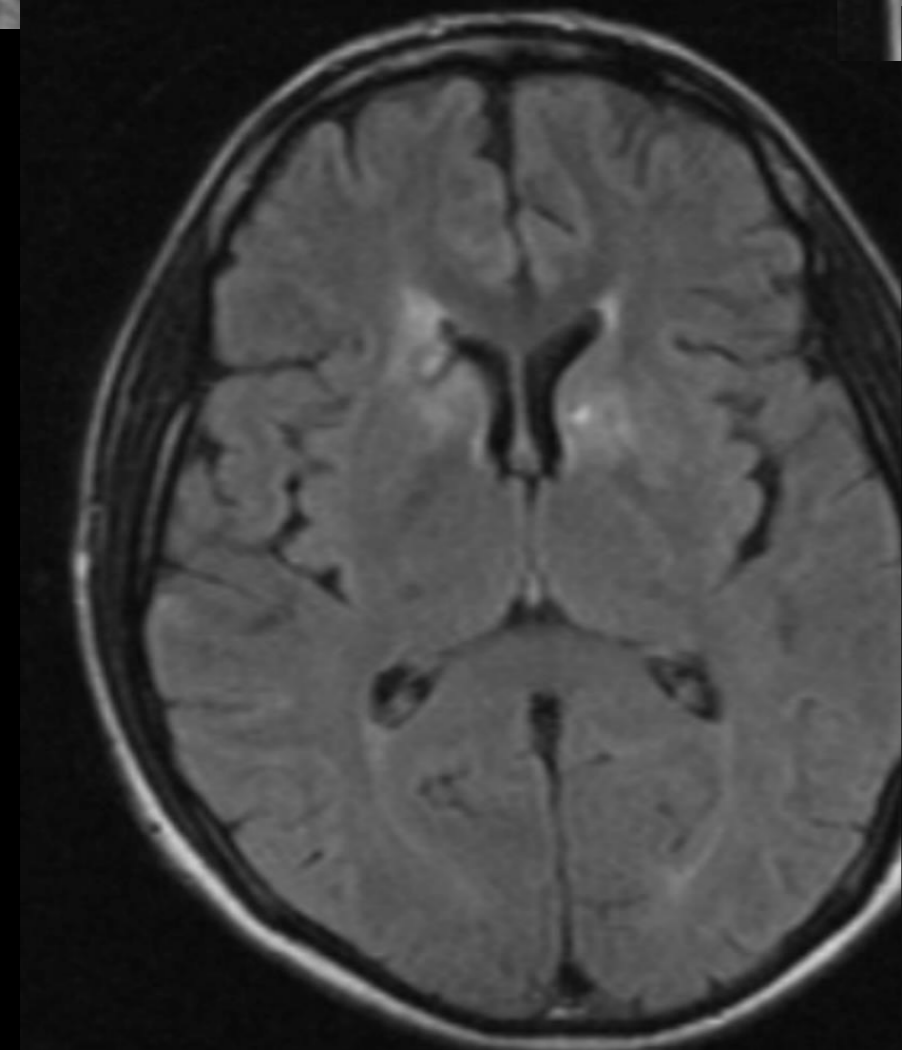
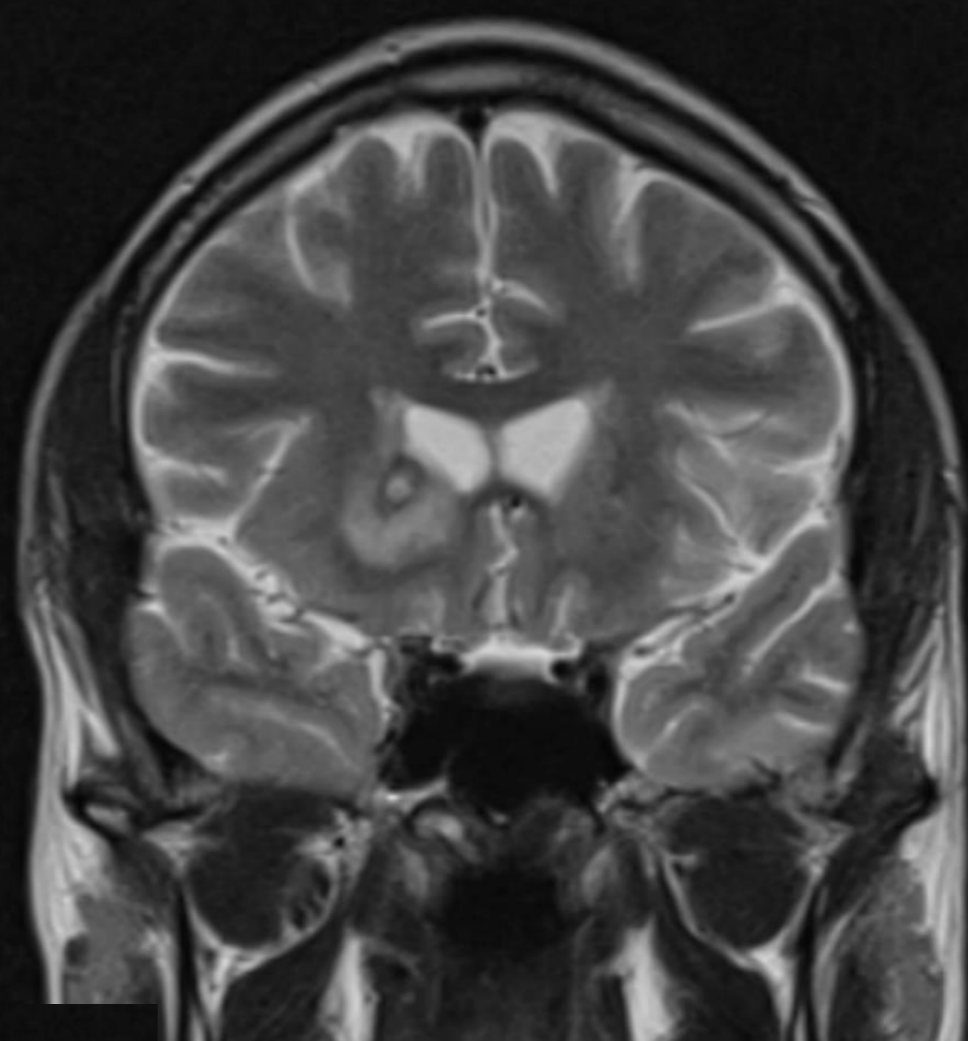
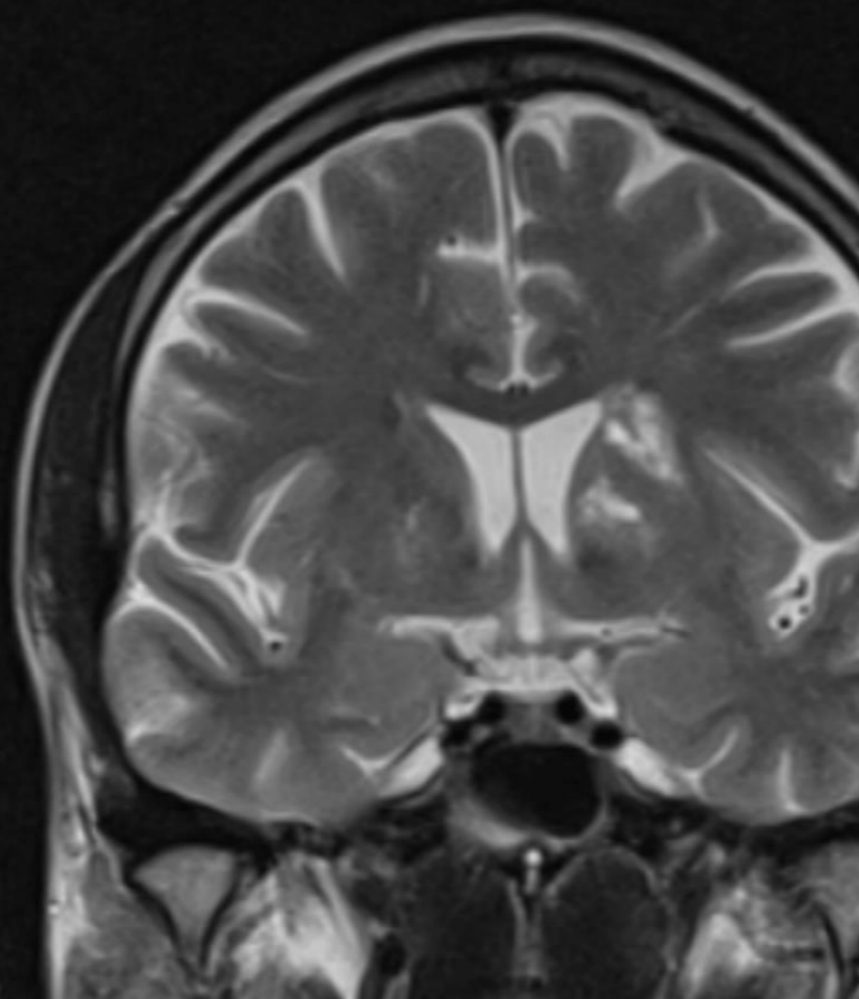
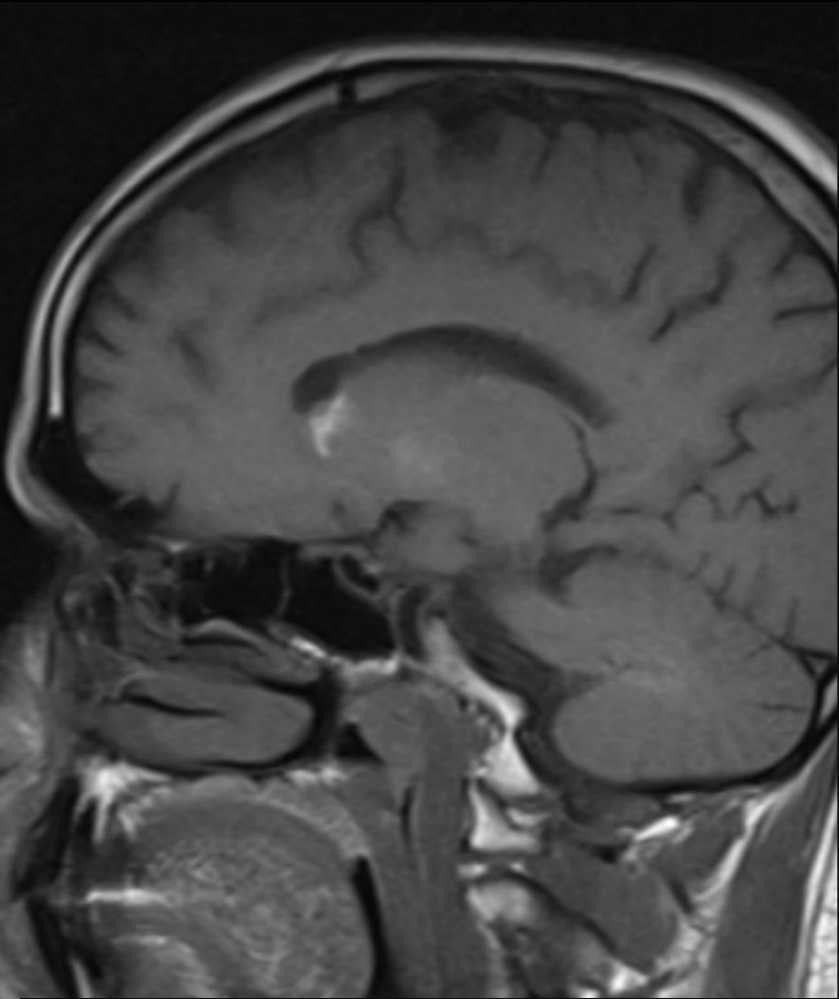
M.J.D. Post, M.M. Thurnher, D.B. Clifford, A. Nath, R.G. Gonzalez, R.K. Gupta, and K.K. Post

IRIS-NIRIS Tanı Kriterleri

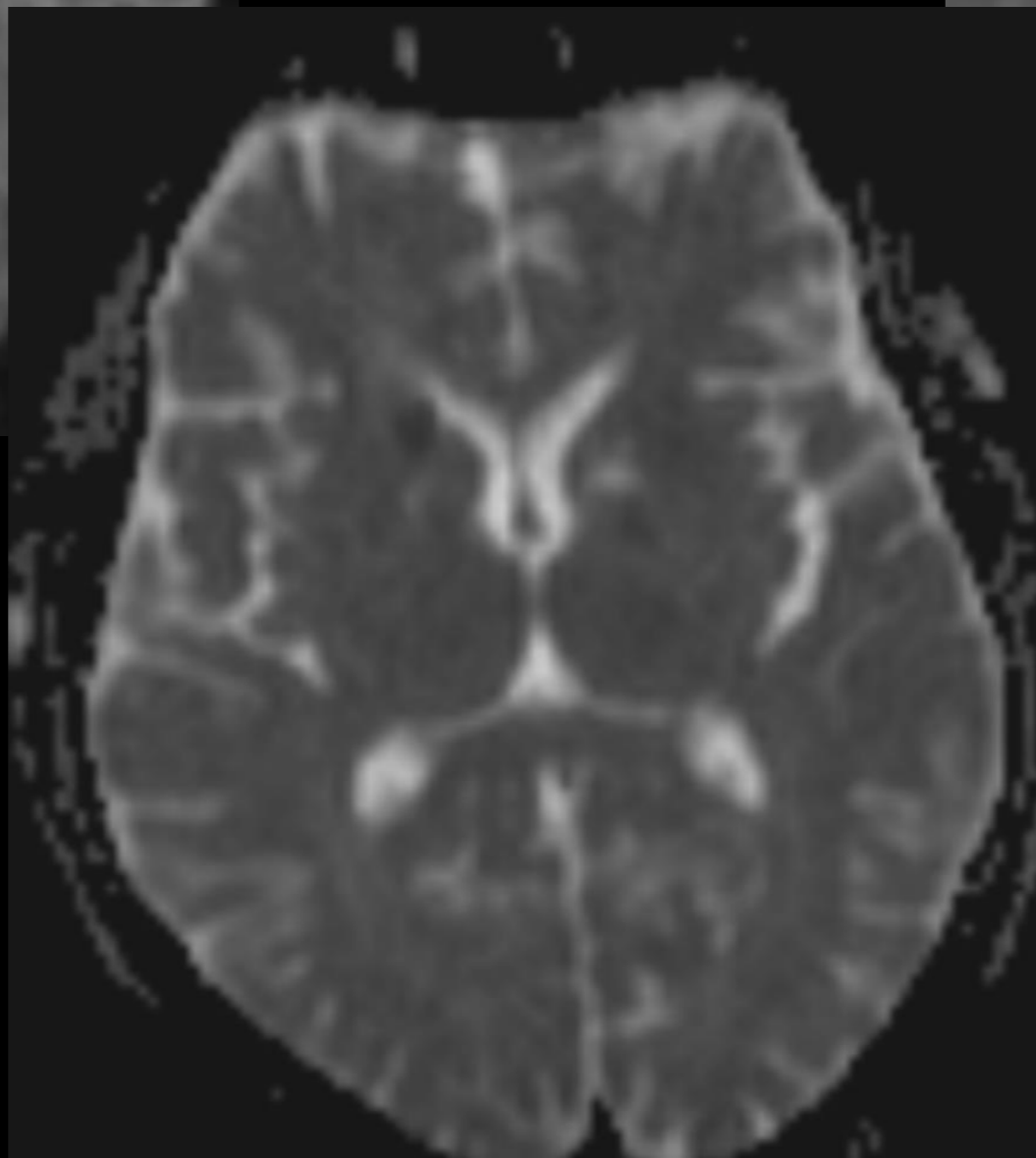
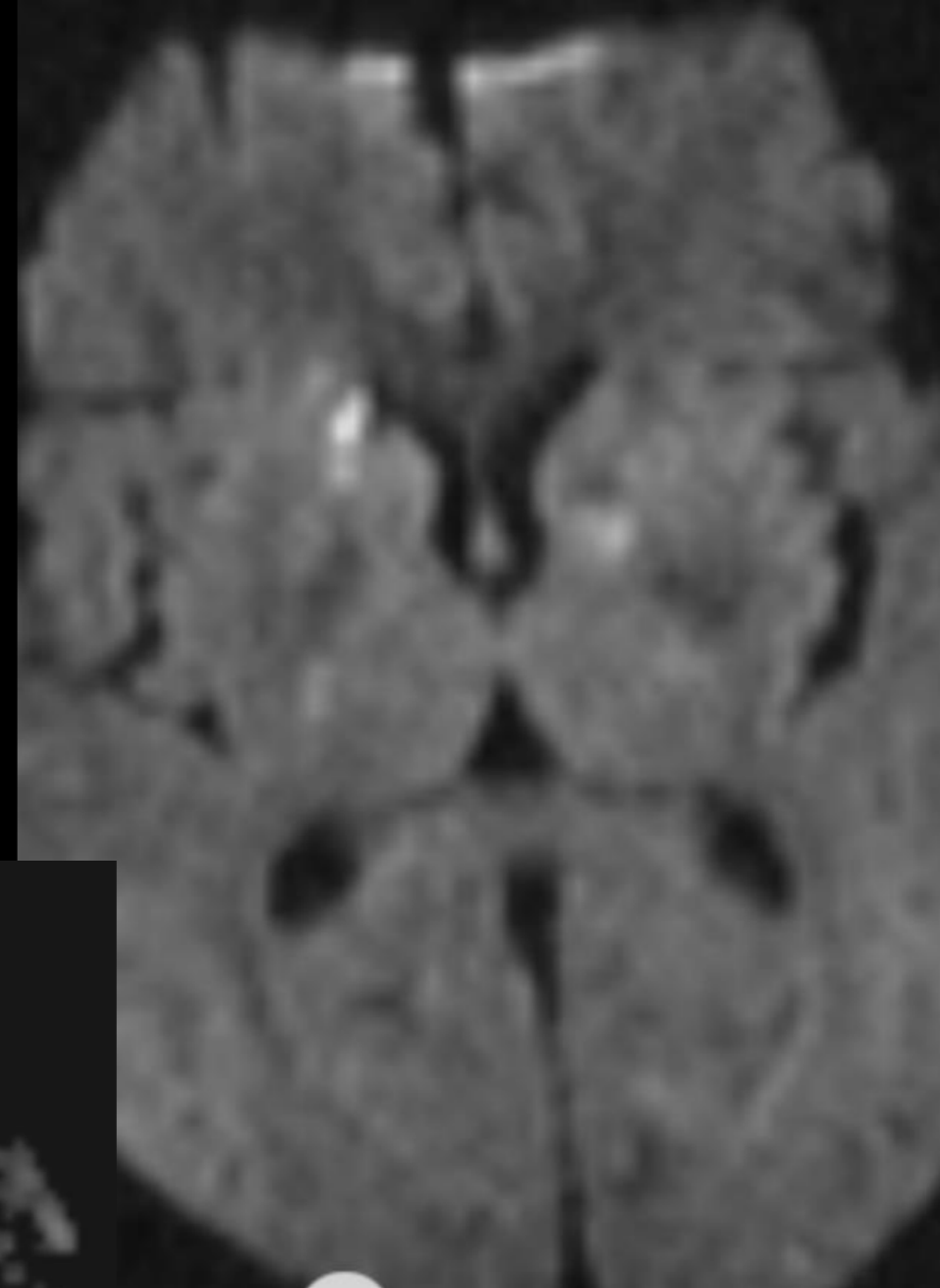
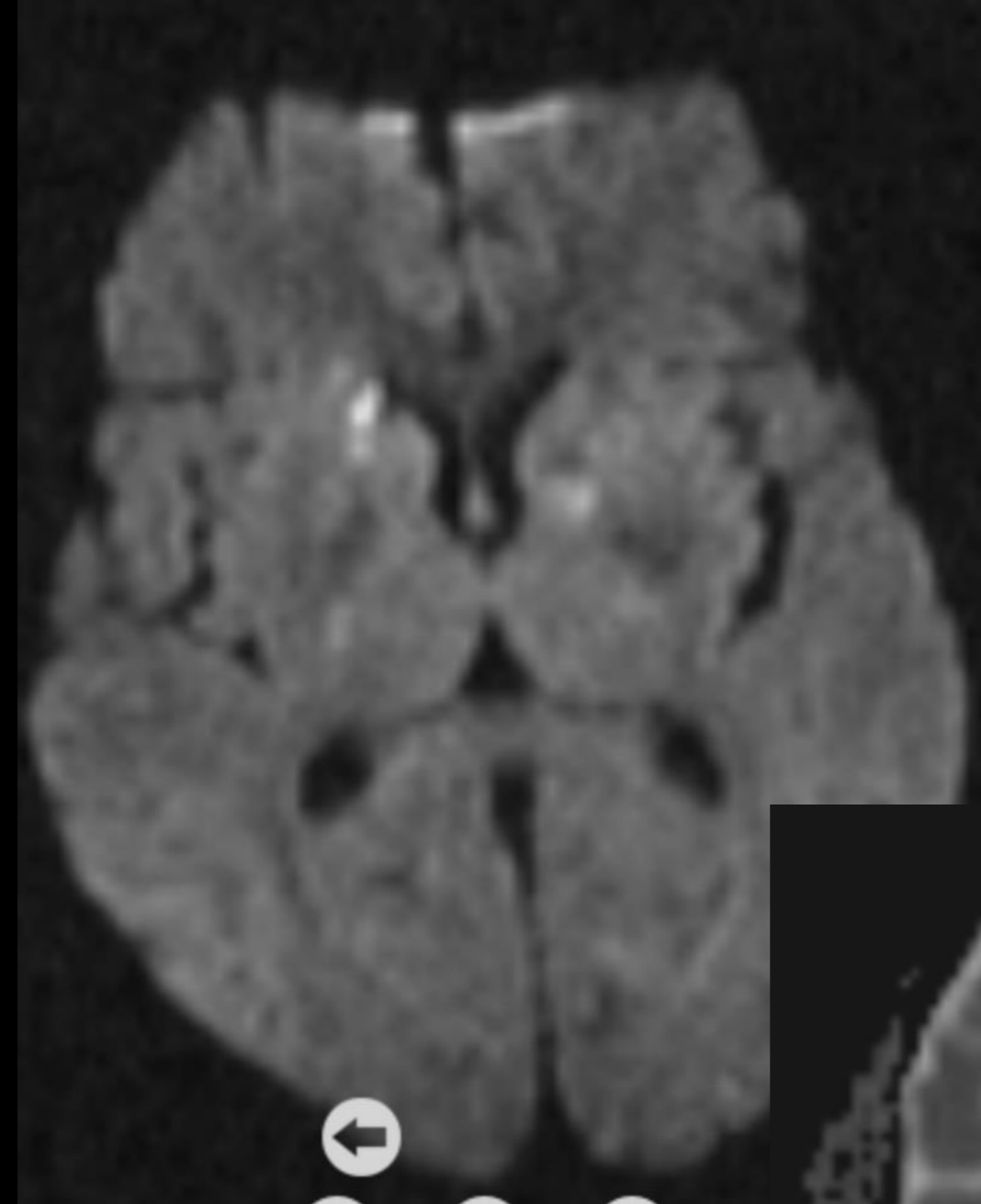
- HIV +, HAART tedavisi altında HIV-1 RNA düzeyinde düşme
- CD4 sayısında artış
- Klinik bulgular fırsatçı enf ya da ilaç toksisitesinden daha çok enfl süreçle uyumlu
- IRIS- MSS'de NIRIS olarak isimlendirilir

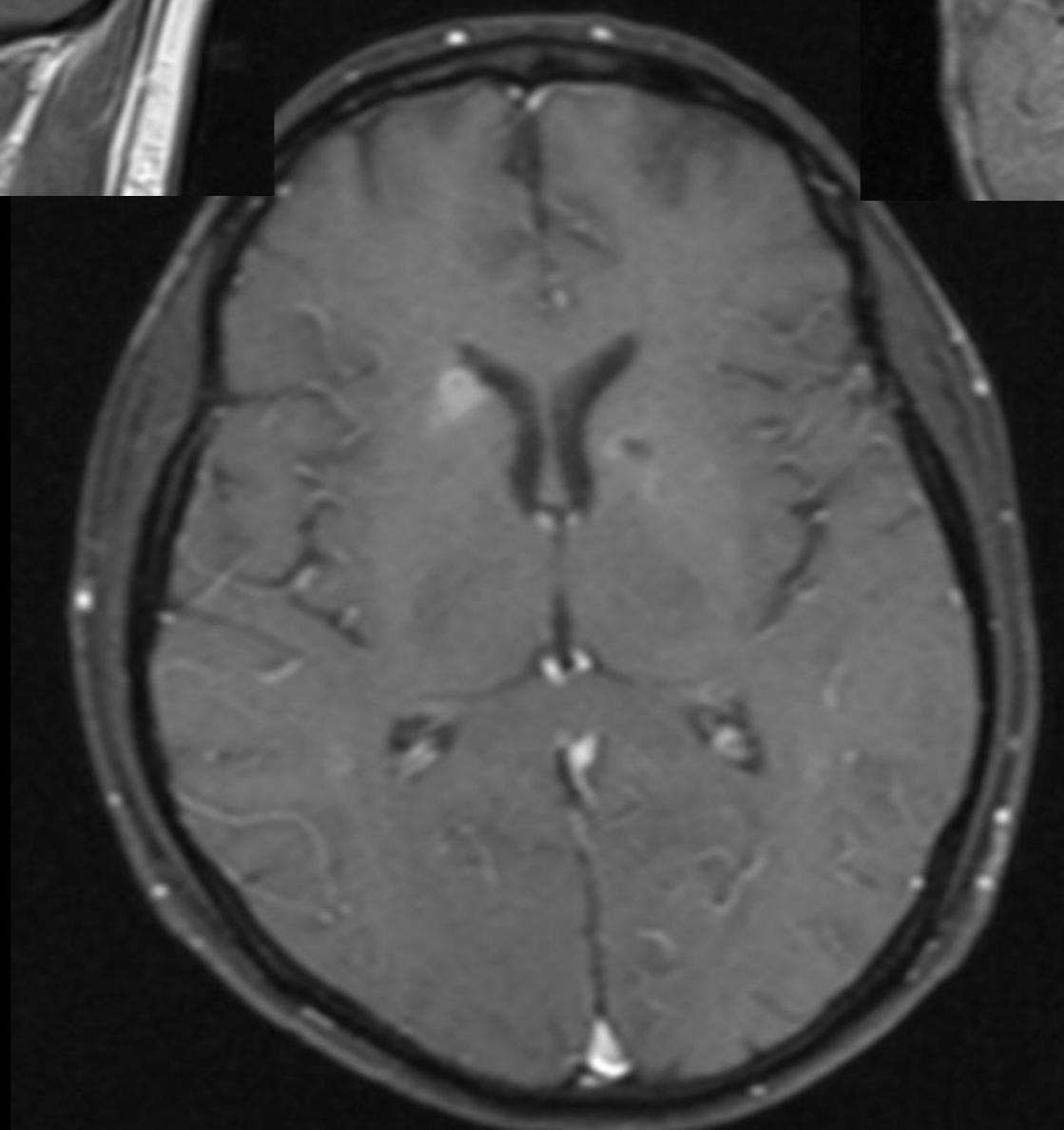
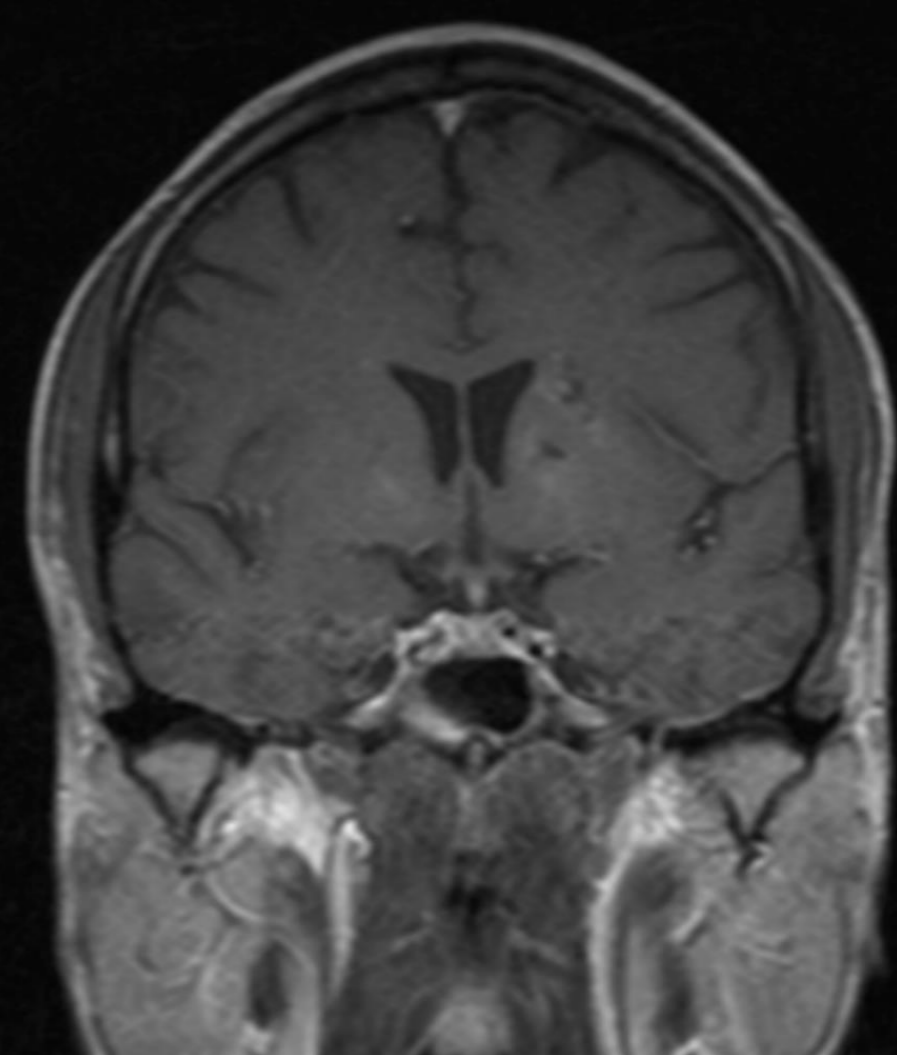
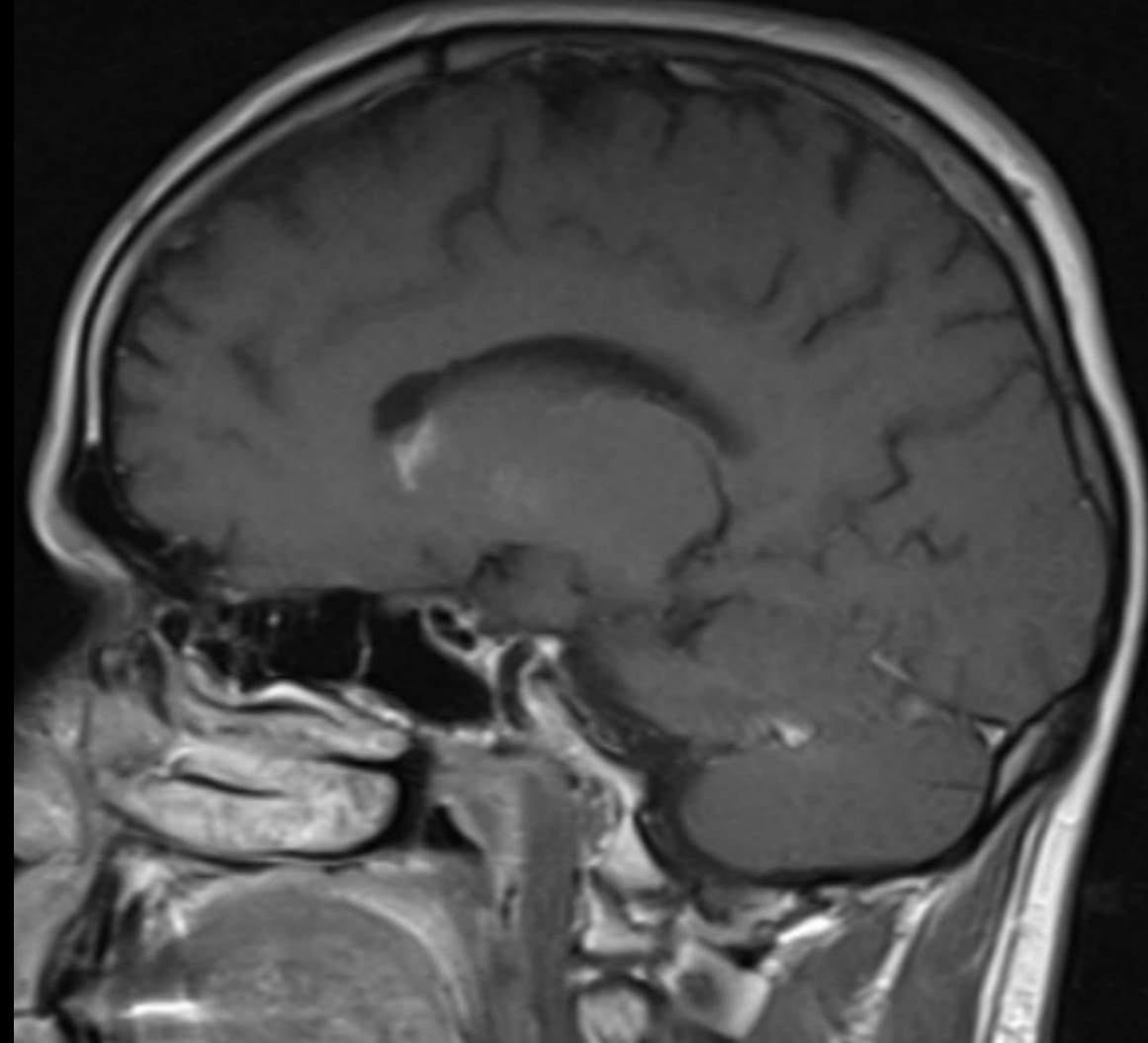


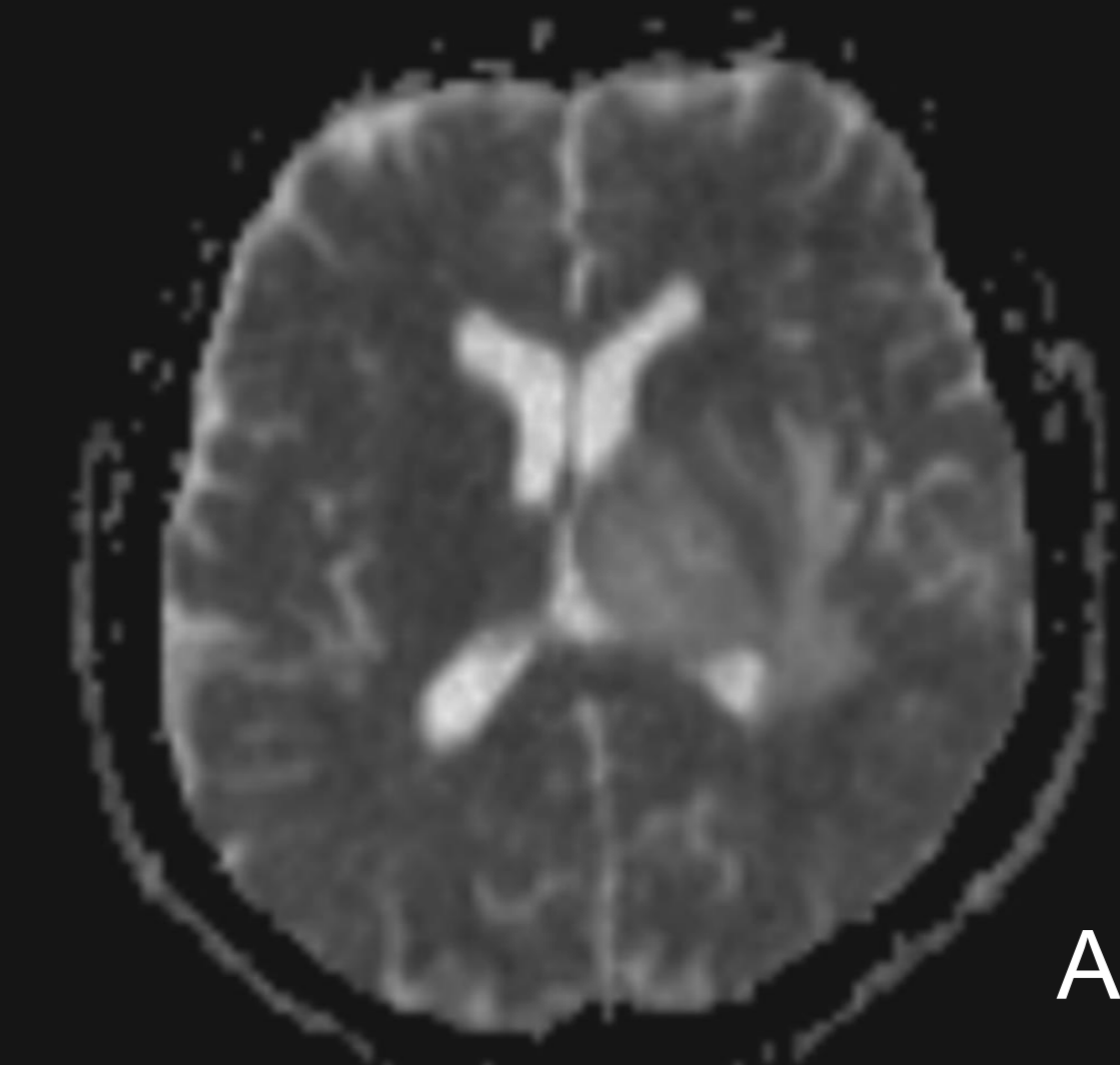
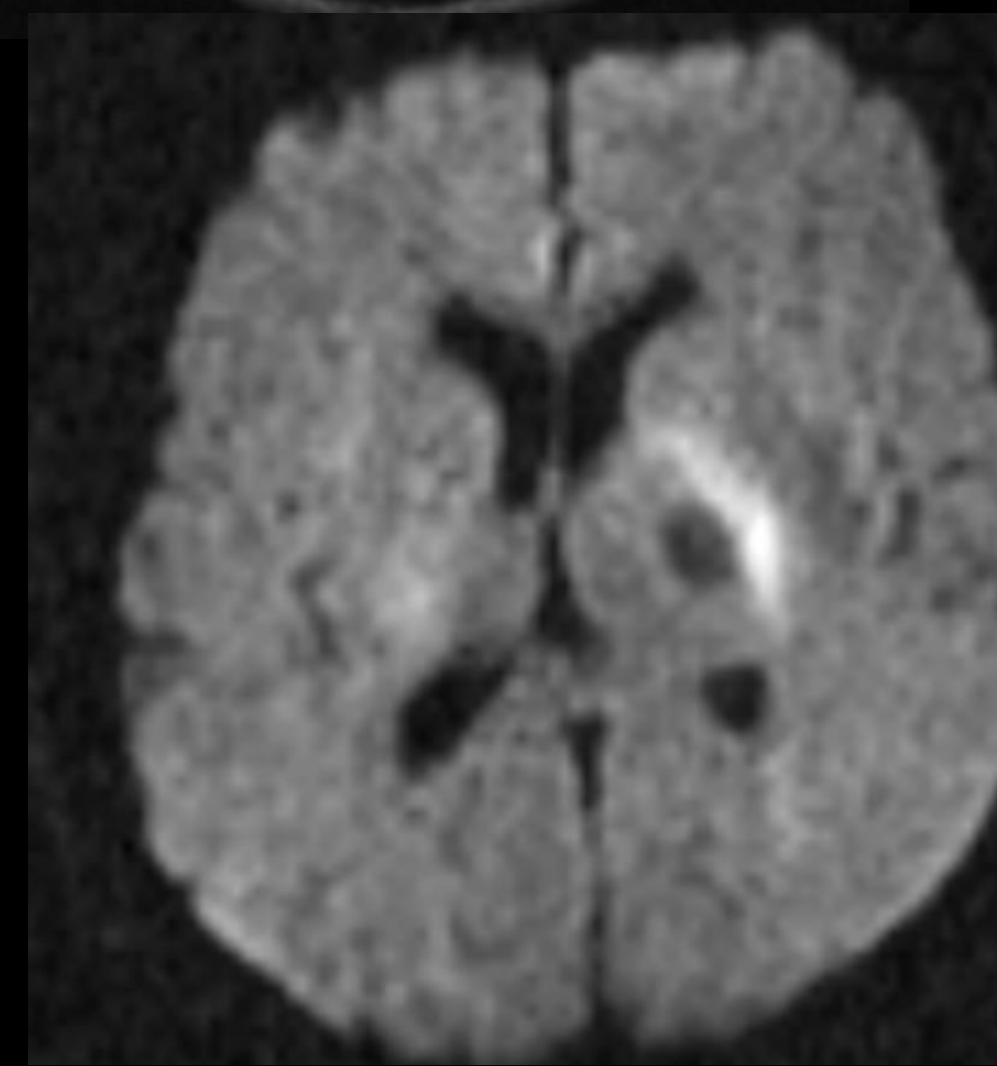
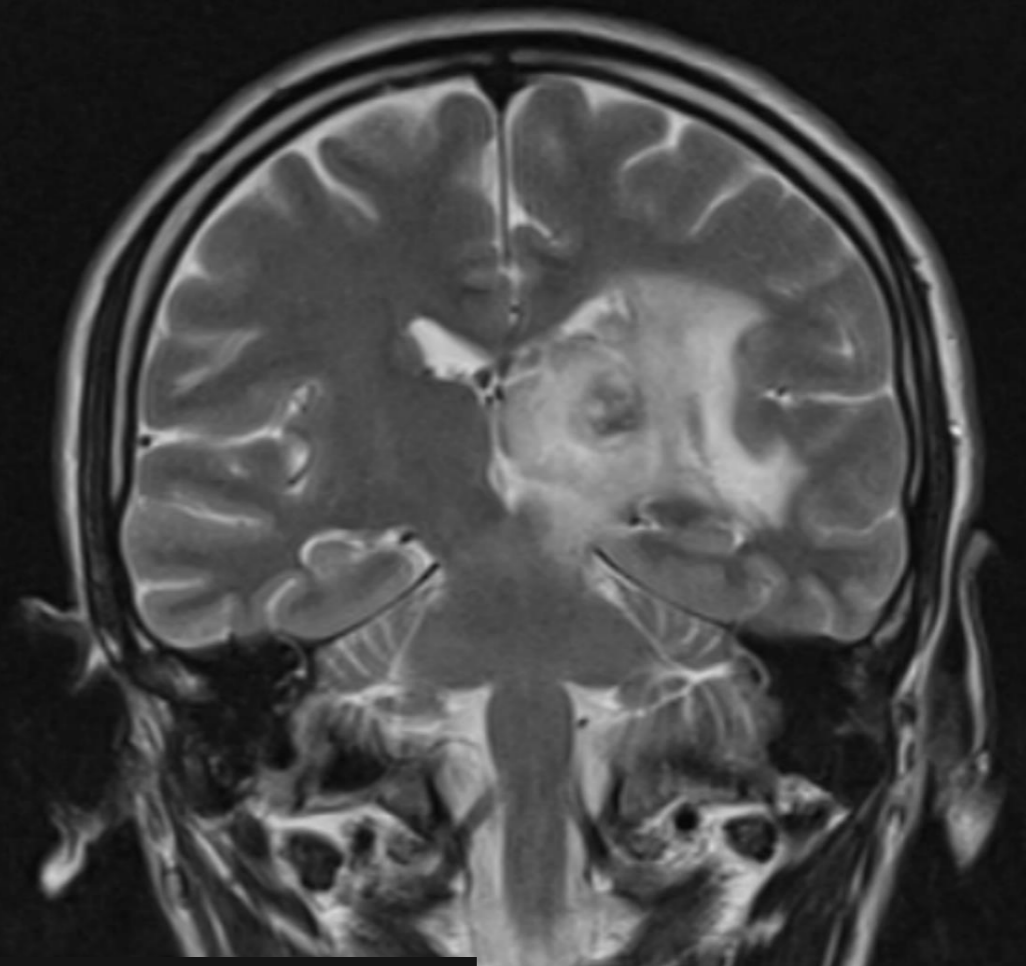
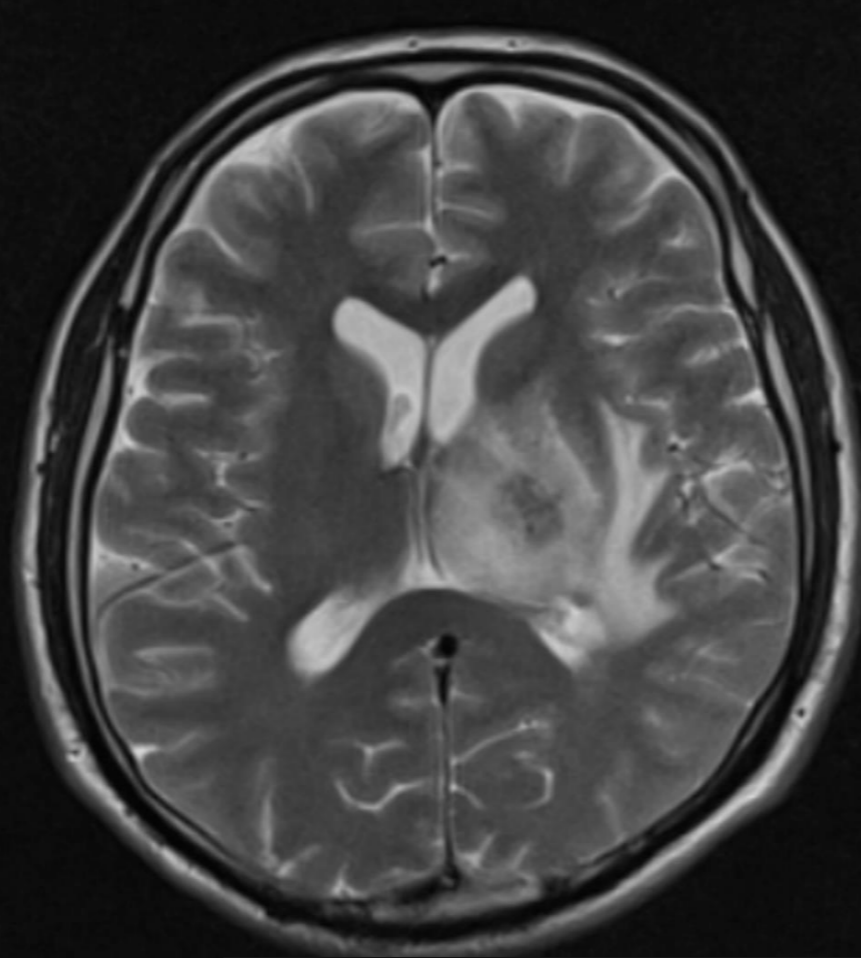
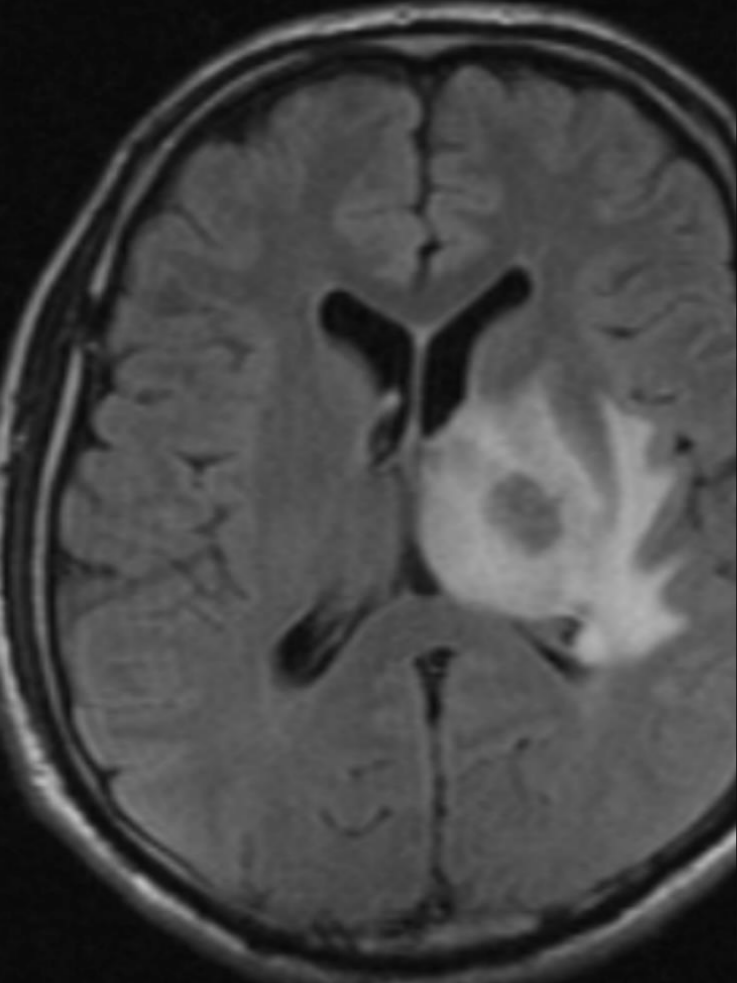
Mayis 2015
HAART



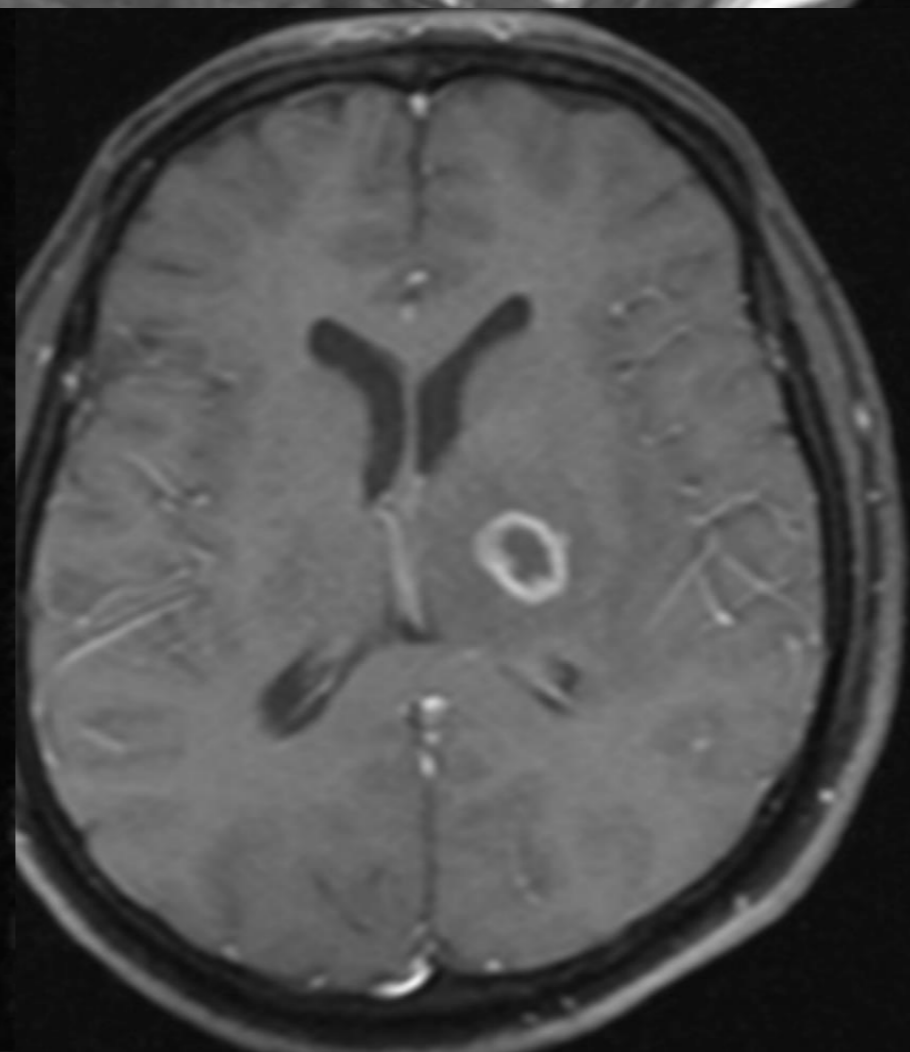
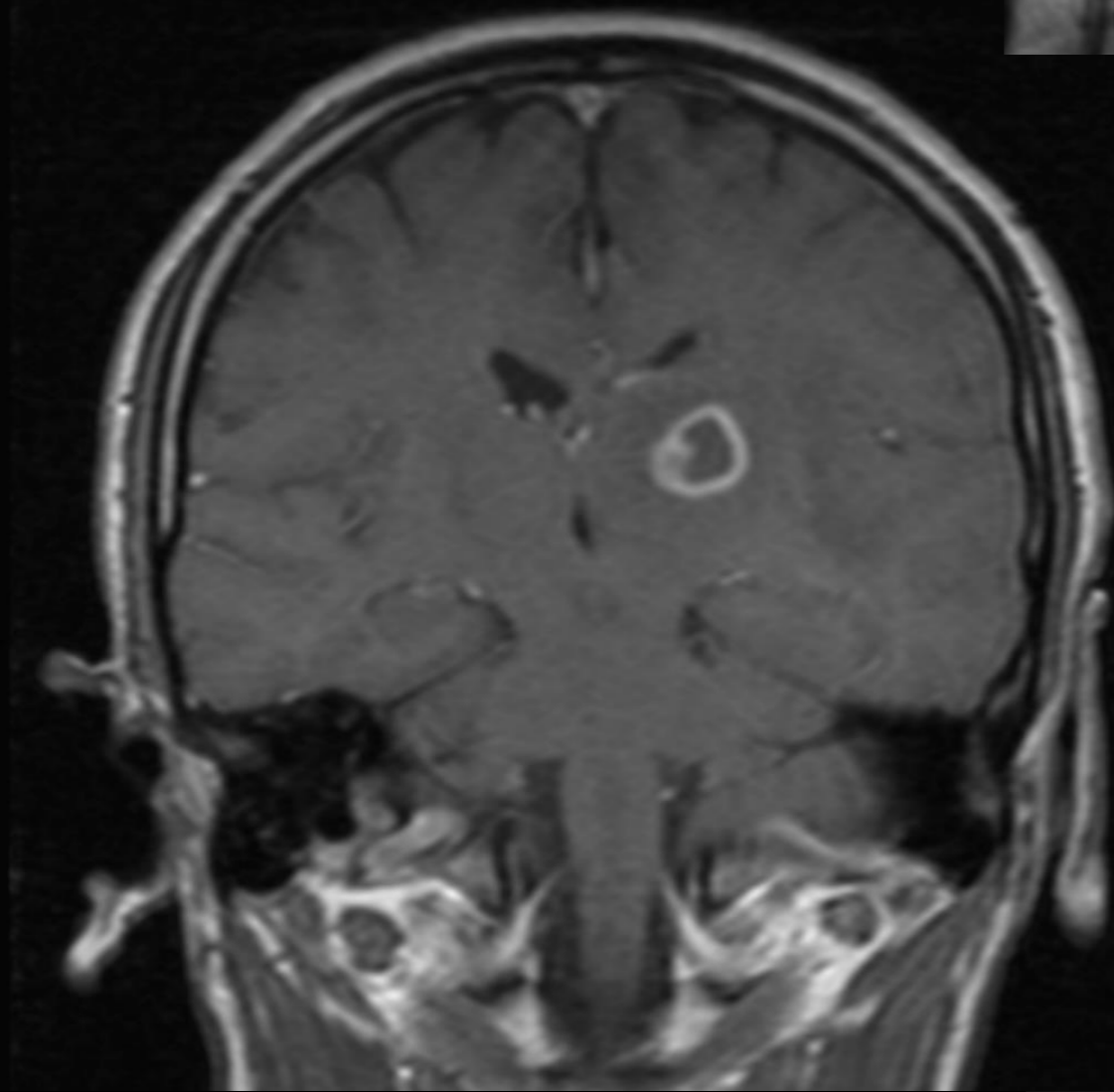
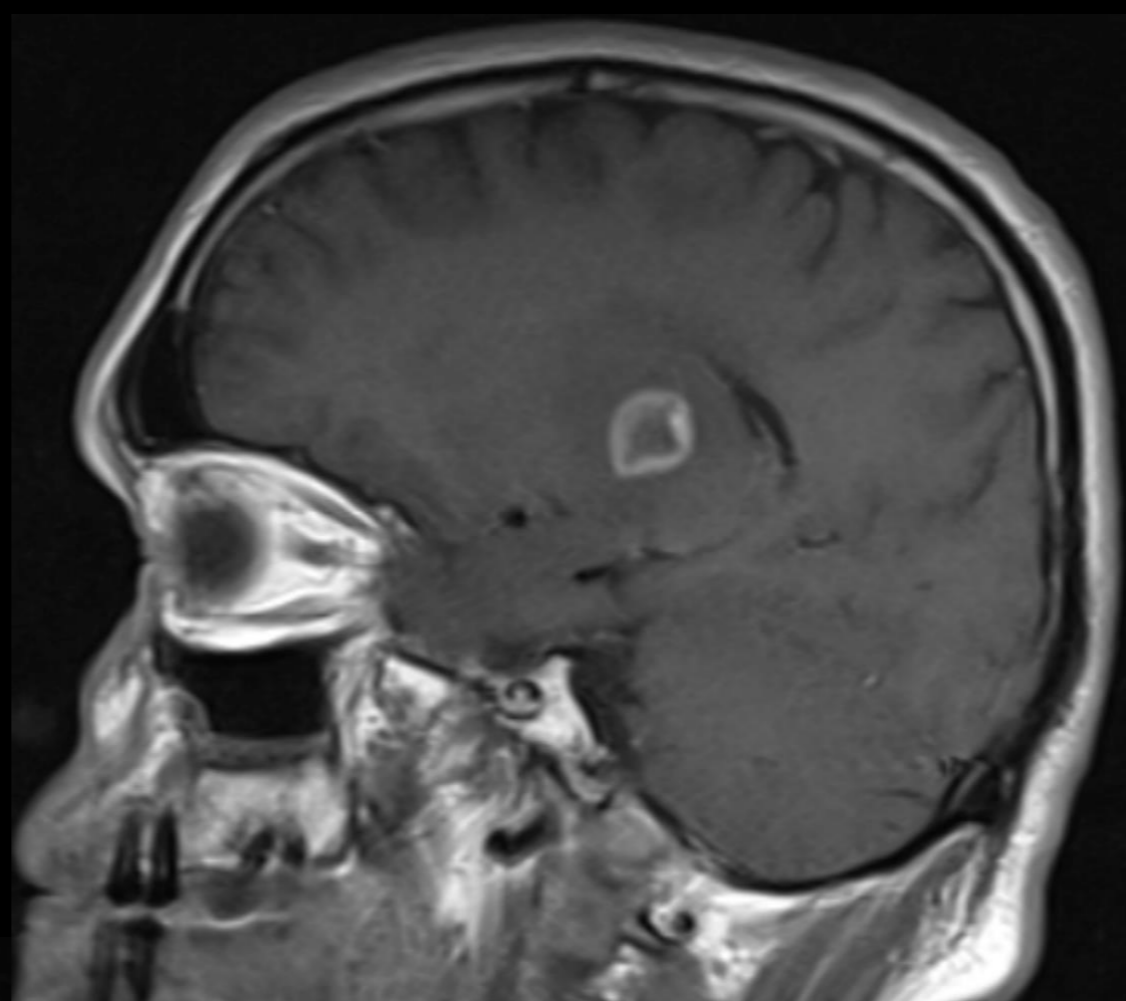
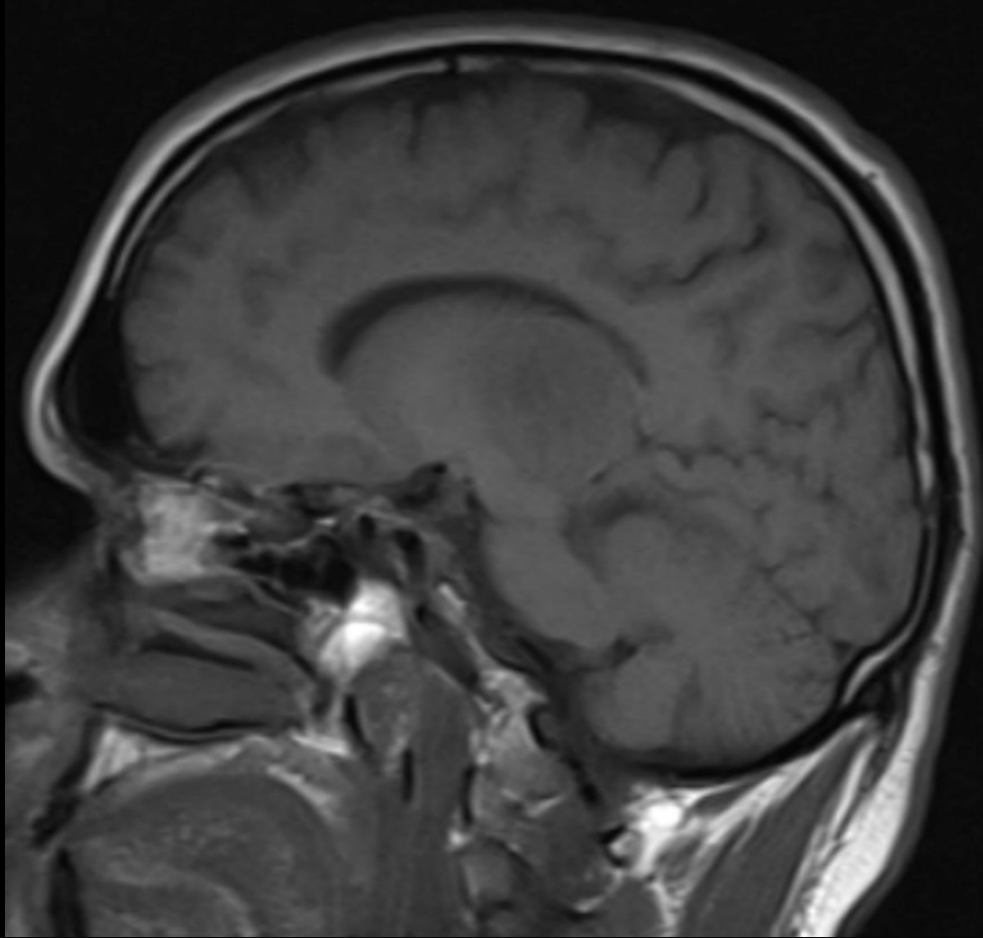
Ocak 2016



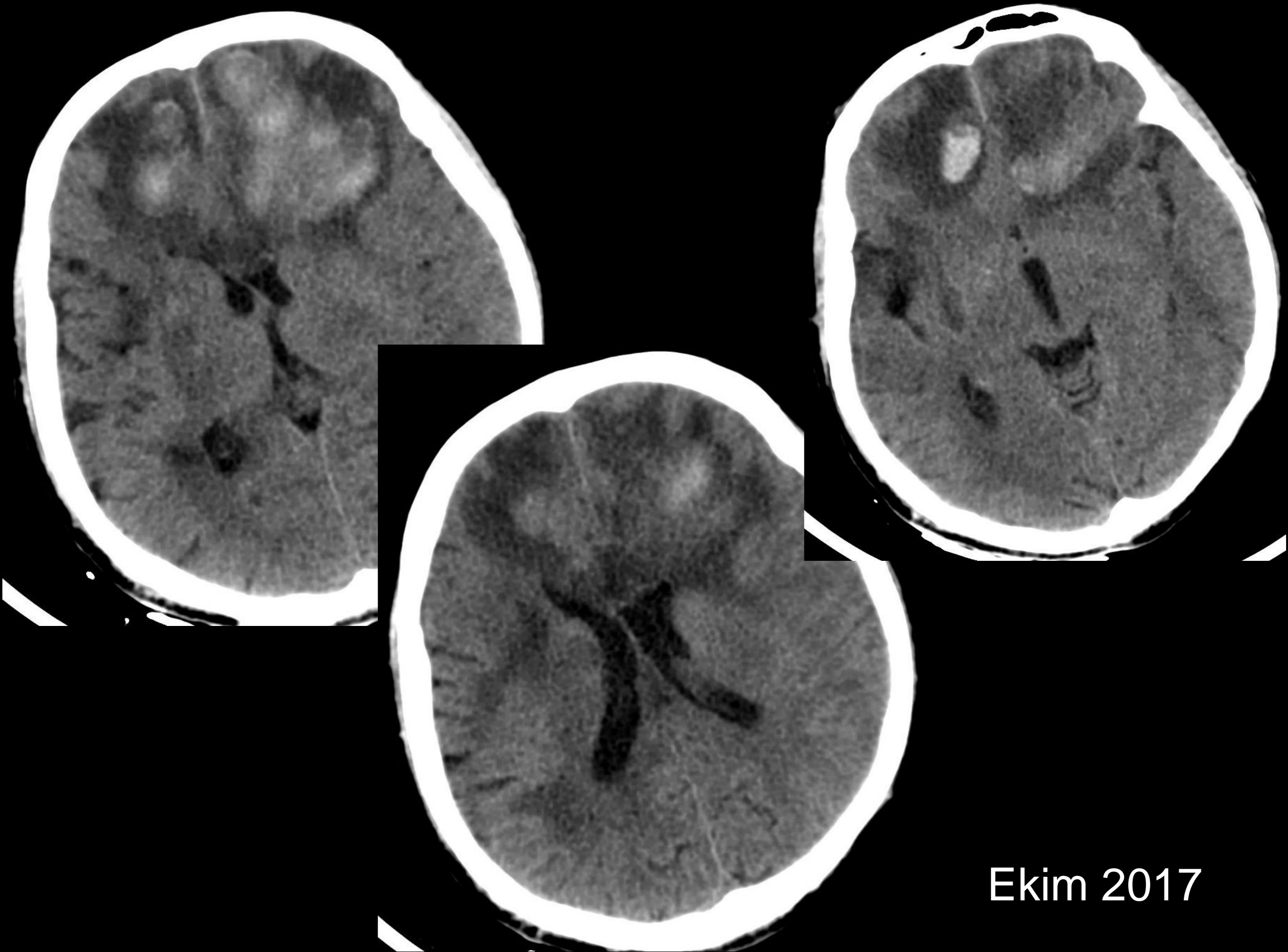




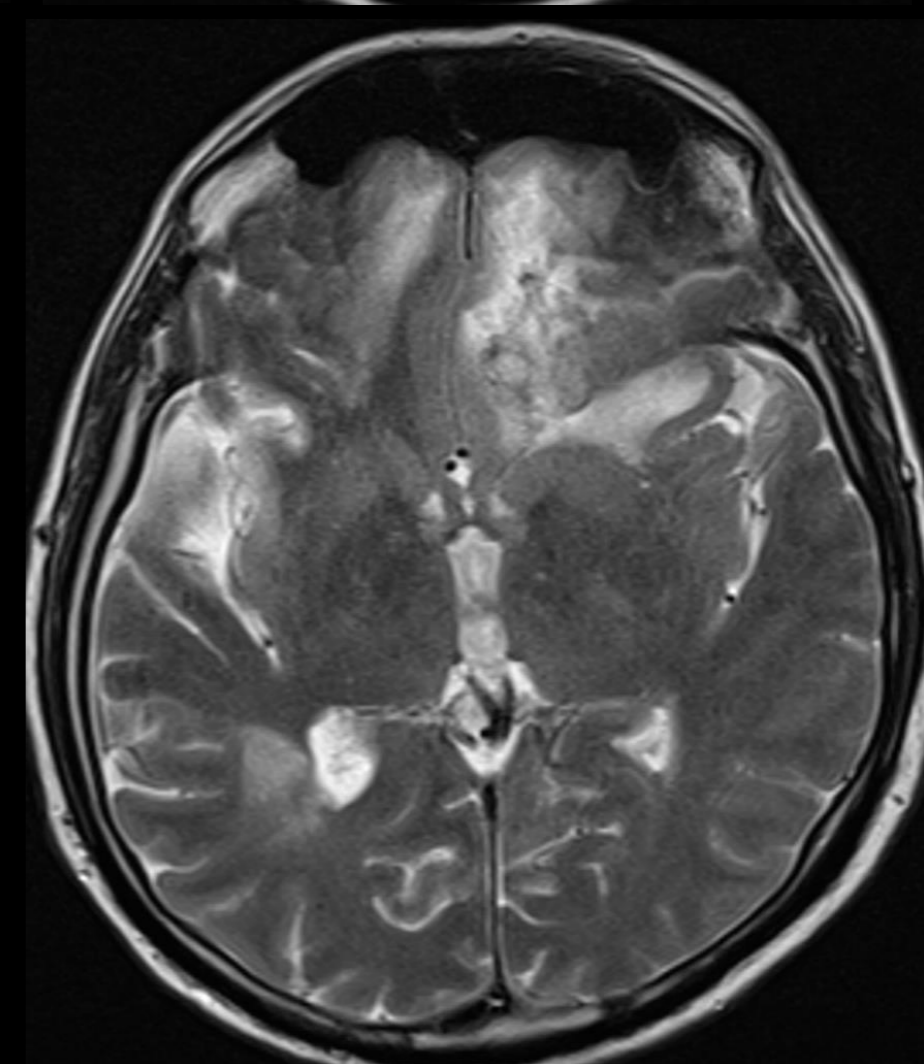
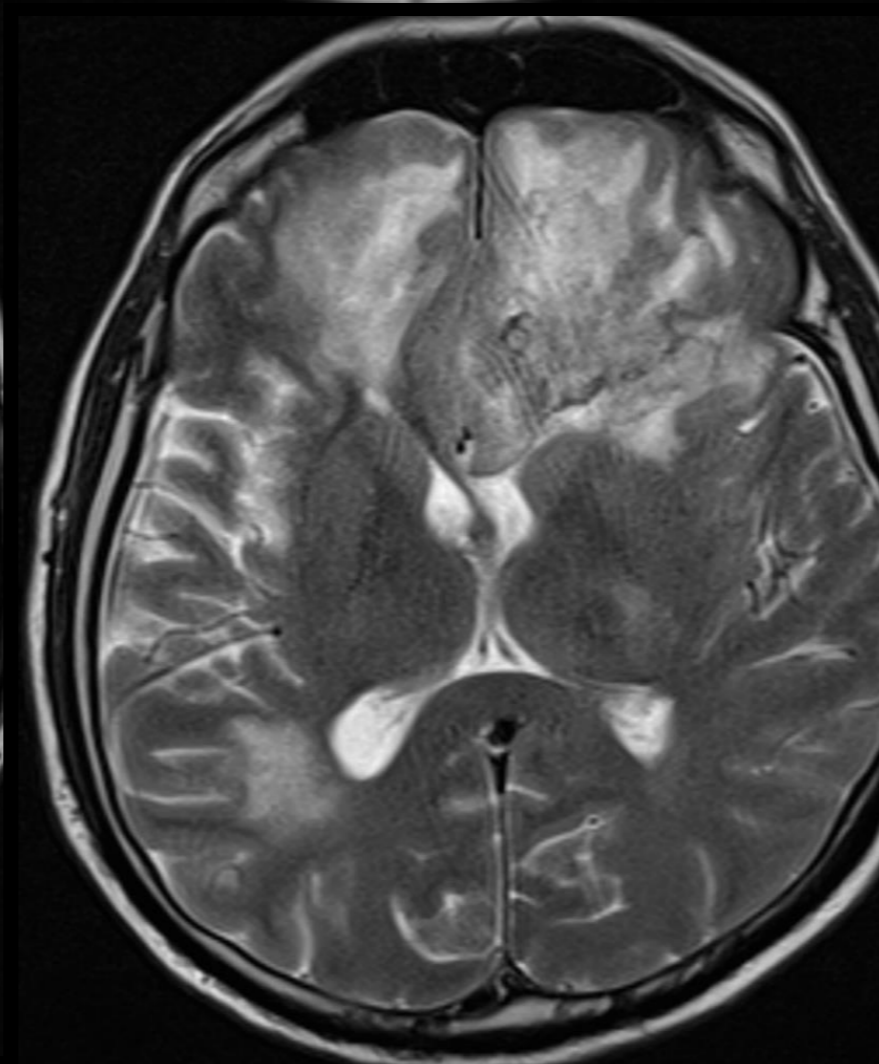
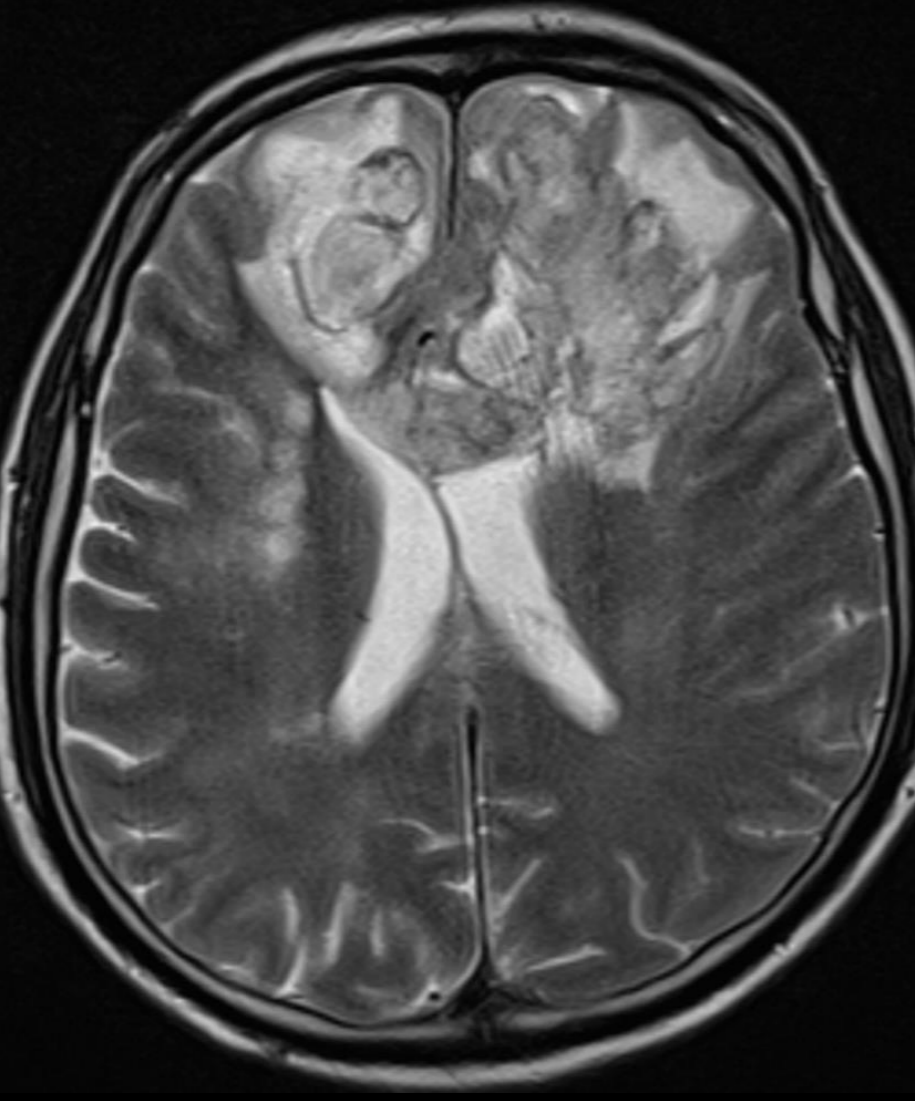
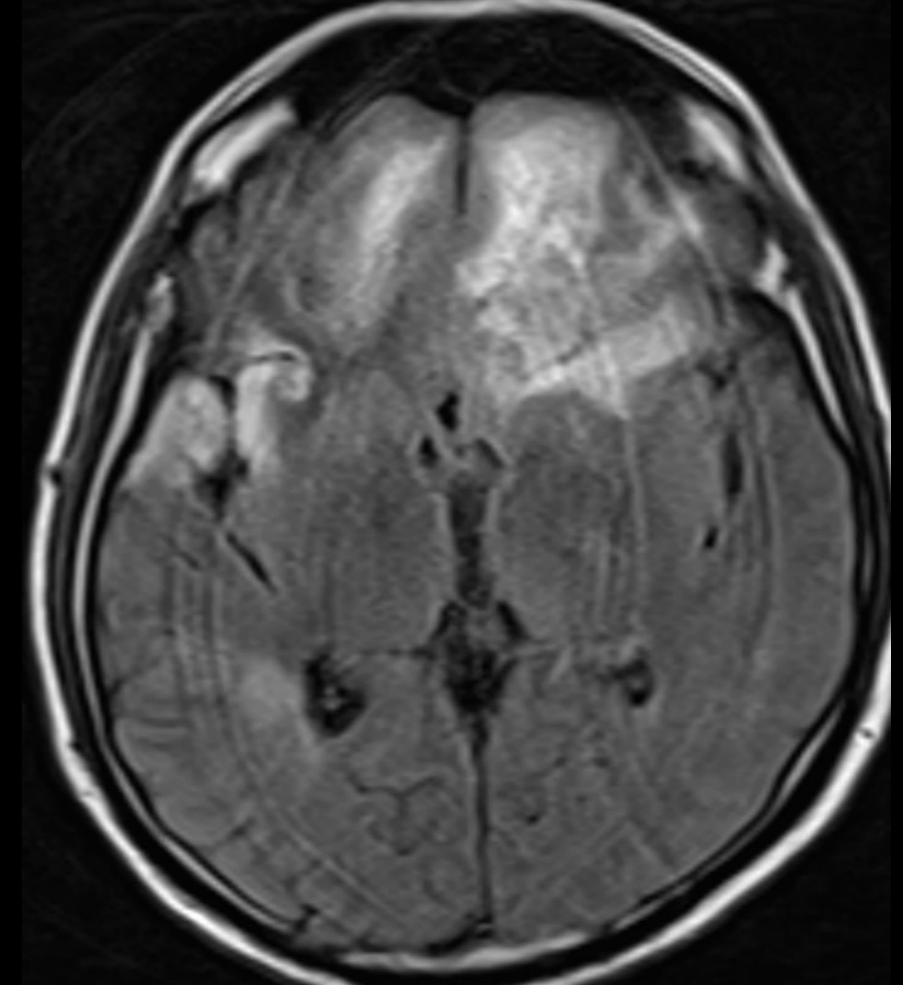
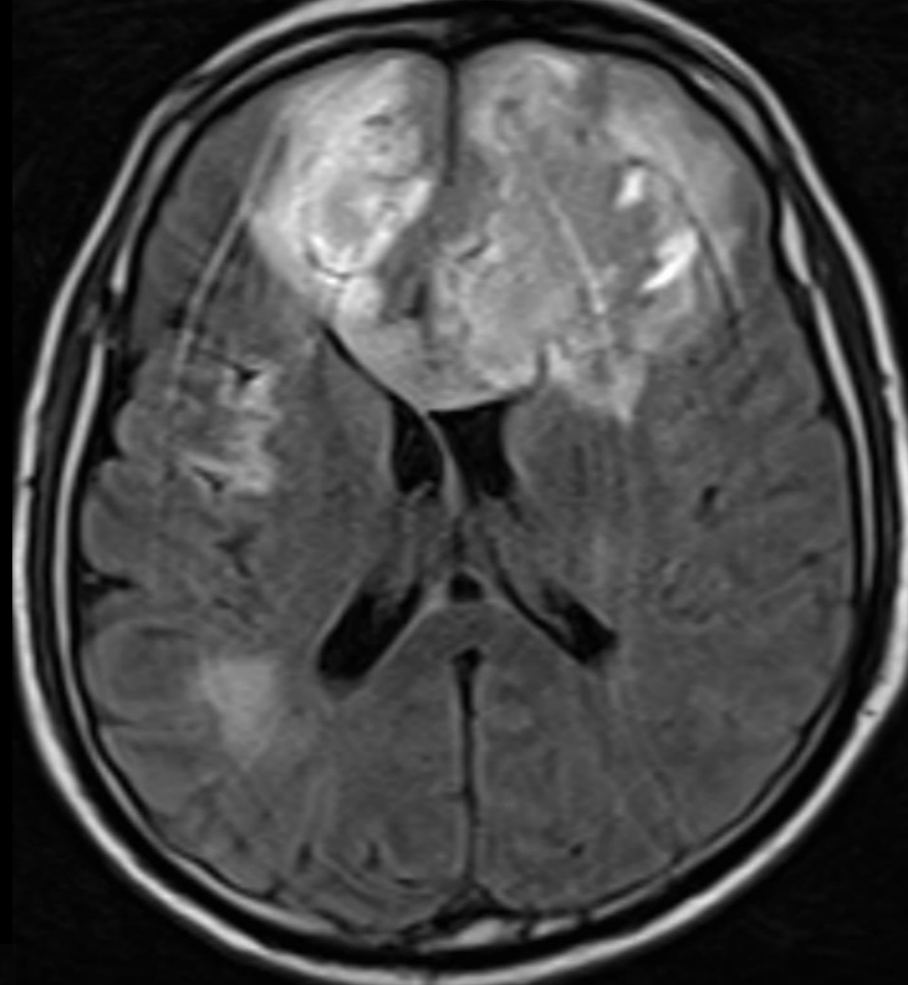
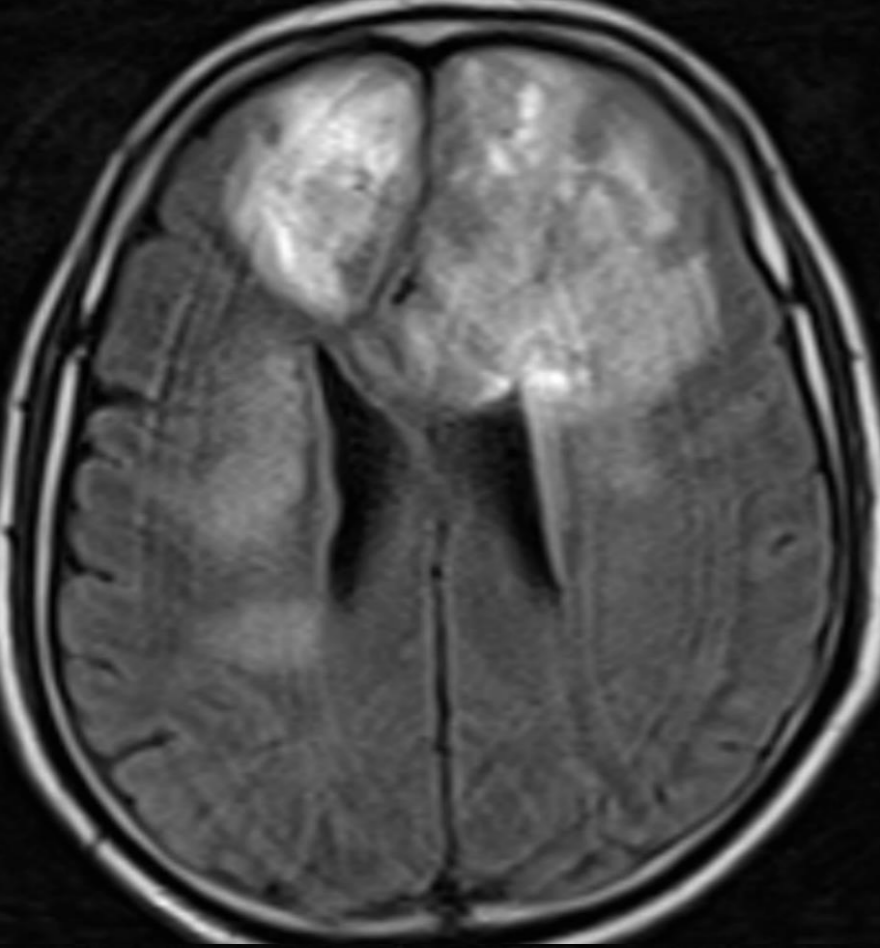
Ağustos 2017

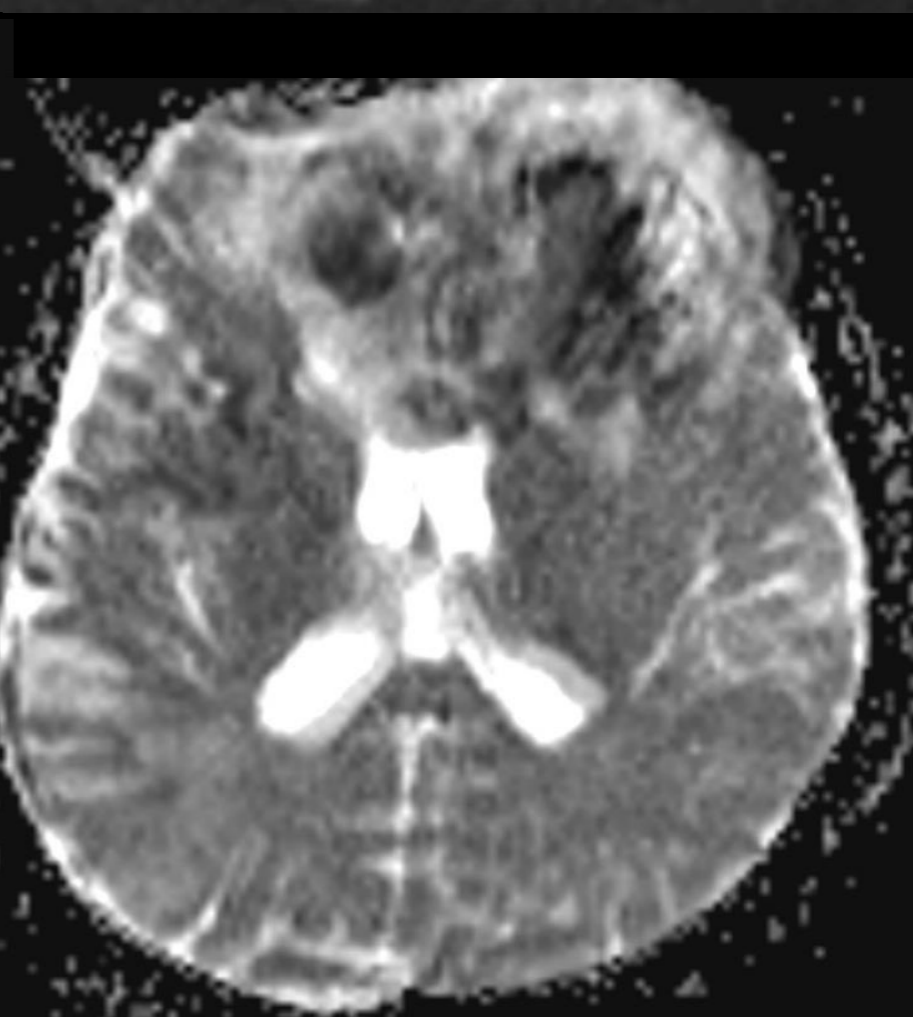
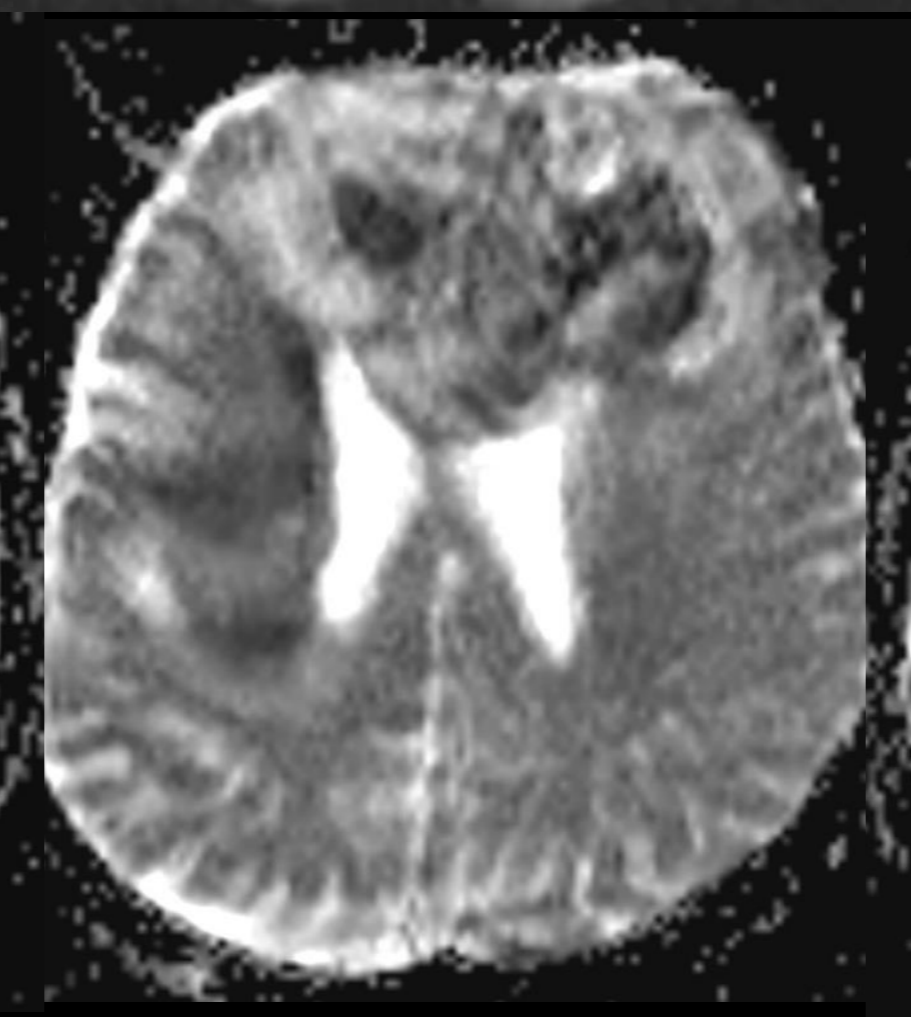
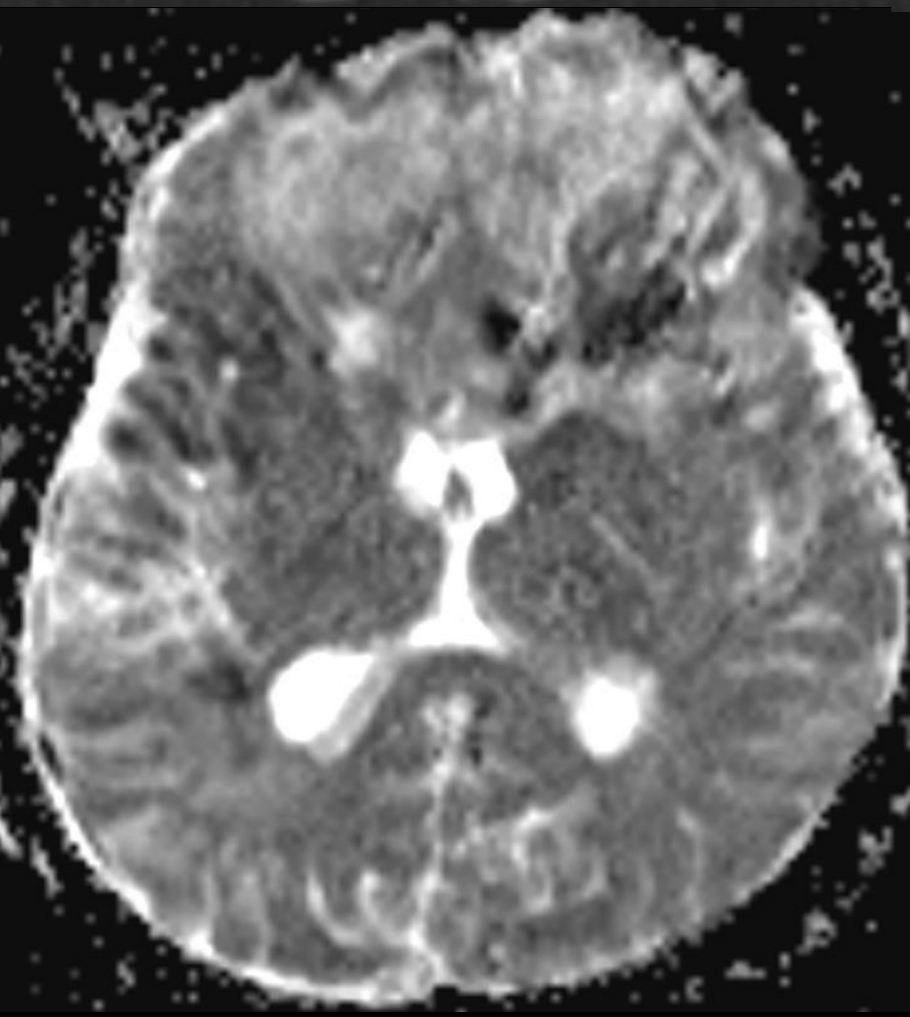
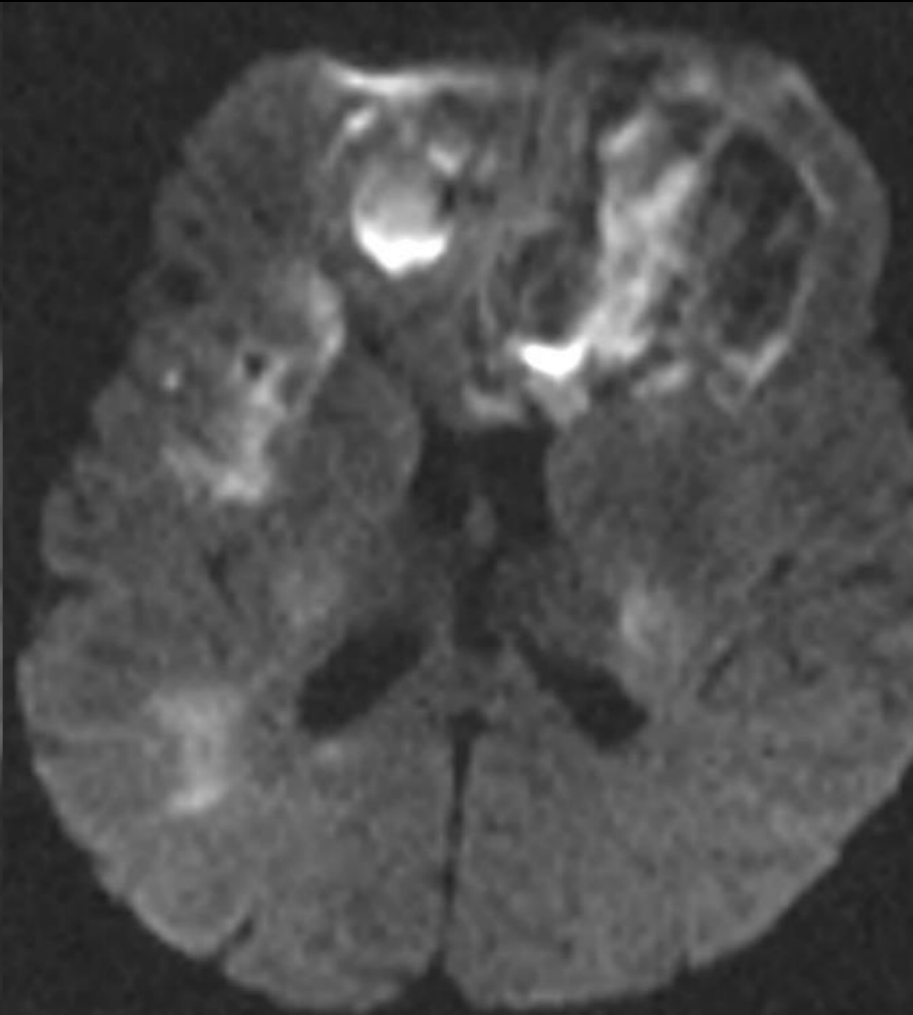
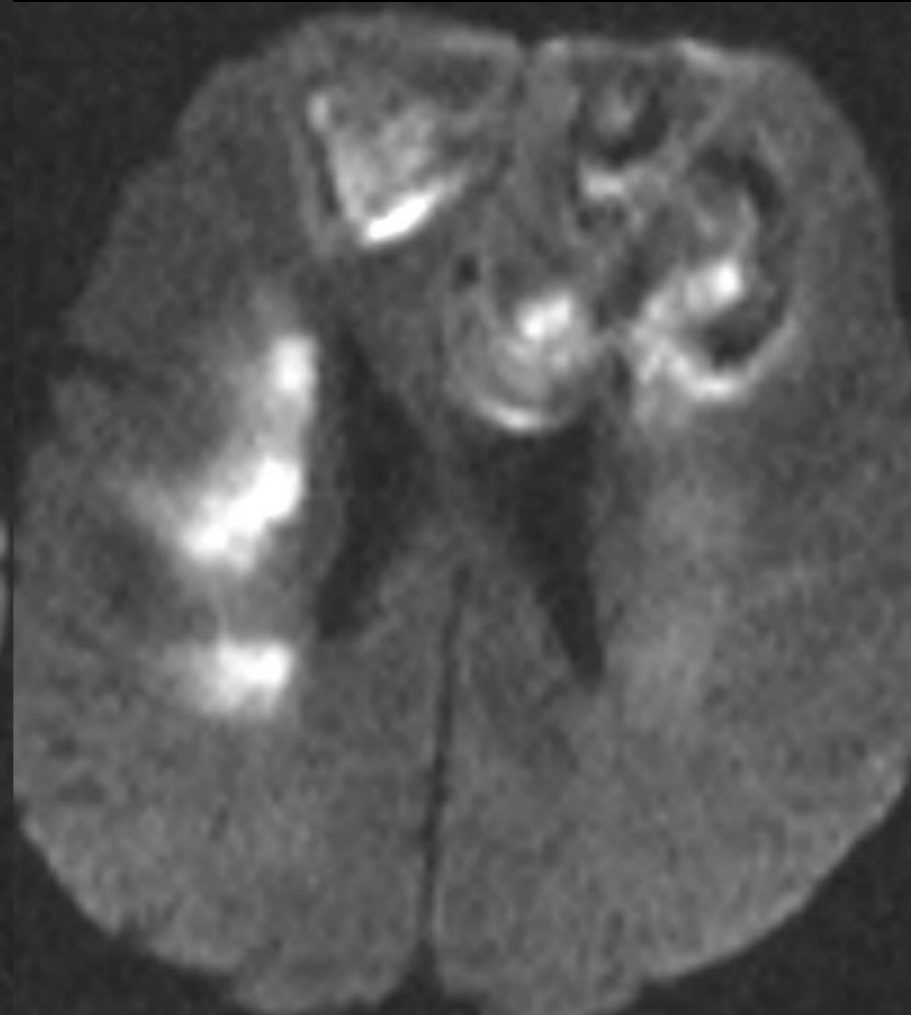
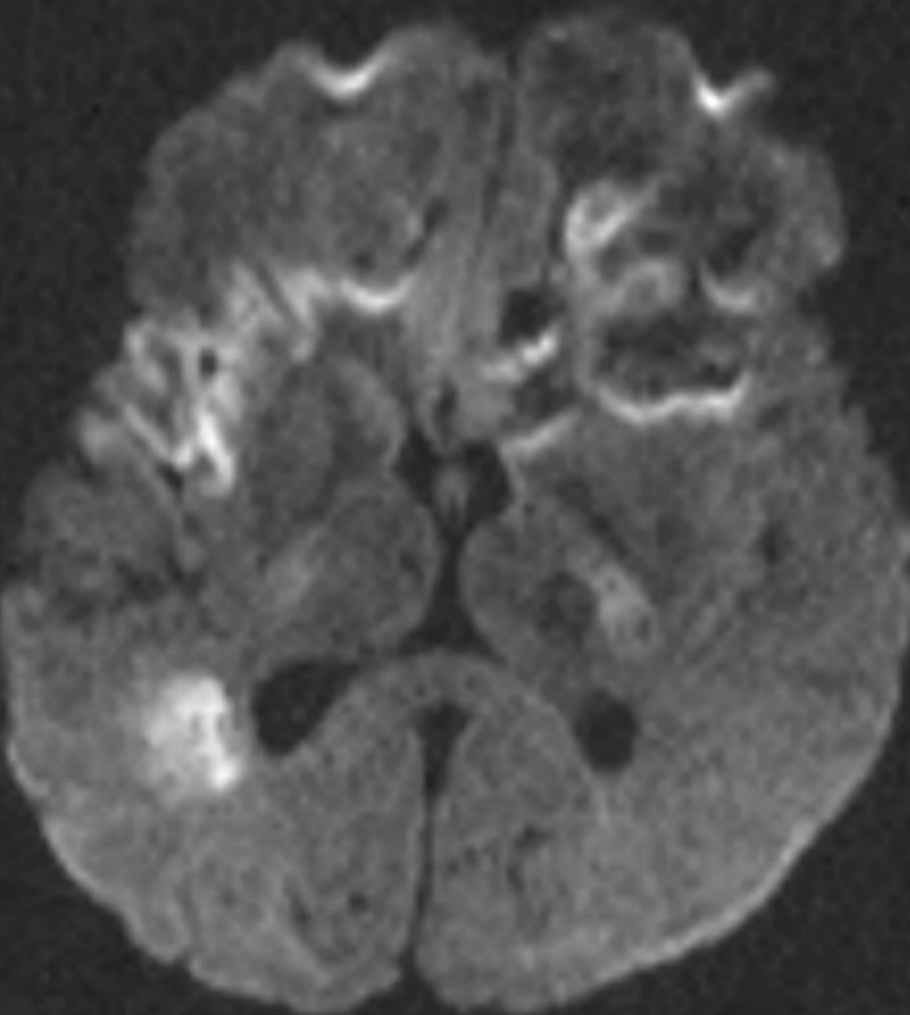


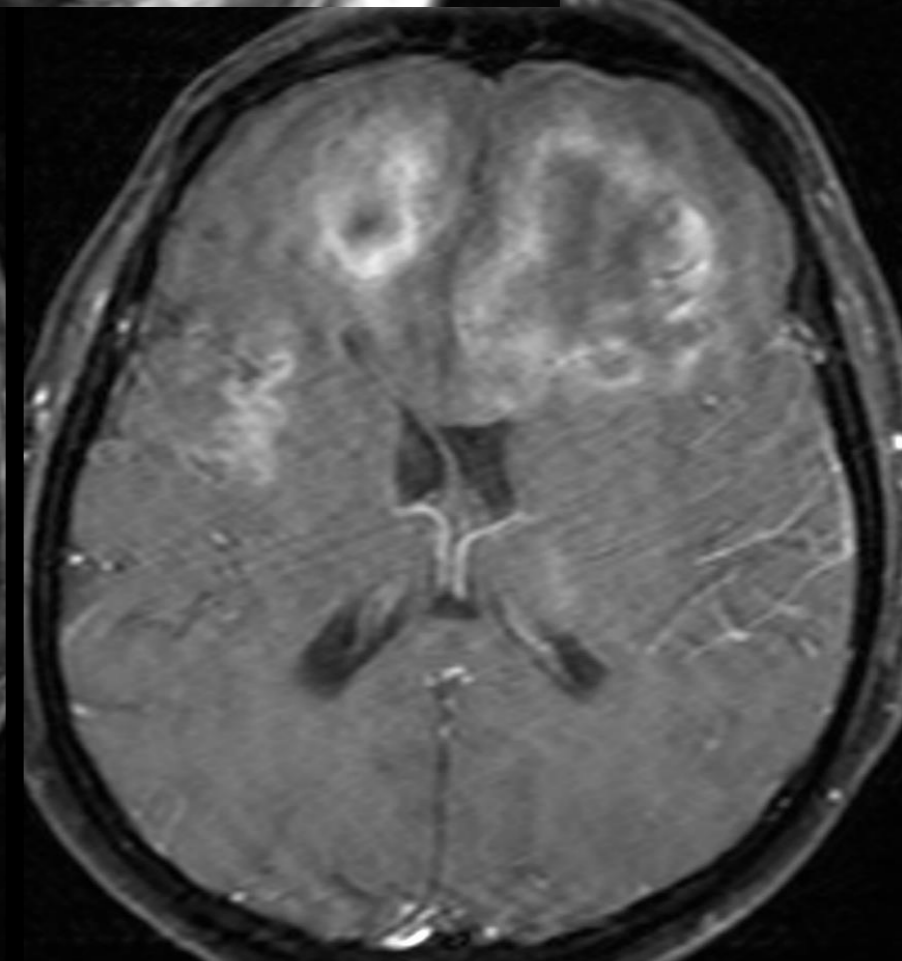
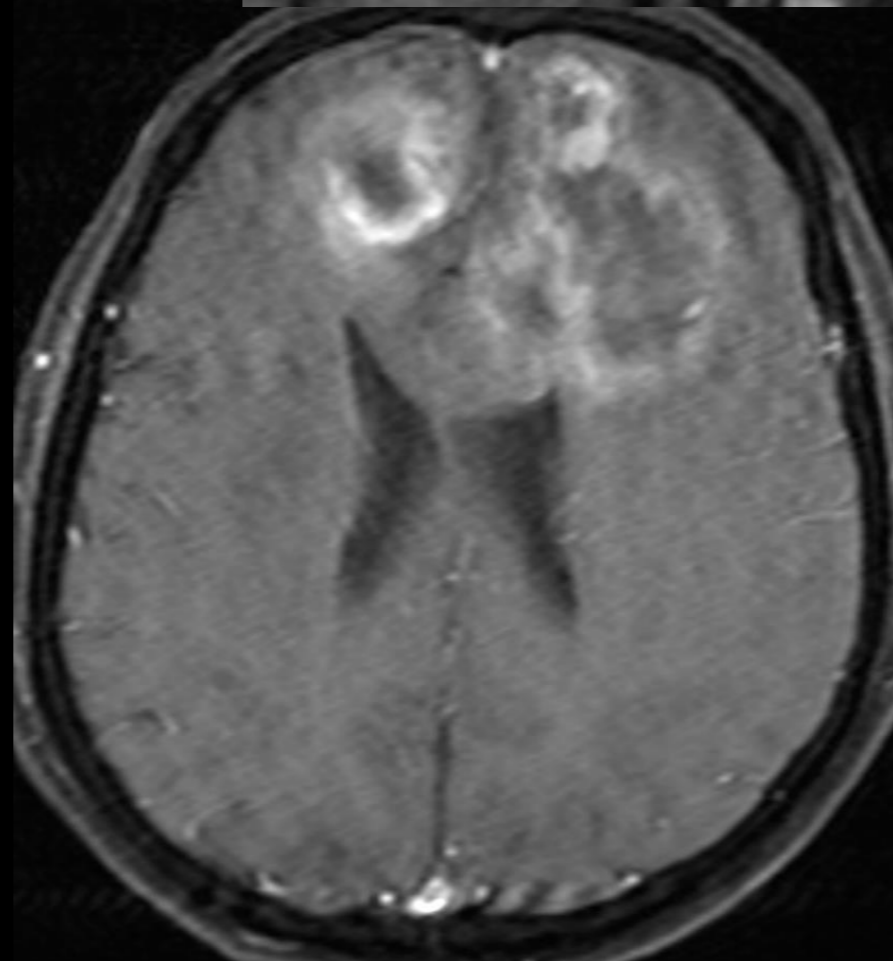
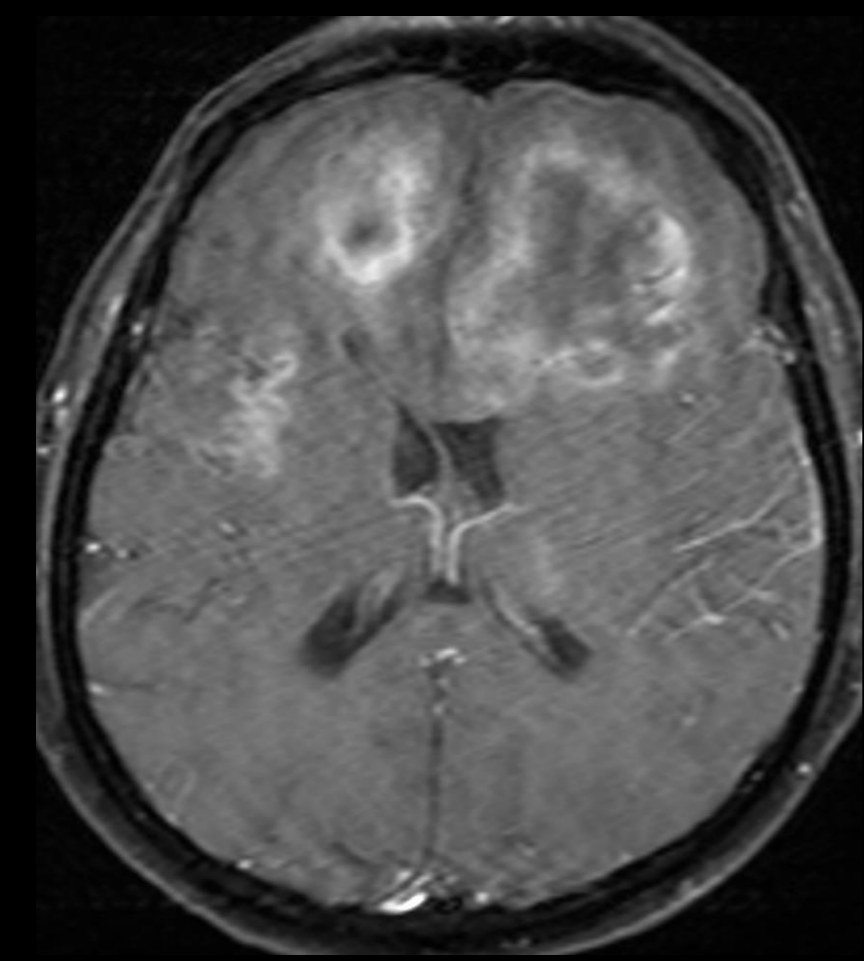
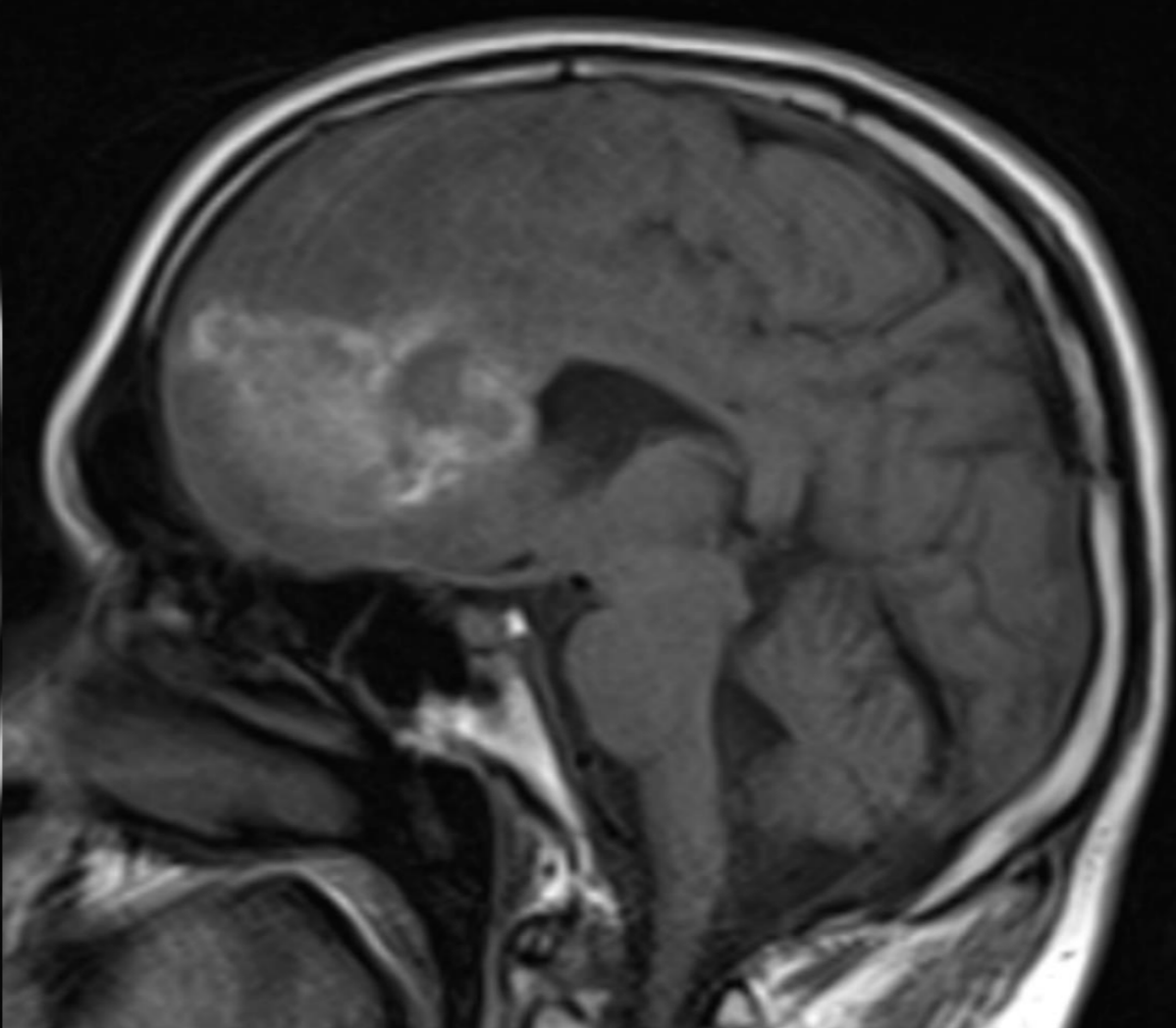
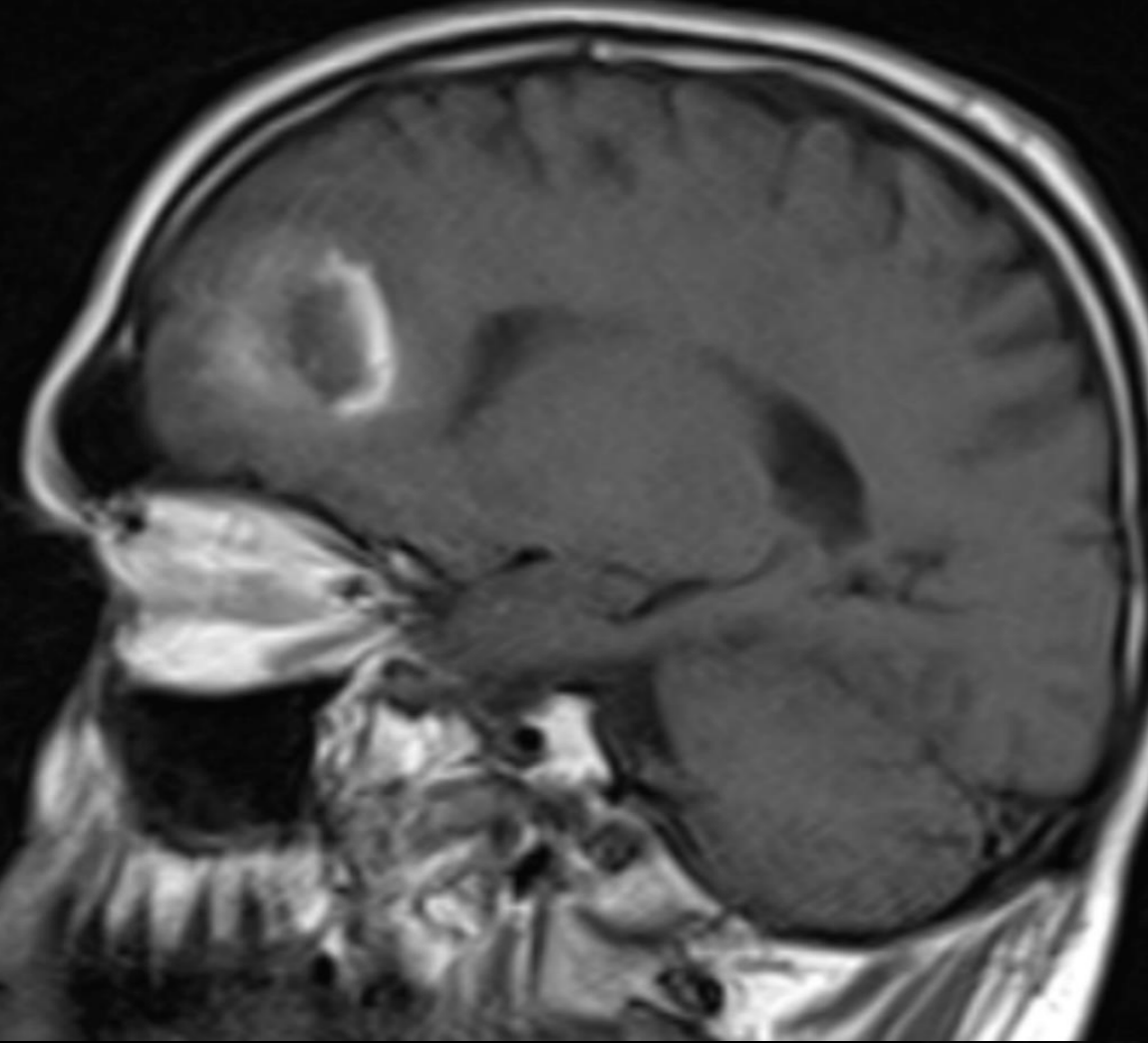
Toxo



Ekim 2017







IRIS A. Tanı

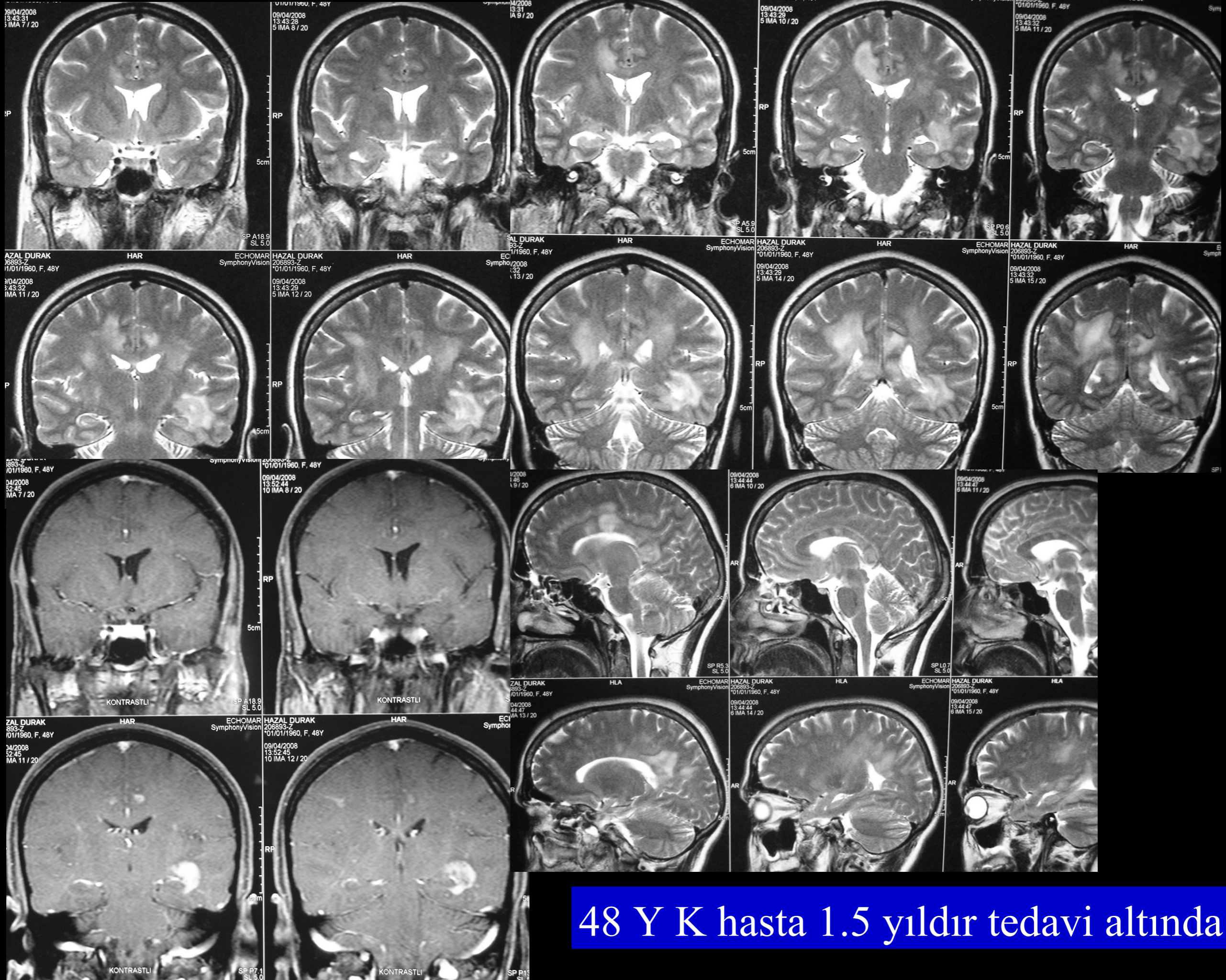
- Fırsatçı enf.lar
- AIDS eşlik eden maligniteler
 - Öz.le lenfoma

AIDS ilişkili maligniteler

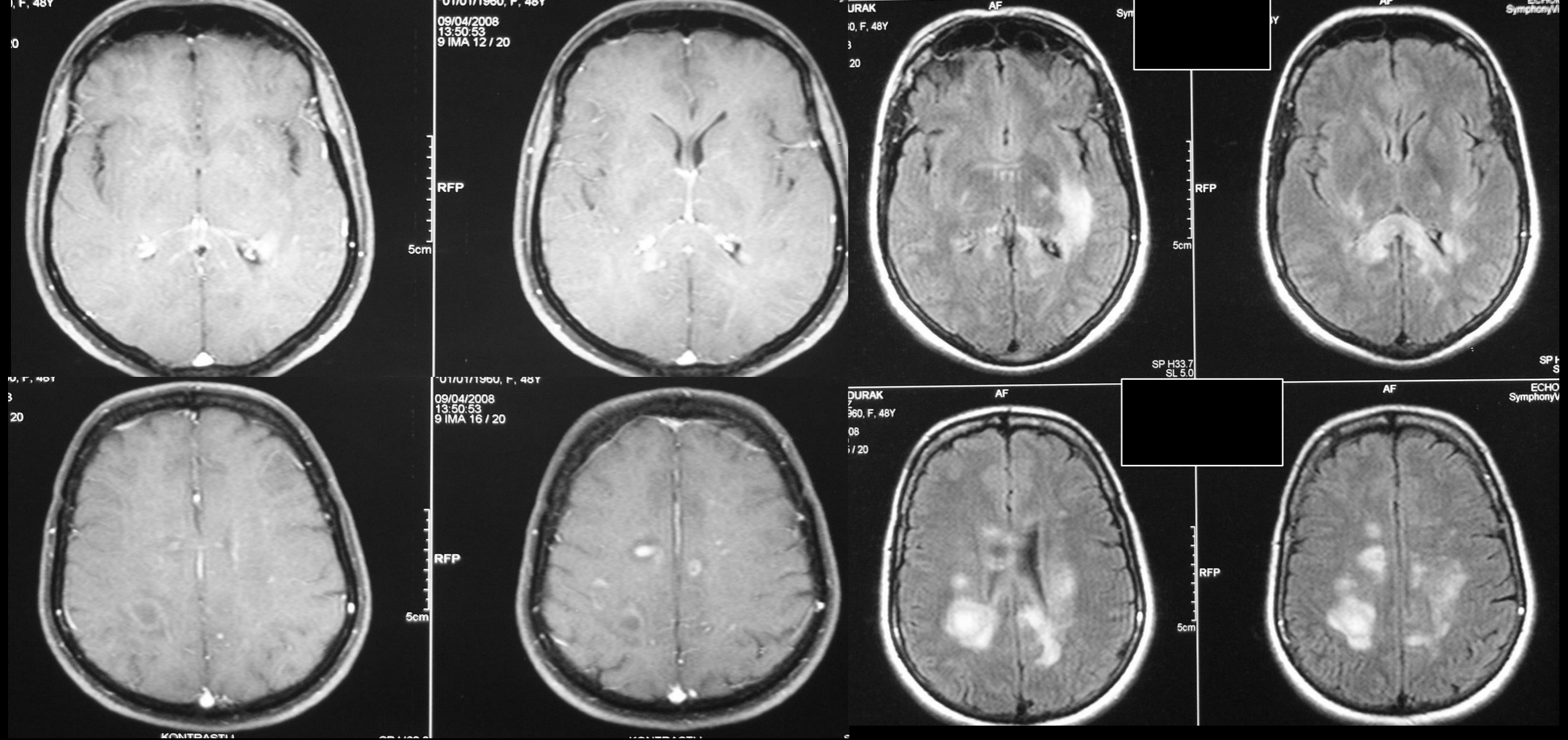
- En sık g lenfoma
- Diffüz büyük B h.li, NHL tipi
- Sıklıkla EBV ile birlikte
- AIDS'te en sık g 2. kitle

AIDS ilişkili Lenfoma

- Kanama ve nekroz sık
- %90 supratent
- Bazal gang, derin ak madde
 - Sıklıkla KK'dan geçer (GBM taklit)
- Halkasal kontrastlanma sık
- ↑ rCBV

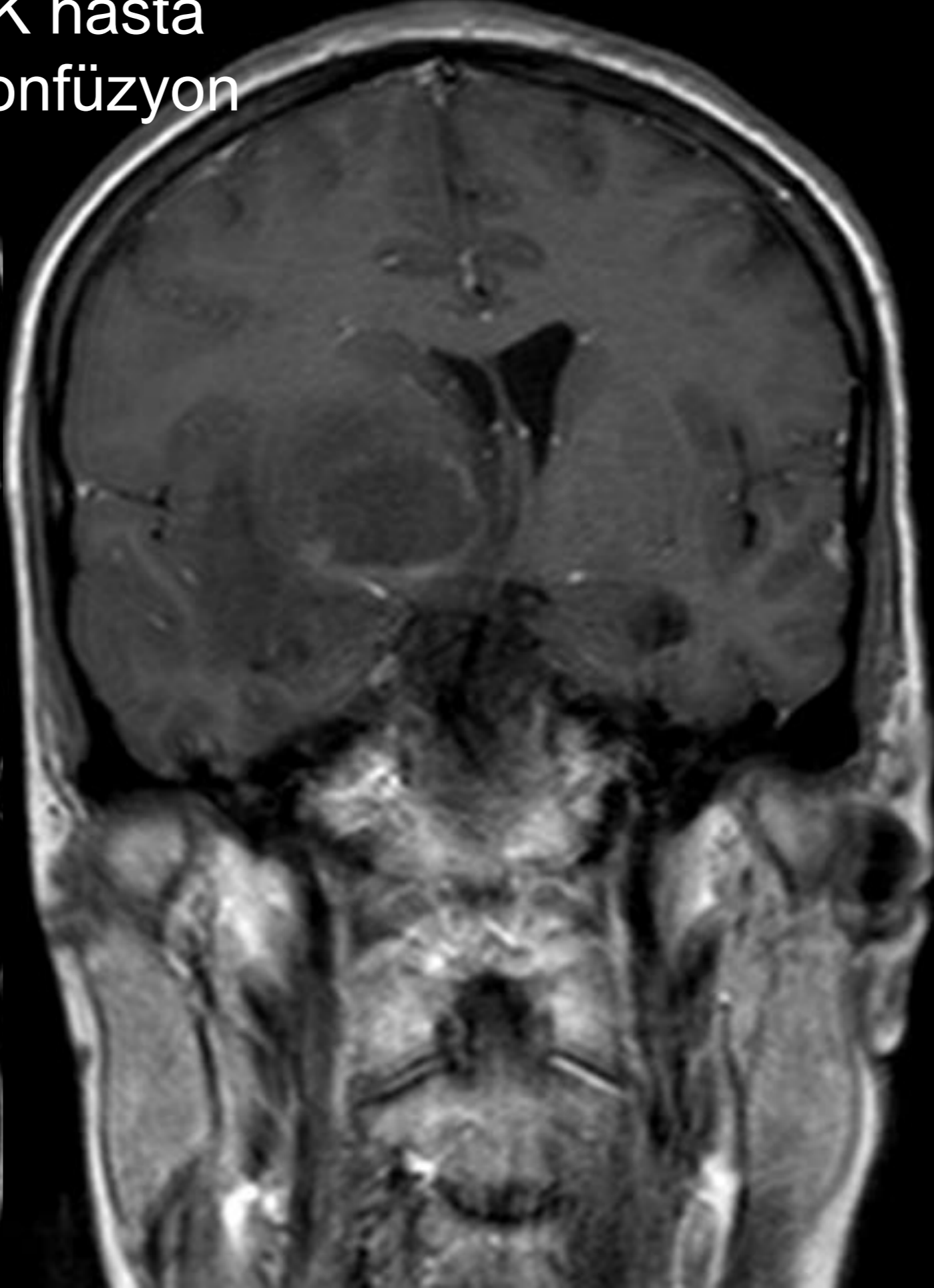
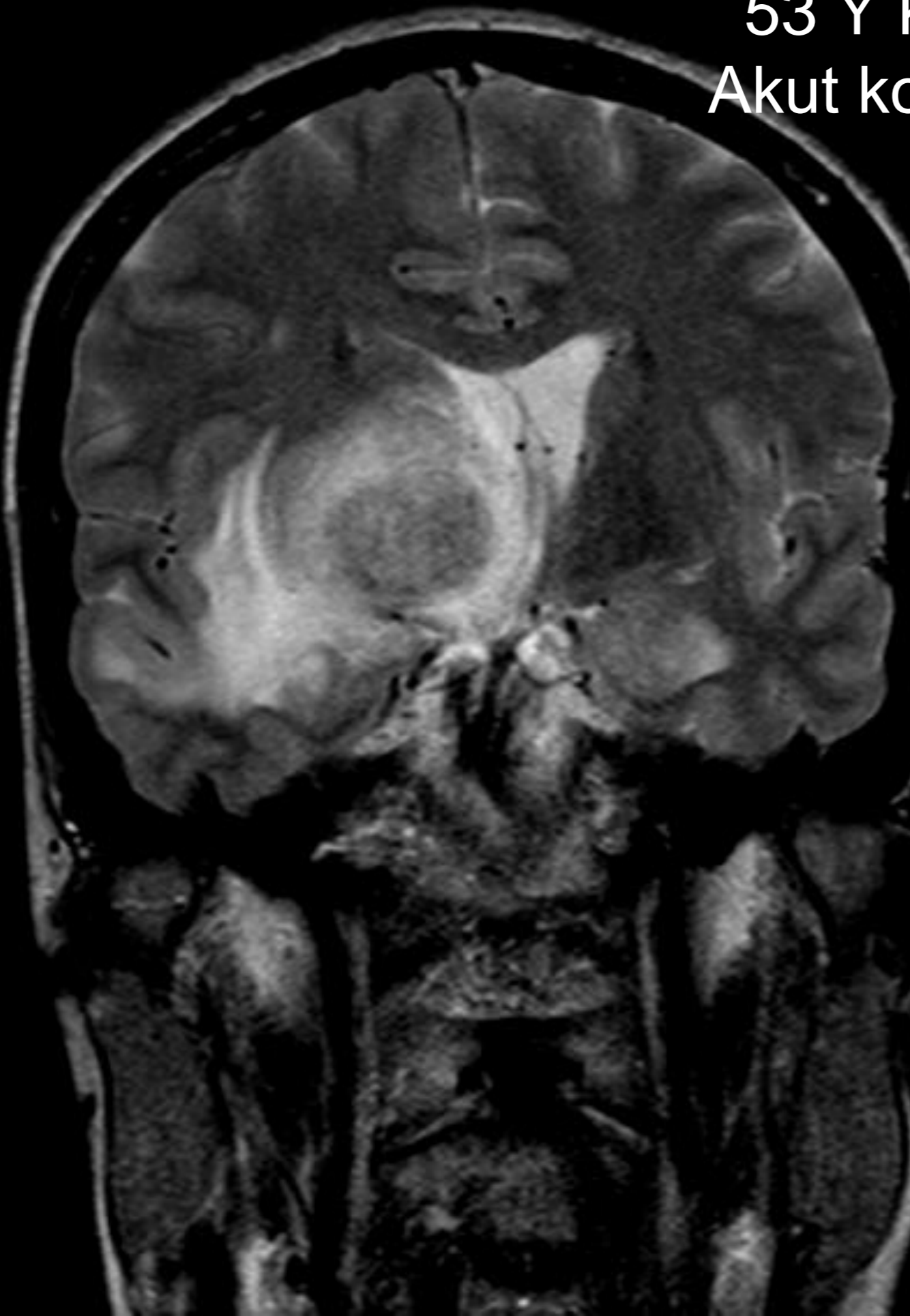


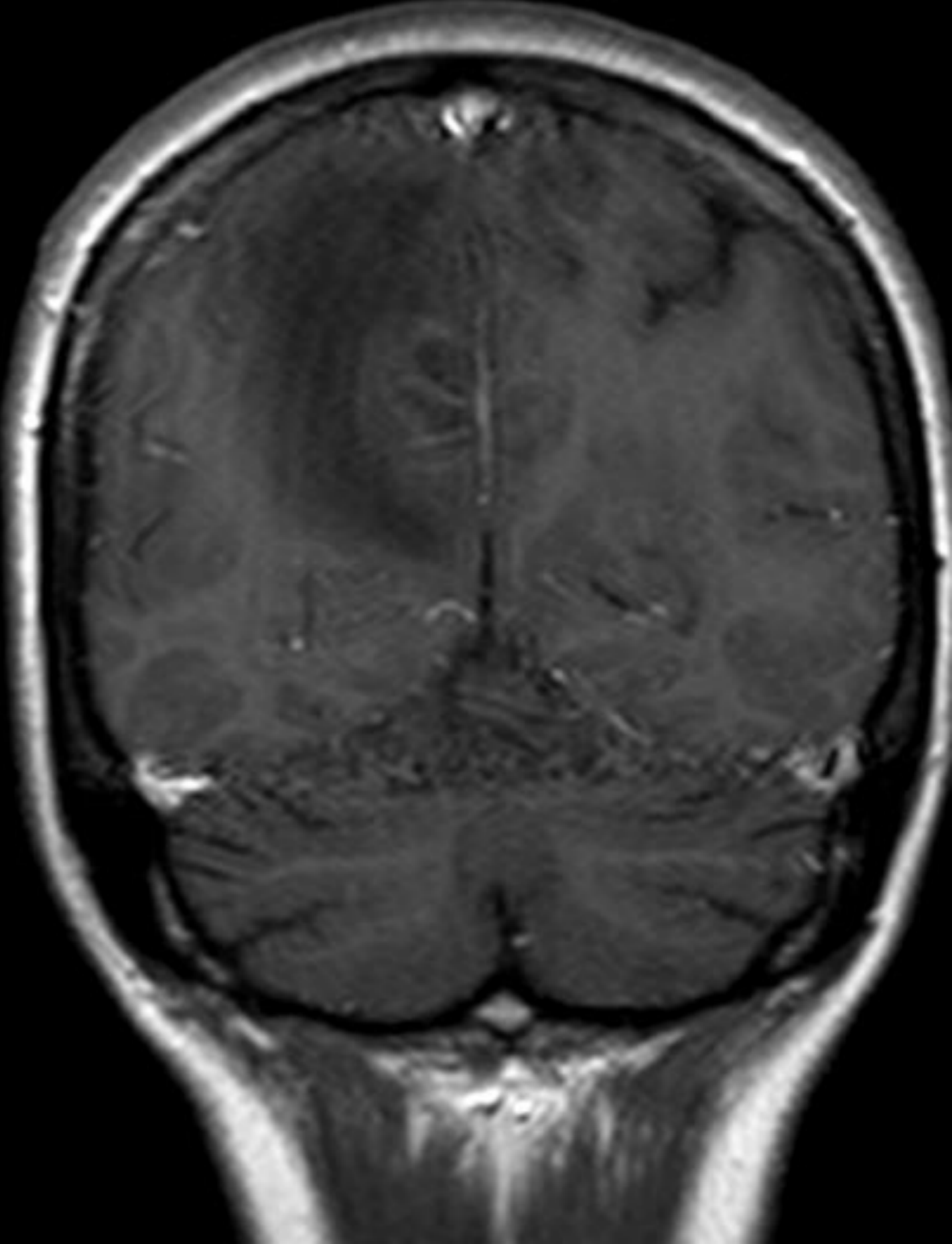
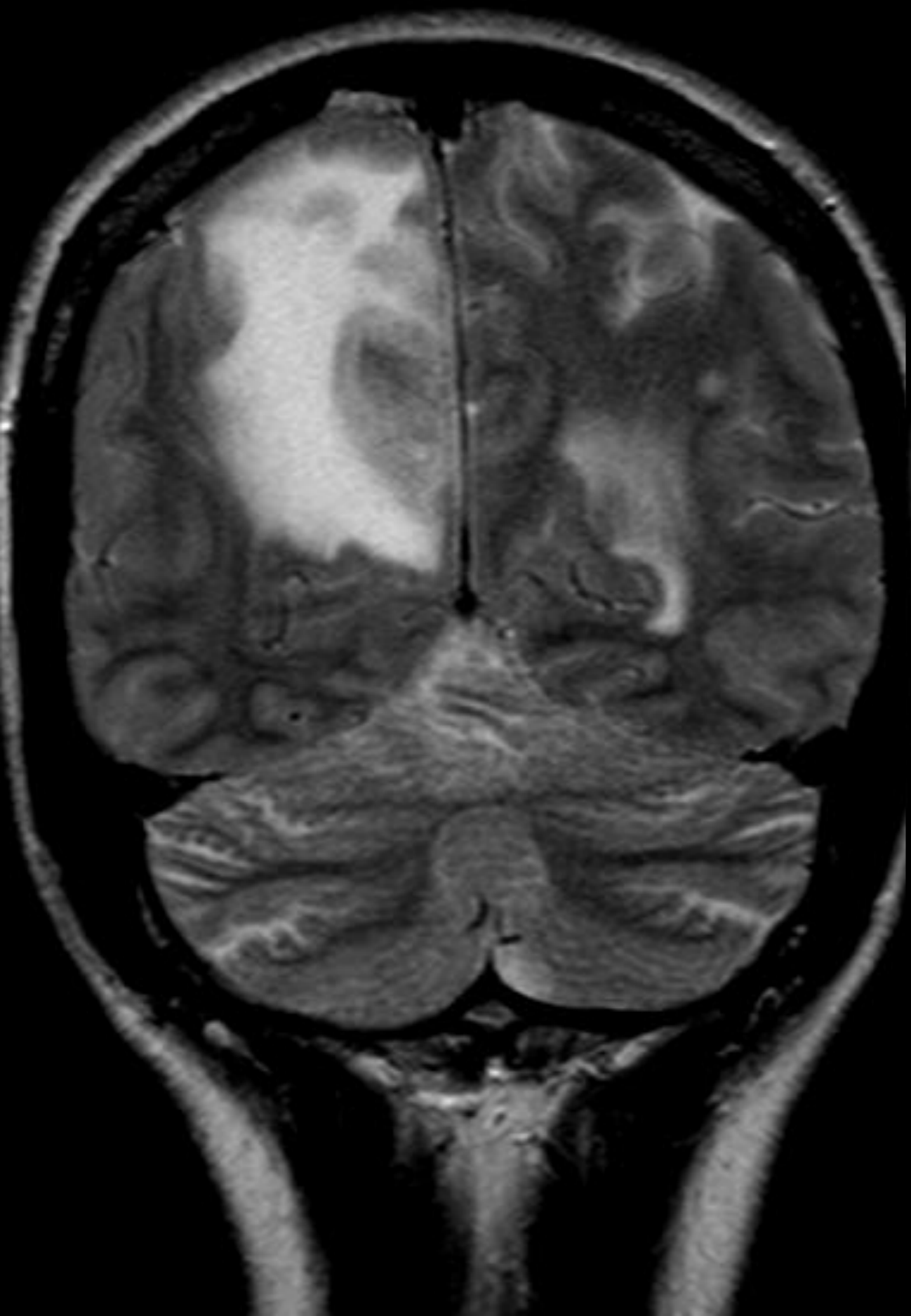
48 Y K hasta 1.5 yıldır tedavi altında

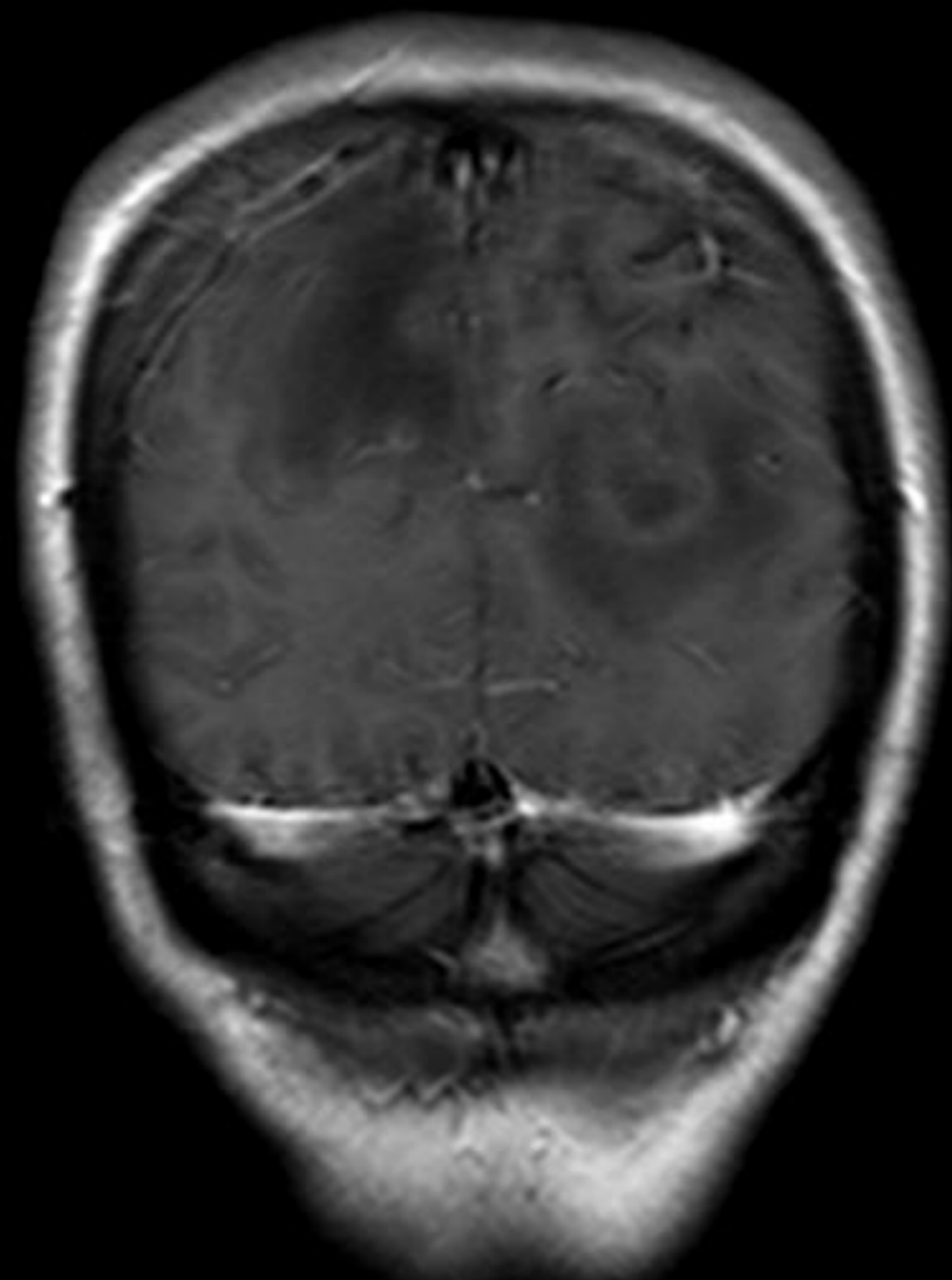
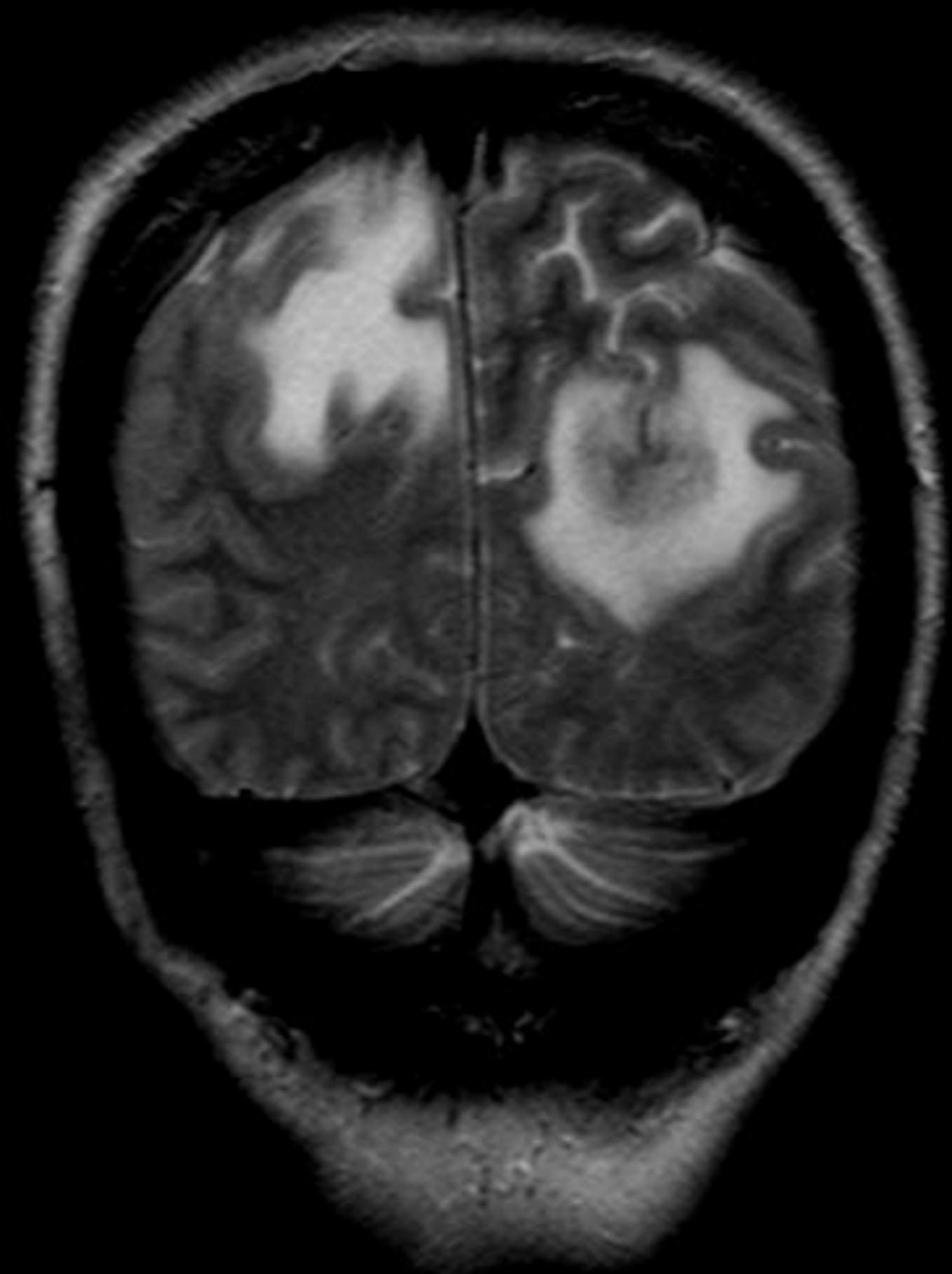


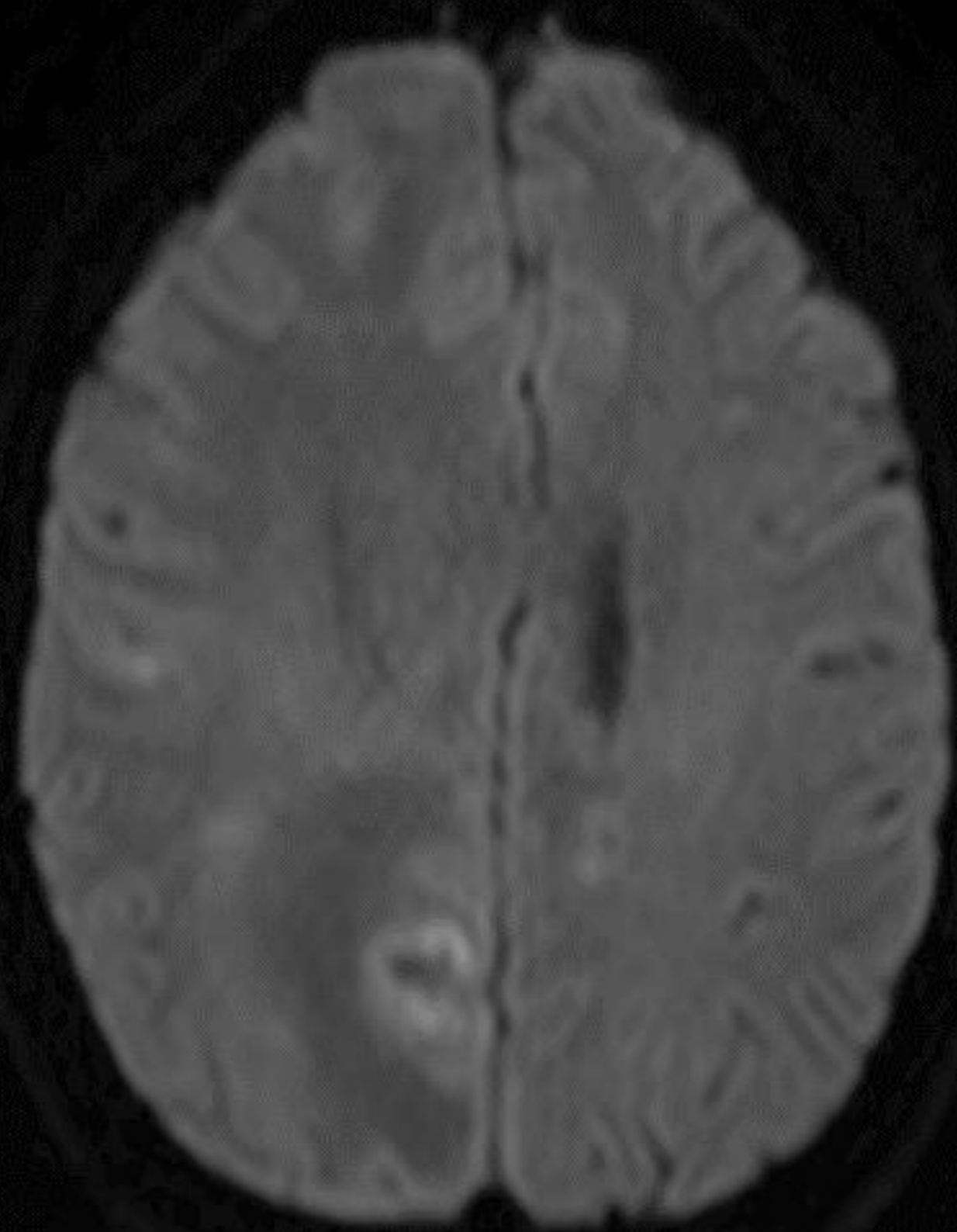
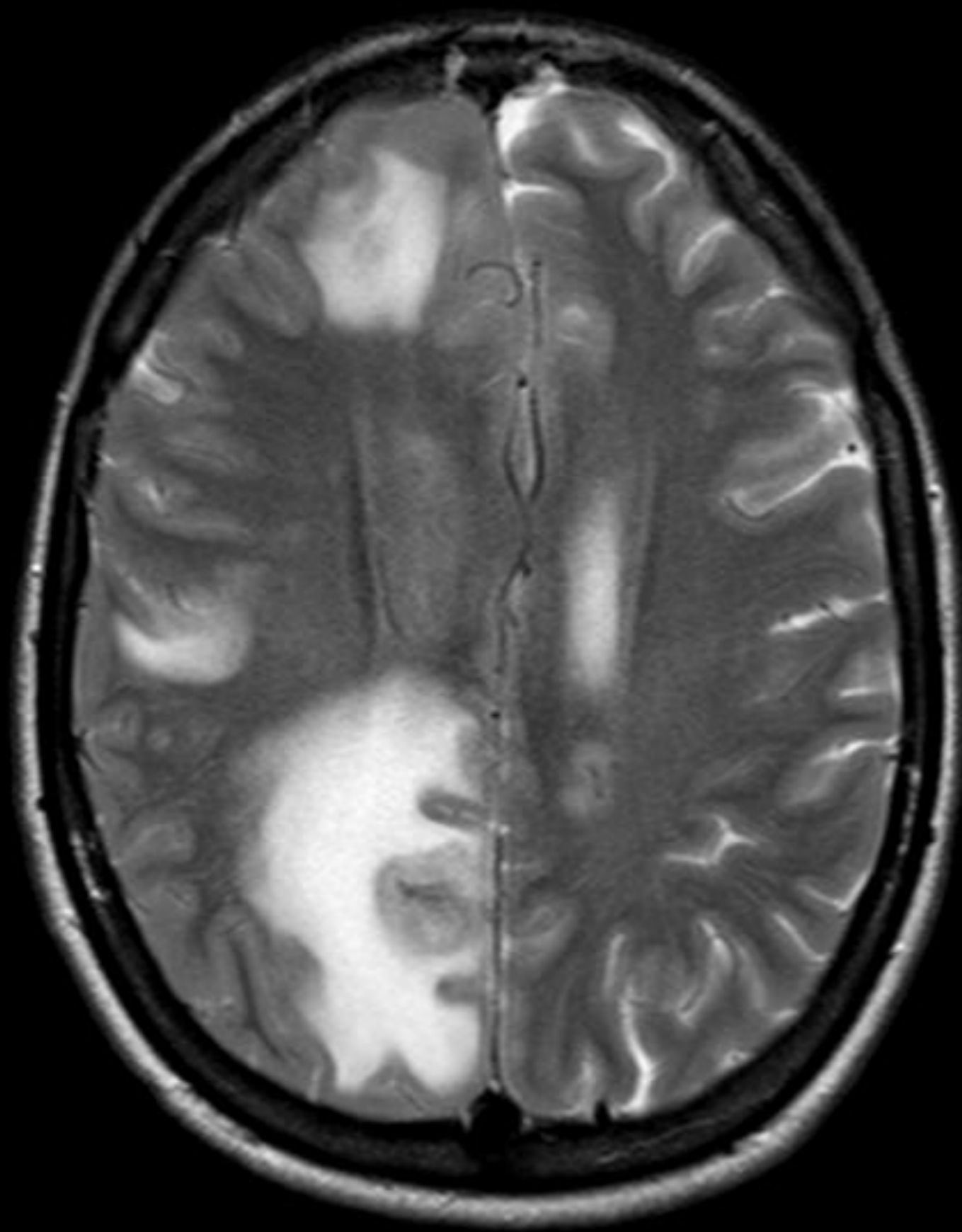Bx sonucu
Lenfoma

53 Y K hasta
Akut konfüzyyon









Teşekkürler

Prof. Dr. Fehmi Tabak
Dr. Mustafa Alkan

